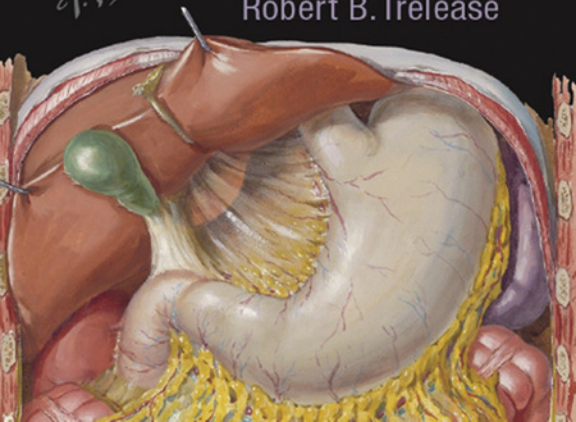




# NETTER'S Surgical Anatomy Review

P.R.N. 2nd Edition  
Robert B. Trelease

*F. Netter  
M.D.*



Any screen.  
Any time.  
Anywhere.

Activate the eBook version  
of this title at no additional charge.

Expert Consult eBooks  
give you the power  
to browse and find  
content, view enhanced  
images, share notes and  
highlights—both online  
and offline.

## Unlock your eBook today.

- 1 Visit [expertconsult.inkling.com/redeem](http://expertconsult.inkling.com/redeem)
- 2 Scratch off your code
- 3 Type code into “Enter Code” box
- 4 Click “Redeem”
- 5 Log in or Sign up
- 6 Go to “My Library”

It's that easy!

Scan this QR code  
to redeem your  
eBook through your  
mobile device:



Place Peel Off  
Sticker Here

**For technical assistance:**  
email [expertconsult.help@elsevier.com](mailto:expertconsult.help@elsevier.com)  
call 1-800-401-9962 (inside the US)  
call +1-314-447-8200 (outside the US)

## ELSEVIER


Use of the current edition of the electronic version of this book (eBook) is subject to the terms of the nontransferable, limited license granted on [expertconsult.inkling.com](http://expertconsult.inkling.com). Access to the eBook is limited to the first individual who redeems the PIN, located on the inside cover of this book, at [expertconsult.inkling.com](http://expertconsult.inkling.com) and may not be transferred to another party by resale, lending, or other means.

2015v1.0



ELSEVIER

Turn to **Netter** for better  
surgical outcomes!



**SAVE 20%**

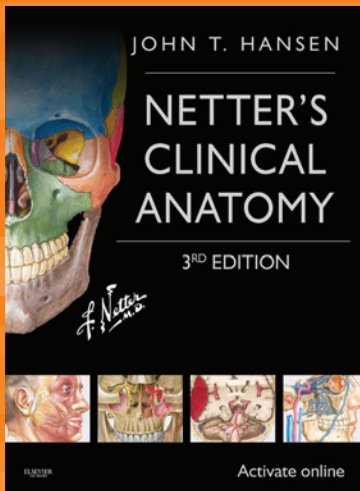
at [us.elsevierhealth.com](http://us.elsevierhealth.com) with  
promo code **BCP2RELEASE\***

\*Only valid for purchases by individual U.S., Mexico,  
Central & South America and Caribbean customers  
at [us.elsevierhealth.com](http://us.elsevierhealth.com)

ISBN: 978-1-4377-0833-2

ELSEVIER

A thorough but quick  
introduction to basic and  
clinical anatomy!



**SAVE 20%**

at [us.elsevierhealth.com](http://us.elsevierhealth.com) with  
promo code **BCP2TRELEASE\***

\*Only valid for purchases by individual U.S., Mexico,  
Central & South America and Caribbean customers  
at [us.elsevierhealth.com](http://us.elsevierhealth.com)

ISBN: 978-1-4557-7008-3



# NETTER'S Surgical Anatomy Review

P.R.N. 2nd Edition

**Robert B. Trelease, PhD**  
Professor  
Division of Integrative Anatomy  
Department of Pathology and  
Laboratory Medicine  
David Geffen School of Medicine  
University of California, Los  
Angeles  
Los Angeles, California

Illustrations by

Frank H. Netter, MD

Contributing Illustrators

Carlos A.G. Machado, MD

Kristen Wienandt Marzejon, MS,  
MFA

Tiffany DaVanzo, MA, CMI

John A. Craig, MD

ELSEVIER

# ELSEVIER

1600 John F. Kennedy Blvd.  
Ste 1800  
Philadelphia, PA 19103-2899

NETTER'S SURGICAL ANATOMY REVIEW P.R.N. ISBN: 978-0-323-44727-0

Copyright © 2017 by Elsevier Inc. All rights reserved.

Previous edition copyrighted 2011.

No part of this book may be produced or transmitted in any form or by any means, electronic or mechanical, including photocopying, recording or any information storage and retrieval system, without permission in writing from the publishers.

Permissions for Netter Art figures may be sought directly from Elsevier's Health Science Licensing Department in Philadelphia, PA, USA: phone 1-800-523-1649, ext. 3276 or (215) 239-3276; or email [H.Licensing@elsevier.com](mailto:H.Licensing@elsevier.com).

## Notice

Neither the Publisher nor the Author assumes any responsibility for any loss or injury and/or damage to persons or property arising out of or related to any use of the material contained in this book. It is the responsibility of the treating practitioner, relying on independent expertise and knowledge of the patient, to determine the best treatment and method of application for the patient.

The Publisher

## Library of Congress Cataloging-in-Publication Data

Names: Trelease, Robert Bernard, author. | Netter, Frank H. (Frank Henry), 1906-1991, illustrator.

Title: Netter's surgical anatomy review P.R.N. / Robert B. Trelease ; illustrations by Frank H. Netter ; contributing illustrators, Carlos A.G. Machado, Kristen Wienandt Marzejon, Tiffany DeVanzo, John A. Craig.

Other titles: Netter's surgical anatomy review pro re nata | Surgical anatomy review PRN

Description: Second edition. | Philadelphia, PA : Elsevier, [2017] | Includes index.

Identifiers: LCCN 2015047555 | ISBN 9780323447270 (pbk.)

Subjects: | MESH: Surgical Procedures, Operative | Anatomy | Atlases

Classification: LCC QM531 | NLM WO 517 | DDC 611/.9--dc23 LC record available at <http://lccn.loc.gov/2015047555>

*Content Strategist:* Elyse O'Grady

*Content Development Specialist:* Marybeth Thiel

*Publishing Services Manager:* Patricia Tannian

*Project Manager:* Ted Rodgers

*Designer:* Julia Dummitt

Working together to grow  
libraries in developing countries

[www.elsevier.com](http://www.elsevier.com) | [www.bookaid.org](http://www.bookaid.org) | [www.sabre.org](http://www.sabre.org)

ELSEVIER BOOK AID INTERNATIONAL Sabre Foundation

Printed in China

Last digit is the print number: 9 8 7 6 5 4 3 2 1

***This book is dedicated to***

*My parents, Florence and Robert Trelease (Sr.),  
who always supported my pursuit of learning  
and science;*

*My wife, Barbara, and our daughters, Cristin  
and Heather, who have motivated all my work;*

*My students, who will put their anatomical  
knowledge to good use in caring for their  
patients.*

This page intentionally left blank

## About the Author

**Robert B. Trelease, PhD**, is Professor in the Division of Integrative Anatomy, Department of Pathology and Laboratory Medicine, in the David Geffen School of Medicine (DGSOM) at UCLA. In 1996, Dr. Trelease became a founding member of and Faculty Advisor to the Instructional Design and Technology Unit (IDTU), part of the DGSOM Dean's Office established to develop online learning resources for medical education. IDTU currently provides and manages a broad range of web server- and mobile device-based educational resources for all 4 years of the medical school curriculum, as well as developing new multimedia teaching tools and course management applications. Dr. Trelease currently serves as Associate Director of IDTU, in addition to teaching medical gross anatomy, embryology, and neuroanatomy.

This page intentionally left blank



# Preface

**Netter's Surgical Anatomy Review P.R.N.** is a just-in-time, point-of-contact review of anatomy for the most common of the surgically treated diseases and diagnoses encountered during medical student clerkships and general surgery residencies.

This second edition includes new chapters on Heart Diseases and Lungs and Respiratory Diseases, content requested by users of the first edition and its electronic versions. This extends the coverage of material from general surgery into thoracic surgery. There are also new updated Netter Figures contributed by Dr. Carlos Machado, Kristen Wienandt Marzejon, and Tiffany DaVanzo.

I thank the prior readers and institutional adopters for their confidence and support. In particular, special thanks go out to Dr. David Chen, Associate Professor of Clinical Surgery, and the medical students and residents of the David Geffen School of Medicine at UCLA (DGSOM) for their ongoing use of the Web-based version for surgical clerkships and in-service learning.

I am also grateful for the continuing support and good counsel of my Department Chair, Dr. Jonathan Braun, and feedback from former Senior Associate Dean of Medical Education, Dr. LuAnn Wilkerson, who originally suggested that I develop a PDA-based learning resource for surgical clerkships.

Great appreciation is due to my colleagues at DGSOM's Instructional Design and Technology Unit, directed by Dr. Anju Relan and including master developers Zhen Gu, Katherine Wigan, Sam Payne, and Jason Rock. Their continuing multimedia learning projects and dedicated support of the online medical school curriculum have provided many practical lessons on the complexities of development and what really works in educational technology.

Most of all, I thank my Editor, Elyse O'Grady, for her continuing dedication to the distribution and improvement of Netter's Surgical Anatomy Review P.R.N. I am especially grateful to Marybeth Thiel, original Development Editor, for providing continuing editorial review and oversight for second edition updates, including all the new artwork. Their expert team at Elsevier worked skillfully to produce the new, redesigned content that you are using.

ROBERT B. TRELEASE, PHD

# Contents

## Section I Head and Neck

- 1 Skull and Face Fractures **3**
- 2 Thyroid Diseases **17**

## Section II Back and Spinal Cord

- 3 Vertebral Fractures **27**

## Section III Thorax

- 4 Breast Diseases **45**
- 5 Heart Diseases **61**
- 6 Lung Diseases **91**
- 7 Esophageal Diseases **115**
- 8 Ribs and Thorax Fractures **129**

## Section IV Abdomen

- 9 Appendix Diseases **139**
- 10 Biliary Diseases **149**
- 11 Colon Diseases **163**
- 12 Gastroduodenal Diseases **181**
- 13 Hernias **201**

- 14 Kidney Diseases **217**
- 15 Liver Diseases **233**
- 16 Pancreatic Diseases **253**
- 17 Small Intestine Diseases **265**

## **Section V Pelvis and Perineum**

- 18 Anorectal Diseases **285**
- 19 Pelvic Fractures **297**
- 20 Prostate Diseases **311**
- 21 Uterus and Adnexal Diseases **325**

## **Section VI Upper Limb**

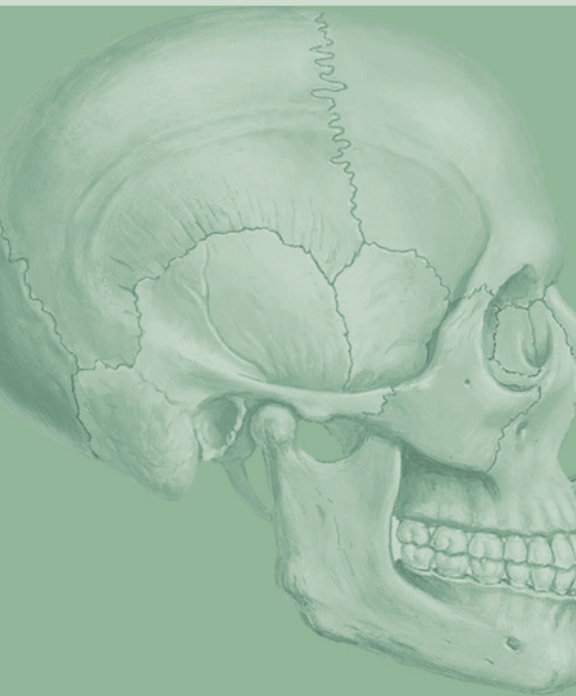- 22 Pectoral Girdle Fractures **343**
- 23 Humerus Fractures **353**
- 24 Forearm Fractures **367**
- 25 Wrist and Hand Fractures **381**

## **Section VII Lower Limb**

- 26 Hip and Thigh Fractures **397**
- 27 Knee and Leg Fractures **413**
- 28 Ankle and Foot Fractures **429**

**Index 443**

# Head and Neck



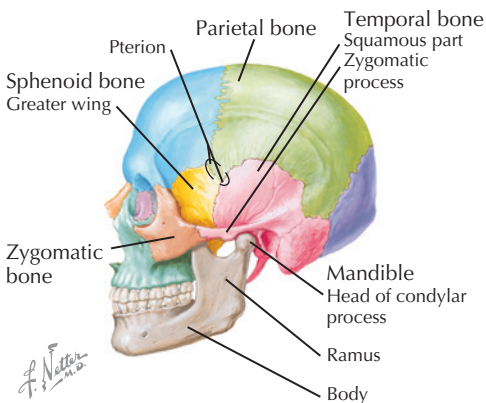
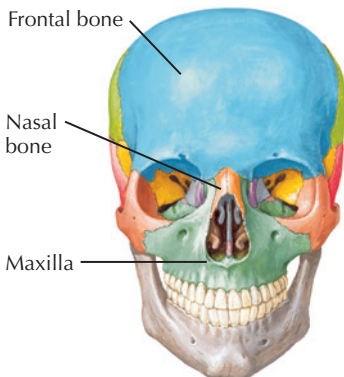
This page intentionally left blank

# 1 Skull and Face Fractures

## ANATOMY OF THE SKULL AND FACIAL SKELETON

### Skull and Facial Bones

- *Neurocranium* (cranial vault): frontal, ethmoid, sphenoid, temporal, parietal, occipital bones
- *Viscerocranium* (facial skeleton): maxilla, nasal, lacrimal, zygomatic, vomer, palatine, mandible bones
- *Base of skull*: occipital, sphenoid, temporal, palatine, maxilla bones
- Most of the bones of the skull are *flat* (type), with inner and outer “tables” (layers) of *compact (cortical) bone* surrounding trabecular bone and marrow space (*diploë*).
- *Emissary veins* connect *diploic spaces* with cerebral veins/sinuses (intracranial) and scalp and superficial veins: potential route for intracranial spread of infection.
- *Sutures*
  - Thin fibrous joints found only between skull and facial bones
  - Produced by intramembranous ossification
  - May be indented (e.g., coronal suture), planar, or squamous
- Most cranial and facial bones are pharyngeal arch derivatives.
- Occipital, sphenoid, and ethmoid bones develop from paraxial mesoderm, comparable to vertebrae.



Anterior and Lateral Aspects



## Scalp Layers

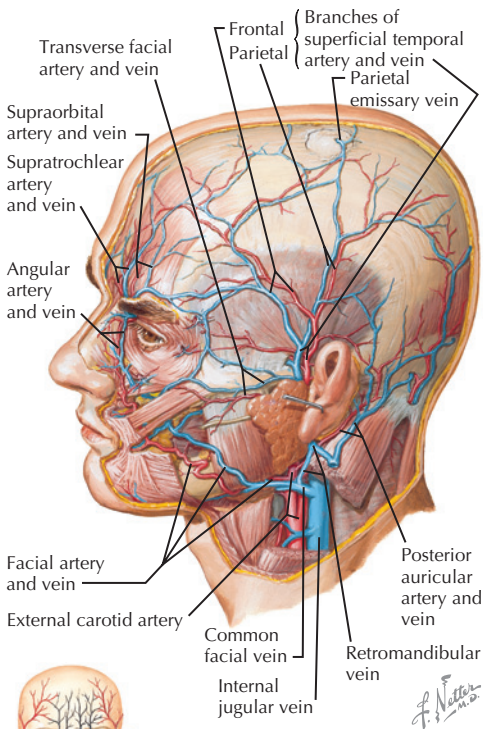
- Skin: thin (thicker in occipital region); well supplied with arteries, veins, lymphatic drainage
- Connective tissue: dense subcutaneous layer with rich neurovascular supply
- Aponeurosis of occipitofrontalis muscle, with lateral attachments of temporoparietalis and posterior auricular muscles (collectively the epicranium)
- Loose areolar tissue: allows aponeurosis movement; danger space for infections owing to emissary vein drainage into diploic spaces of cranium
- Pericranium: external periosteum, fibrously fused to sutures

## NEUROVASCULAR SUPPLY

### Arteries of Face and Cranium

#### *External Carotid (Proximal to Distal)*

- Lingual: to tongue and floor of mouth, may have common origin with facial
- Facial: superior, inferior labial, lateral nasal, angular branches; to anteromedial face
- Posterior auricular: posterior to ear and mastoid regions
- Occipital: lateral aspect of head behind ear
- Maxillary: deep auricular, anterior tympanic, deep temporal, middle meningeal, inferior alveolar, posterior alveolar, infraorbital branches; to deep face
- Transverse facial: lateral face, parallel to parotid duct
- Superficial temporal: anterior, lateral aspect of crania



Sources of arterial supply of face

Black: from internal carotid artery  
(via ophthalmic artery)

Red: from external carotid artery

## Superficial Arteries and Veins of Face and Scalp

### *Internal Carotid*

- Anterior cerebral
  - Ophthalmic artery: supraorbital, supratrochlear, anterior and posterior ethmoid branches
- Middle cerebral

### *Other*

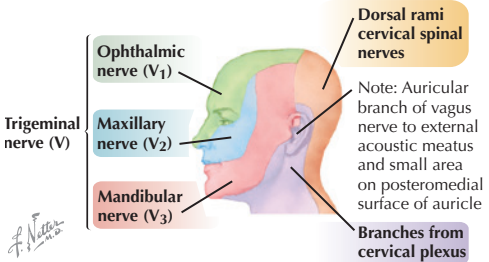
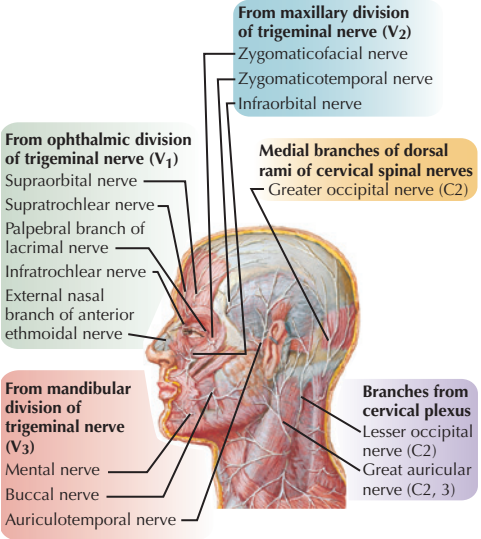
- Vertebral: basilar, pontine, posterior and inferior cerebellar, posterior cerebral, posterior communicating branches
- Facial: face richly perfused, with anastomoses across midline, anterior to posterior, and between intra- and extracranial branches
- Kiesselbach's area/plexus: anterior inferior nasal septal region, anastomoses between superior labial (facial), sphenopalatine, palatine (maxillary), and anterior ethmoid (anterior cerebral via ophthalmic) branches; frequent site of epistaxis

### **Venous Drainage**

#### *Internal Jugular Vein*

#### Common Facial Vein

- Tributaries
  - Facial: superior, inferior labial, deep facial, external nasal, angular ← orbital, inferior and superior palpebral
  - Submental
  - Retromandibular: superficial temporal, middle temporal, maxillary
- Pterygoid venous plexus of deep face connects with deep facial and maxillary veins and with cavernous sinus via connections through foramen ovale.
- Facial veins have no valves: potential route for spread of infection from face and deep venous



*F. Netter M.D.*

Cutaneous Nerves of Head and Neck

sinuses to intracranial sinuses (e.g., cavernous sinus via angular and orbital veins)

- Common facial connects to external jugular vein

### *External Jugular Vein*

- Drains posterior auricular

### **Innervation of the Head and Neck**

- Cranial nerve deficits may be associated with specific regional fractures, trauma
- Olfactory (I): special somatic sensory to superior nasal cavity; foramina: cribriform plate of ethmoid; intranasal CSF leakage, anosmia with ethmoid fracture
- Optic (II): foramen—optic canal (sphenoid)
- Oculomotor (III), trochlear (IV): motor to extraocular muscles, travel through cavernous sinus, superior orbital fissure (sphenoid bone), and orbit
- Trigeminal nerve (V): sensory to most of face and head, superficial and deep, including sinuses and supratentorial dura; motor to muscles of mastication, tensor palati, and tensor tympani
  - Ophthalmic division: foramen—superior orbital fissure (sphenoid bone)
  - Maxillary division: foramen rotundum (sphenoid bone)
  - Mandibular division: foramen ovale (sphenoid bone)
- Abducens (VI): runs along clivus and through cavernous sinus and superior orbital fissure to lateral rectus; clival fracture can cause lateral gaze paralysis
- Facial (VII)
  - Supplies muscles of facial expression and stapedius

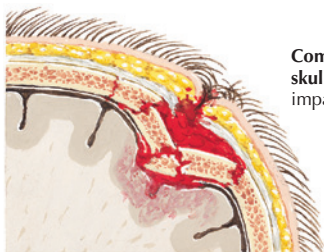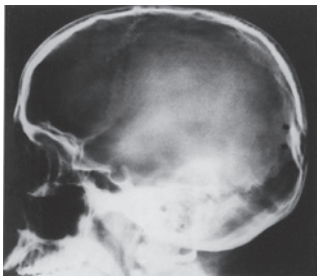
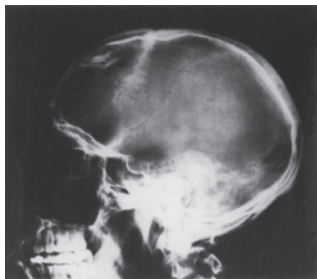- Carries visceromotor fibers to lacrimal and submandibular and sublingual salivary glands
- Taste afferents for anterior 2/3 of tongue
- Exits stylomastoid foramen (temporal bone)
- Acousticovestibular (vestibuloacoustic, auditory) (VIII): from cochlea and vestibular apparatus (labyrinth) in temporal bone; nerve enters internal acoustic meatus (temporal bone)
- Glossopharyngeal (IX): taste and common sensation from posterior third of tongue and tonsillar fossa; exits jugular foramen (between temporal and occipital bones)
- Vagus (X): motor to palate, pharynx and larynx, thoracoabdominal viscera; exits jugular foramen (between temporal and occipital bones)
- (Spinal) accessory (XI): motor to sternomastoid and trapezius muscles; exits jugular foramen (between temporal and occipital bones)
- Hypoglossal (XII): motor to tongue muscles except for palatoglossus (X); exits hypoglossal canal (anterior supracondylar occipital bone)
- Cervical nerves
  - No C1 dermatome exists.
  - C2 spinal nerve: sensory to skull, skin from vertex down, infratentorial dura, parotid (auriculotemporal nerve), and infratemporal skin
  - C3 spinal nerve: sensory to suboccipital region

## CLINICAL CORRELATES

### Skull Fractures

#### *Classification*

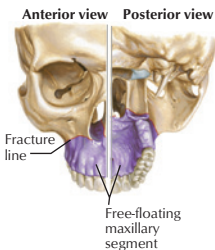
- Linear: fracture line is distinct
- Comminuted: multiple fragments, may be depressed with compression of dura and brain (image)



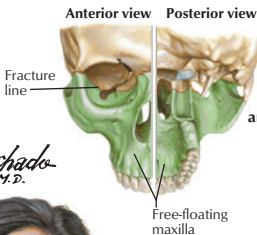
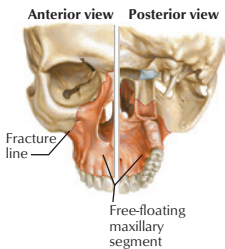
**Compound depressed skull fracture.** Note hair impacted into wound

Compound Depressed Skull Fractures

**Le Fort I fracture: horizontal detachment of maxilla at level of nasal floor**

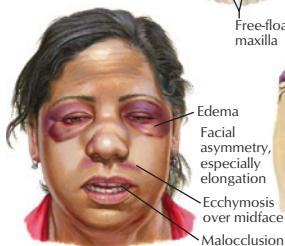


**Le Fort II fracture: fracture through maxillae, antra, nasal bones, and infraorbital rims**

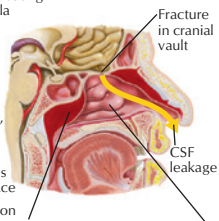


**Le Fort III fracture: fracture through zygomatic bones and orbits, separating facial bones from cranial vault**

*C. Machado*  
— M.D.



Craniofacial dysjunction in Le Fort III fracture distorts facial symmetry



Hematoma and massive edema may occlude nasal airway, necessitating tracheostomy

## Mid-face Fractures



- Basilar: in skull base
- Diastasis: fracture along a suture

### *Compound*

- A compound fracture is any fracture communicating with scalp laceration, sinuses, or middle ear.
- Depressed compound fractures require surgical treatment.

### *Middle Meningeal Artery*

- Underlies sphenoid, parietal, temporal bones
- May be lacerated with fractures at pterion, resulting in epidural hematoma

### Facial Fractures

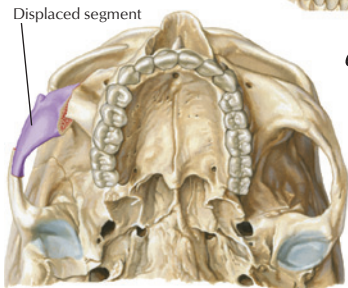
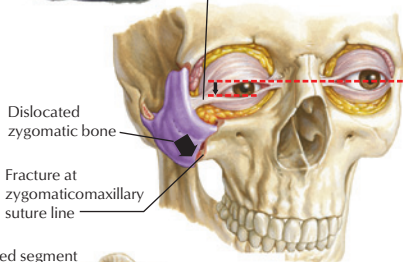
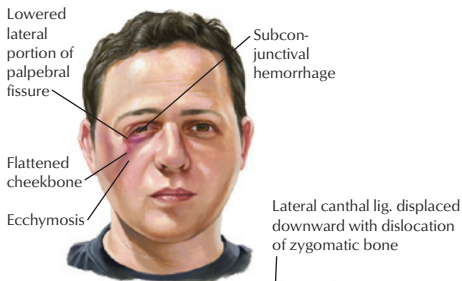
- Nasal fractures are most common (3rd most common fracture overall).
- Blowout fracture of orbit
  - Pressure of direct blunt trauma to eye fractures superior maxilla.
  - Entraps orbital fat, inferior rectus or inferior oblique in antrum
  - Impairs upward gaze

### Mid-face Fractures

- Consequence of high-energy impact with mid-face (e.g., motor vehicle accident)

### *Le Fort Classification*

- I: horizontal detachment of maxilla along nasal floor
- II: pyramidal fracture of maxilla, including nasal bones, antra, infraorbital rims, orbital floors



*C. Machado*  
— M.D.

Zygomatic Fractures

- III: pyramidal fractures as in II, with both zygomatic bones; may be accompanied by airway problems, nasolacrimal obstruction, CSF leakage

### Zygomatic Fractures

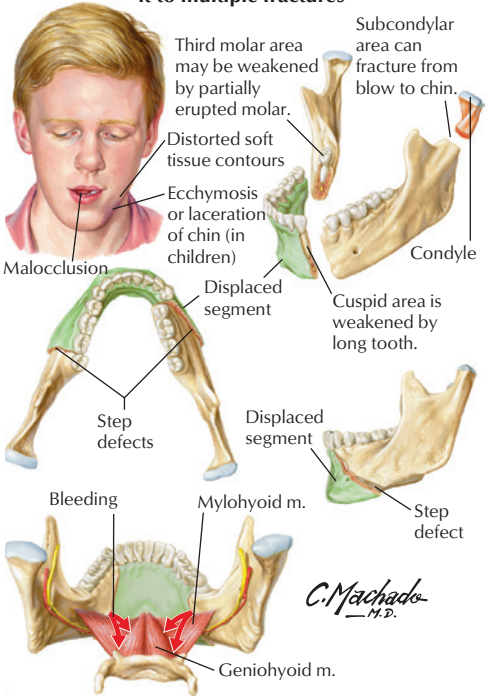
- Trauma to cheek can disrupt zygomatic articulations with frontal, maxilla, sphenoid, and temporal bones.
- Frontal and maxillary suture line fractures are common, with displacement inferiorly, medially, or posteriorly.
- Displacement of canthic ligament with lower margin of orbit may be associated with ipsilateral ocular and visual changes and diplopia.
- Hyphema (anterior chamber blood from hemorrhage) from associated eye impact

### Mandible Fractures

- Second most commonly fractured facial bone (after nasal)
- Multiple fractures are common (50%), favored by U shape and bilateral articulations
- Most common sites are cuspid (canine) and 3rd molar regions.
- Ecchymosis (blood leakage) is common in loose tissues of floor of mouth.

*See next page*

**Anatomy of mandible predisposes it to multiple fractures**



Bleeding caused by fracture is trapped by fanlike attachment of mylohyoid musculature to mandible, and presents clinically as ecchymosis in floor of mouth.

**Mandibular Fractures**

# 2

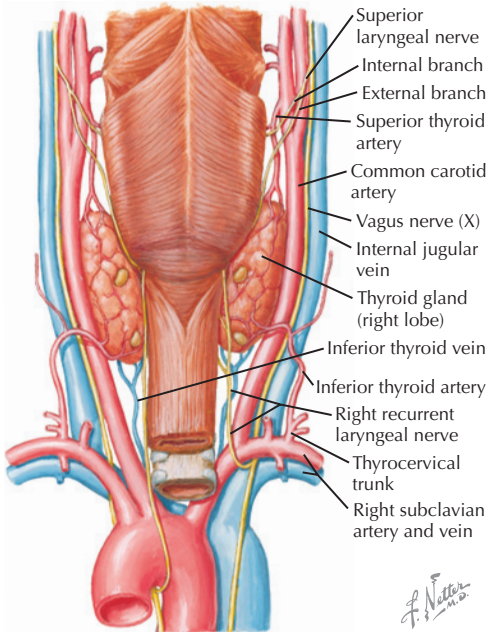
## Thyroid Diseases

### THYROID AND PARATHYROID ANATOMY

#### Thyroid

- Thyroid typically consists of right and left lobes, connected by a midline isthmus, with an ascending pyramidal lobe in about 50% of cases.
- Location
  - Immediately anterior and lateral to trachea, from about 5th cervical vertebra to 1st thoracic vertebra
  - Medial to internal jugular veins
  - Anterior to common carotid arteries
  - Deep to infrahyoid muscles: sternohyoid (medial), omohyoid, sternothyroid (lateral)
  - Infrahyoid muscles embedded in pretracheal fascia, deep to investing fascia of neck (superficial layer of deep fascia)
- Connective tissue (true) capsule is continuous with the septa dividing the stroma of the gland.
- Surgical (false) capsule lies external to the true capsule and is derived from the pretracheal fascia.
- Of the overlying strap muscles, the sternohyoid is most superficial, overlying the sternothyroid and thyrohyoid.
- Thyroid follicular (epithelial/principal) cells secrete thyroxine ( $T_4$ ) and triiodothyronine ( $T_3$ ), regulated by TSH receptors.

## Posterior view



Thyroid Gland and Pharynx: Posterior View

- Thyrotropin-releasing factor or hormone (TRF or TRH) from hypothalamus controls TSH release from pituitary.
- Parafollicular (C) cells secrete calcitonin.

## Parathyroids

- Superior parathyroid glands usually lie between the true capsule of the thyroid and its investing surgical (false) capsule fascia.
- Inferior parathyroid glands might lie between the true and false capsules, within the thyroid parenchyma, or on the outer surface of the surgical capsule.

## VESSELS AND LYMPHATICS

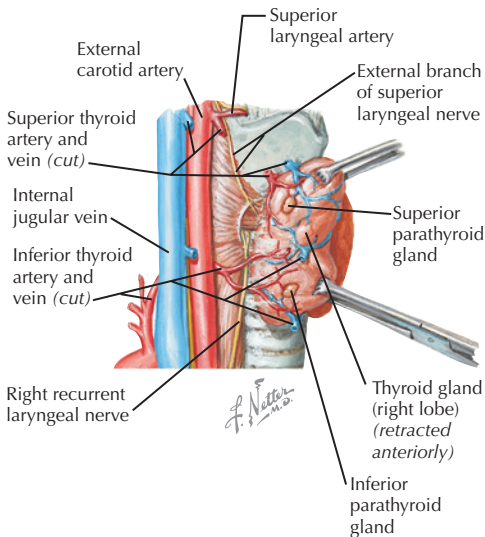
### Arterial Supply

- Superior thyroid arteries arise bilaterally from the external carotid arteries at, above, or below the bifurcation of the common carotid.
- Inferior thyroid arteries arise bilaterally from the thyrocervical trunks (branches of the subclavians) or occasionally directly from the subclavian arteries.
- Thyroid ima artery (1% of patients)
  - Variable, unpaired, anterior to trachea
  - Supplies isthmus
  - Can arise from brachiocephalic, right common carotid, or aortic arch: important consideration in tracheostomy

### Venous Drainage

- Thyroid vein plexus is in the substance of the gland and on its surface.
- Thyroid plexus is drained by 3 main pairs of veins.

## Right lateral view



## Blood Vessels and Parathyroid Glands

- Superior thyroid veins: accompany superior thyroid arteries
- Middle thyroid veins: occasionally double or absent, arise posterolaterally, drain independently
- Inferior thyroid veins: largest, drain inferiorly



## Lymphatic Drainage

- Vessels in interlobular connective tissue parallel the arterial supply
- Communicate with capsular network
- Drainage into prelaryngeal, pretracheal, and paratracheal nodes, then into superior and inferior deep cervical nodes
- Lateral drainage directly into inferior deep cervical nodes
- Some drainage into brachiocephalic nodes, trunks, or thoracic duct

## CLINICAL CORRELATES

### Thyroidectomy

- Partial or total removal of the thyroid may be indicated for refractory severe hyperthyroidism, Graves' disease, nodules, or cancer.
- Recurrent laryngeal nerves are at risk during surgery.

### Recurrent Laryngeal Nerve

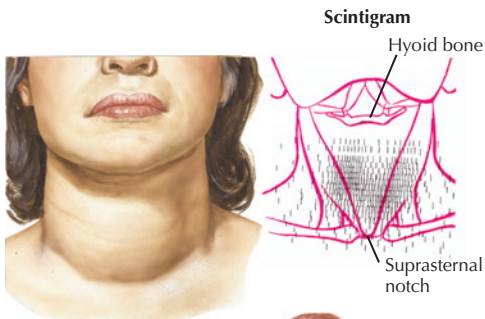
- Nerve ascends from the thoracic outlet, in or near the tracheoesophageal groove.
- Course past the inferior thyroid artery is highly variable: it can pass anterior, between, or posterior to the artery's bifurcation into anterior and posterior branches.

### Thyroid Cancer

- Rare, but most common endocrine malignancy in the United States

#### *Types of Thyroid Cancer*

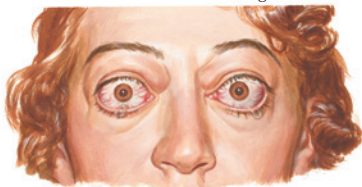
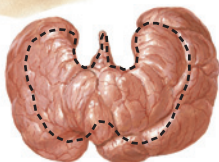- Thyroid adenomas
- Follicular adenomas



**Diffuse goiter of moderate size**

**Diffuse enlargement and engorgement of thyroid gland**

(broken line indicates normal size of gland)



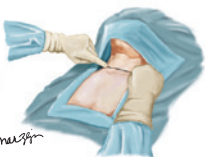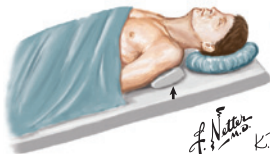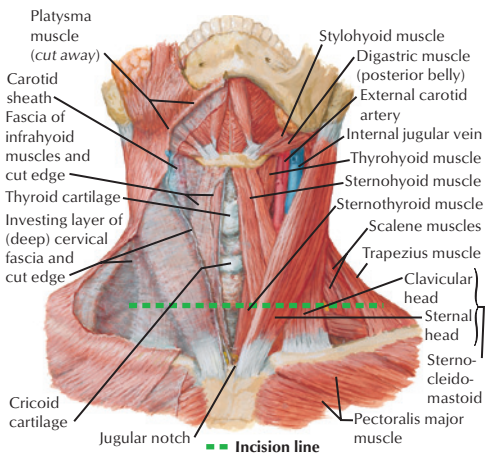
**Moderately severe exophthalmos**

*F. Netter M.D.*

**Graves' Disease: Thyroid and Ocular Pathology**

- Papillary thyroid carcinoma
  - Most common thyroid carcinoma
  - Predominantly in women
  - Slow growing
- Follicular thyroid carcinoma
  - 10% of all U.S. cases
  - Predominantly in women
  - Slow growing
  - Hürtle cell carcinoma considered a variant
  - 1/3 of cases with radiation exposure history, no other common factors
- Medullary thyroid carcinoma
  - Can be associated with multiple endocrine neoplasia, usually as the first manifestation
  - Arises from parafollicular C cells
- Malignant lymphoma of the thyroid

*See next page*

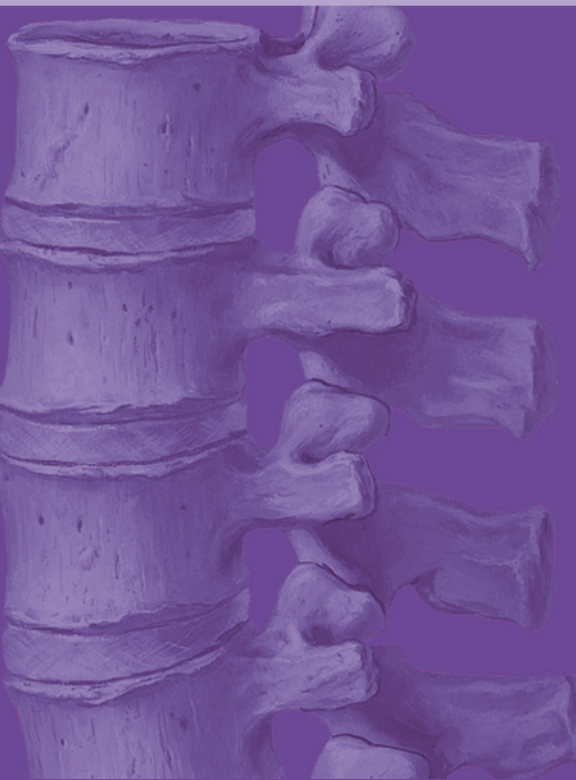


The patient is positioned supine on the operating room table with the arms tucked at the sides. To enhance the accessibility of the thyroid gland, the patient is positioned on a soft roll (arrow) placed lengthwise under the shoulders, and the neck is extended on a soft-foam headrest. The bed is placed in reverse Trendelenburg position to decrease the venous pressure in the neck and reduce potential bleeding.

A silk suture is used to mark the site of the incision. Important anatomic landmarks are the thyroid cartilage, the cricoid cartilage, and the sternal notch. The site for the incision is being marked just below the cricoid cartilage.

### Anatomic Landmarks for Thyroidectomy or Parathyroidectomy Incision

# Back and Spinal Cord



Back and Spinal Cord

This page intentionally left blank

# 3 Vertebral Fractures

## ANATOMY OF THE VERTEBRAL COLUMN

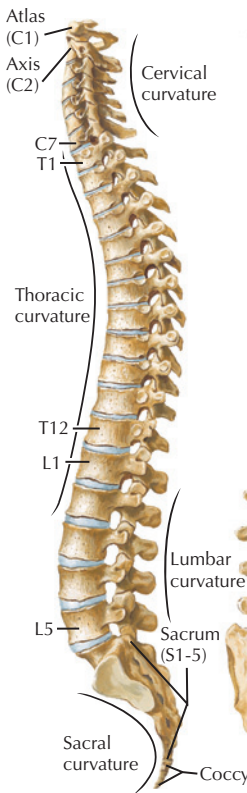
### Articulated Vertebrae and Spine

- Number: 31 = C7 + T12 + L5 + S5 + Co4
- Primary curvatures: thoracic, sacral; present in utero
- Secondary curvatures: cervical, lumbar; develop postnatally
- Curvatures dependent on body shapes and sizes and disc shapes and sizes
- Consequences of upright gait, large head, high-speed travel: major fracture forces typically are on cervical or lumbar vertebrae
- Physical landmarks for surgery
  - C2-C3 disc: level of mandible
  - C3 body: level of hyoid bone
  - C4-C5 bodies: level of thyroid cartilage
  - C7 spine: vertebra prominens
  - T7 body: level of inferior angle of scapula
  - L4-L5 disc: level of iliac crest

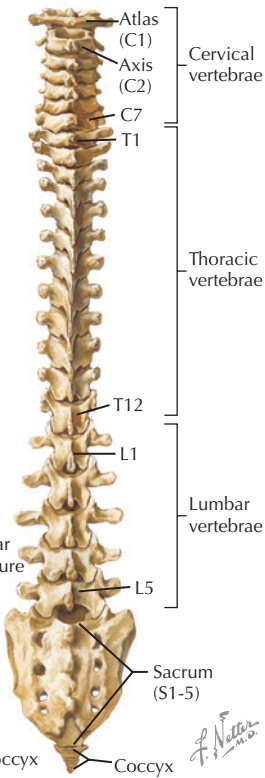
### Typical Vertebrae

- Parts and landmarks: body, pedicles, lamina(e), spine, transverse processes, superior articular facets, inferior articular facets
- Associated rib components (variable): developmental (homeobox) anomalies can produce cervical and lumbar ribs.

## Left lateral view



## Posterior view



Vertebral Column and Spine

*F. Netter M.D.*

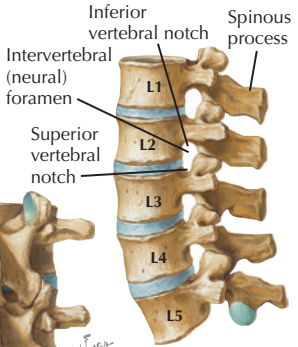
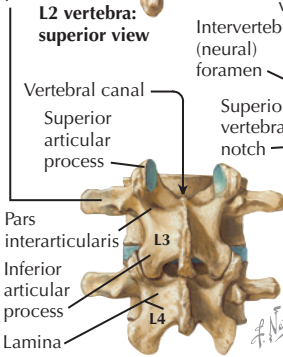
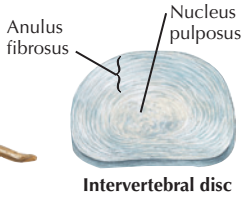
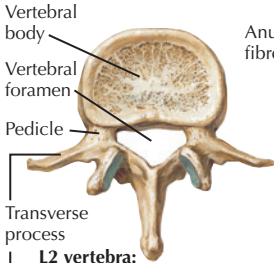


## Cervical Vertebrae

- C1, atlas
  - No body, thin anterior and posterior arches, posterior tubercle, no laminae or spine
  - Lateral masses with superior (atlantooccipital) and inferior (atlantoaxial) articular facets
  - No transverse foramina grooves for vertebral arteries entering foramen magnum
- C2, axis
  - Body includes dens or odontoid process representing developmental C1 body.
  - Broad lamina with bifid posterior process
  - Large interarticular part with planar superior articular facet for C1, more typical inferior articular process for C3
  - Strongest cervical vertebra
- Foramina transversaria
  - Contain vertebral arteries from C6 through C2
  - Anterior rims are rib components.
- C3-C7, typical cervical vertebrae
  - Large, upward-cupped bodies
  - Bifid spinous processes
  - C6 and C7 spines are longest of the cervical vertebrae.
  - Superior and inferior articular facets constrain flexion, extension, and lateral flexion.

## Thoracic Vertebrae

- “Typical” vertebrae
- Synovial hemifacets on upper and lower body for heads of ribs; vertebral-costal joints
- Synovial facets on transverse processes for costovertebral joints with tubercles of ribs



Lumbar Vertebrae and Intervertebral Disc

## Lumbar Vertebrae

- Largest bodies of all regional vertebrae, bear weight of body above
- Spinal foramina are larger superiorly, and spinal roots are larger inferiorly: L5 spinal nerves fit tightest.

## Sacral Vertebrae

- Fusion of sacral bodies typically occurs in adulthood, though disc remnants can remain visible on imaging.
- Parts and landmarks
  - Ala
  - Sacroiliac articular surfaces
  - Lumbosacral articular (disc) surface
  - Promontory
  - Fused bodies (5)
  - Anterior and posterior foramina
  - Coccyx (~4 segments)
- Sacral canal
  - Continuation of vertebral canal
  - Contains meninges and roots of cauda equina
- Posterior
  - Median and lateral sacral crests
  - Superior articular facet (to L5 inferior facet)
  - Sacral hiatus (end of sacral canal, ref. caudal anesthesia)
- Posterior and anterior sacrococcygeal ligaments are the tail ligaments.
- See Pelvic Fractures for more information.

## Joints and Ligaments of the Spine

- Vertebral body joints: discs, symphyses
  - Anulus fibrosus: dense regular CT

- Nucleus pulposus: gelid remnant of embryonic notocord
- Anulus reinforced anteriorly by broad anterior longitudinal ligament: resists hyperextension
- Anulus weakest lateral to narrow dorsal longitudinal ligament, favors herniation posteriorly near intervertebral foramina and exiting spinal roots
- Discs support range of movement between adjoining vertebrae (dashpot function).
- Vertebral arch joints: between superior and inferior articular processes of successive vertebrae
  - Synovial, zygapophyseal, sliding
  - Shape of articular processes determines axes of movement between regional vertebrae.
- Ligamenta flava run between laminae.
- Interspinoous and supraspinoous ligaments
  - Prevent hyperflexion, help maintain upright extension of neck and lower back
  - Continuous with raphes of trapezius, lumbar aponeuroses
- Ligamentum nuchae: supraspinoous ligament + raphes of trapezius and cervical muscles
- Tectorial membrane
  - Epidural
  - Continuous with posterior longitudinal ligament
  - Stabilizes atlantooccipital joints
- Cruciate ligament (craniovertebral)
  - Deep to tectorial membrane
  - Part of synovial atlantoaxial joint
  - Transverse + longitudinal parts
  - Transverse ligaments pass posterior to dens and attach to inner anterior arch of atlas.

- Superior longitudinal band attaches to occipital bone above foramen magnum.
- Inferior longitudinal band attaches to C2 body posteriorly.
- Stabilizes atlantoaxial joints
- Alar ligaments
  - From head of dens to occipital bone above foramen magnum
  - Limit rotation of head/atlantoaxial joint

## **NERVES AND VESSELS OF SPINE AND CORD**

### **Spinal Cord and Nerves**

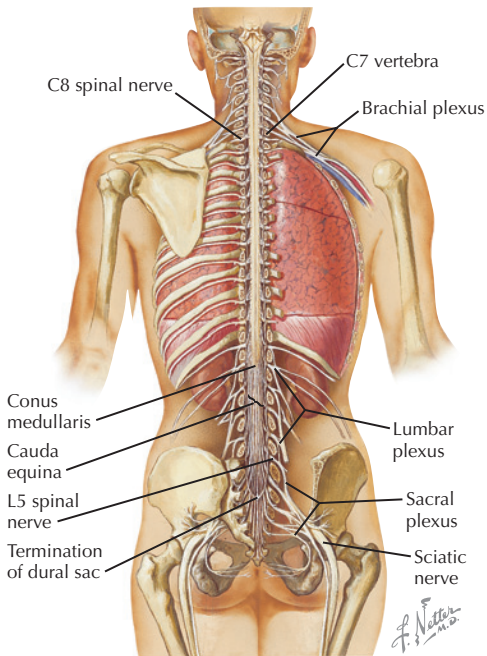
- Spinal cord and meningeal sheaths adjoin inner bone of bodies, pedicles, and laminae in vertebral canal and are susceptible to trauma with fractures.
- Epidural space separates dura from periosteum and ligaments of vertebral canal.
- C1-C7 spinal nerves and ganglia exit canal above numbered vertebral arch or pedicle.
- C8 lies below C7 pedicle, above T1.
- Spinal nerves T1 and below exit below the pedicles of the same-numbered vertebrae.
- Because the cord is shorter than the length of vertebral canal, cervical roots exit more laterally than those below.
- Phrenic nerve (C3-C5 segments): cord injuries at or above C4 can cause diaphragmatic paralysis.
- Upper limb enlargement (C5-T1 cord; for brachial plexus)
  - About same level as cervical vertebrae
  - Cord injuries at or above these segments compromise upper limb (and lower) musculature and sensation.

- Conus medullaris (adult): inferior tip of spinal cord typically lies ~ mid-body L2 level.
- Lower limb enlargement (L3-S1 cord for lumbosacral plexus)
  - At levels of lower thoracic and uppermost lumbar vertebrae
  - Cord injuries at or above these segments compromise lower limb and pelvic musculature and sensation.
- Lumbosacral roots travel nearly vertically to individual vertebral foramina: posterior L4 herniation typically spares L4 roots and compresses closer L5 and S1 roots within dural sac.
- L4 and L5 (suprasacral) discs are the most susceptible to herniation.

## Vessels

### *Arteries of the Spine and Cord*

- Vertebrae are supplied by periosteal and equatorial branches of major cervical and thoracoabdominal arteries.
  - Cervical: vertebral artery and ascending cervical artery
  - Thoracic: posterior intercostal artery branches
  - Lumbar: subcostal and lumbar arteries
  - Sacrum and coccyx: iliolumbar, lateral, and medial sacral arteries
- Spinal cord is supplied by longitudinal anterior (1) and posterior spinal (2) arteries, arising superiorly from vertebral arteries.
- Spinal arteries receive segmental input from segmental spinal and radicular branches of cervical and thoracoabdominal arteries (e.g., aorta).



Spinal Cord and Nerves in Situ

- Radicular and segmental anastomoses do **not** occur at every spinal level, favoring cervical and lumbosacral limb enlargements of cord.
- Largest segmental, great anterior medullary artery (Adamkiewicz) supplies ~2/3 of cord, 65% left only, at lower thoracic or lumbar level.

### *Venous Drainage*

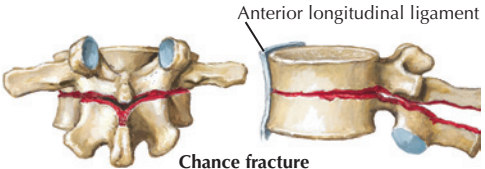
- Venous drainage parallels the arteries.
- Anterior external plexus: drains basivertebral veins from bodies.
- Posterior external plexus: around spines
- Internal (epidural) plexus
  - Anterior and posterior networks lining vertebral canal
  - Anterior also drains basivertebral veins.
- Plexuses connect to azygous system, cervical, lumbar veins and may be dilated with caval obstruction or portal hypertension.

## **CLINICAL CORRELATES**

### Three-Column Concept for Vertebral Fractures

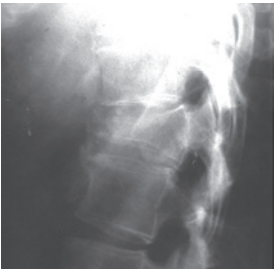
- Anterior column: anterior half of vertebral body + anterior longitudinal ligament
- Middle column: posterior half of vertebral body + posterior longitudinal ligament
- Posterior column: facet joints, laminae, spines, interspinous ligament
- Fracture is unstable if >1 column is disrupted.
- Anterior column compression (wedge) fractures are usually considered stable.
- Burst fractures are considered unstable.



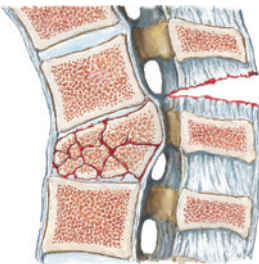


**Chance fracture**

Complete transverse fracture through entire vertebra. Note hinge effect of anterior longitudinal ligament



Lateral radiograph shows burst fracture of body of T12 with wedging, kyphosis, and retropulsion of fragments into spinal canal.



Sagittal view of fracture shown in radiograph above

*F. Netter M.D.*

**Vertebral Dislocations**

### Cervical Fractures

- C1 burst (Jefferson): caused by axial forces
- C2 hangman's: caused by extension, distraction
- C2 odontoid
  - Type I: above base, stable
  - Type II: at base, unstable
  - Type III: extends into body, unstable

### Thoracolumbar Fractures

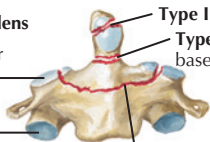
- Thoracolumbar junction is the most mobile spinal segment and most common site of injury.
- Associated trunk and limb injuries are common.
- Neurologic injuries are often complete in thoracic spine trauma.
- Thoracolumbar junction–level spinal injuries can damage the conus medullaris.
- Lumbar spine injuries typically affect roots of the cauda equina.

### Sacral Fractures

- Sacral fractures are typically associated with other fractures of the pelvis (e.g., motor vehicle accidents).
- See Pelvic Fractures for more information.

### Fracture of dens

Superior articular  
facet  
Inferior articular  
facet



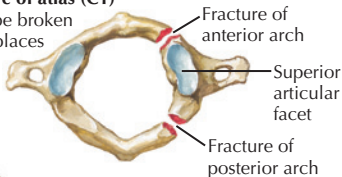
**Type I.** Fracture of tip

**Type II.** Fracture of  
base or neck

**Type III.** Fracture  
extends into body of axis

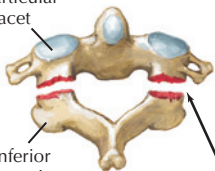
### Jefferson fracture of atlas (C1)

Each arch may be broken  
in one or more places



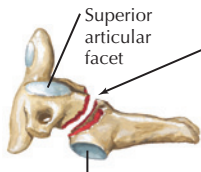
Superior  
articular  
facet

Inferior  
articular  
process



### Hangman fracture

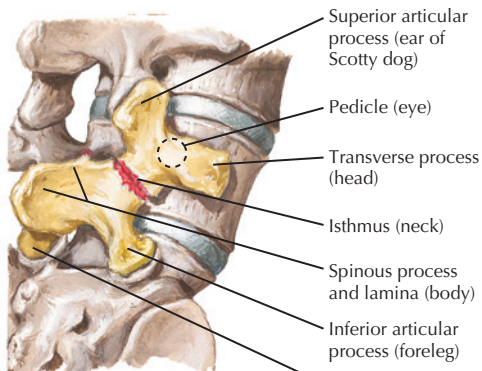
Fracture through neural arch  
of axis (C2), between superior  
and inferior articular facets



Inferior articular facet

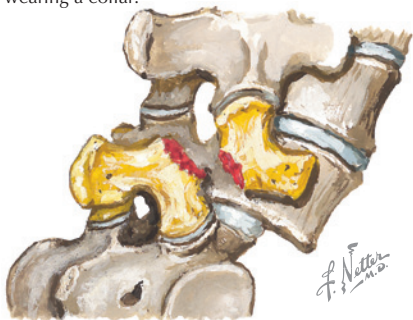
*F. Netter  
M.D.*

## Cervical Vertebral Fractures



Posterior oblique view showing radiographic Scotty dog. In simple spondylolysis, dog appears to be wearing a collar.

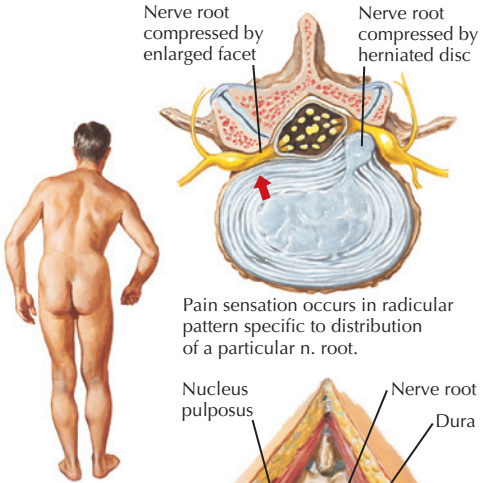
Opposite inferior articular process (hindleg)



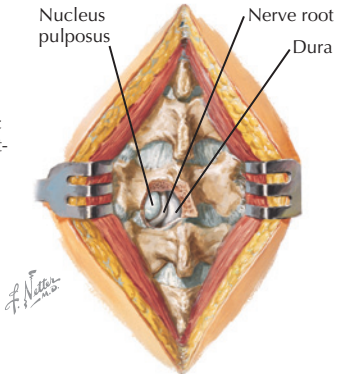
In spondylolisthesis, Scotty dog appears to be decapitated.

### Spondylolysis and Spondylolisthesis

## Radicular pain due to nerve root compression



Pain sensation occurs in radicular pattern specific to distribution of a particular n. root.

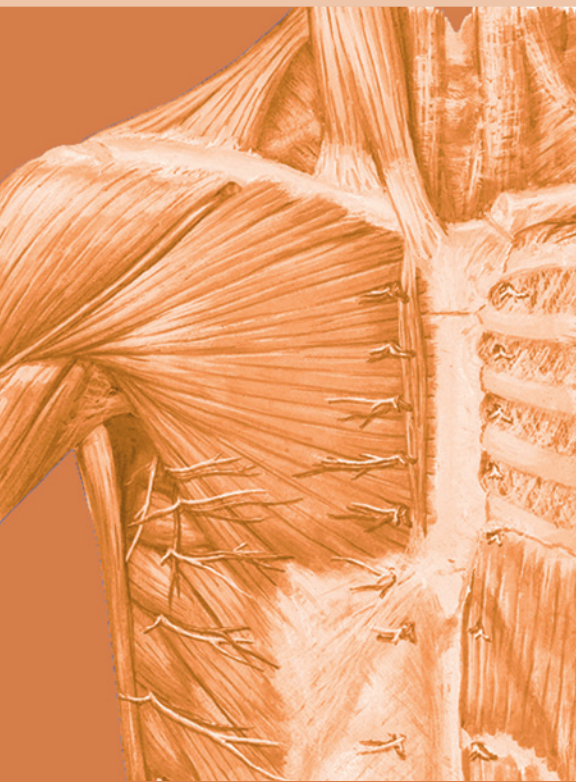


Surgical exposure of lower lumbar disc herniation

## Herniation of Lumbar Disc

This page intentionally left blank

# Thorax



This page intentionally left blank



# 4

## Breast Diseases

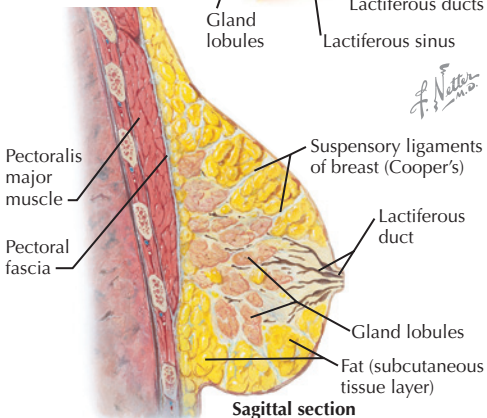
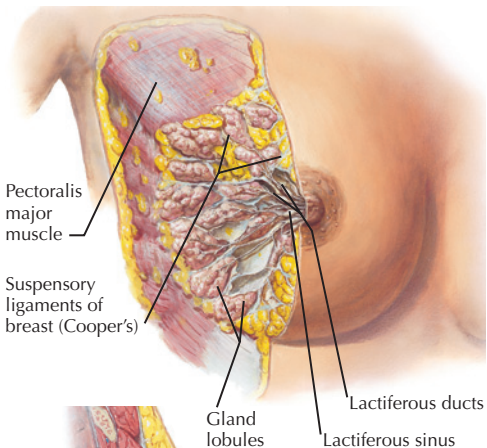
### **ANATOMY OF THE BREAST**

#### **Basic Structure**

- Adipose tissue and lactiferous glands lie between superficial and deep layers of superficial thoracic fascia.
- Cooper's (suspensory) ligaments: partitions of fibrous connective tissue running from the deep fascia over the pectoralis major, external intercostals, and serratus anterior, through the breast parenchyma, to the dermis and superficial fascia
- Cooper's ligaments form septa around glandular clusters and fat.
- Lactiferous ducts communicate with openings on nipple and areola.
- Accessory glands in areola: Montgomery's tubercles
- Nipple contains skin, connective tissue, sebaceous glands, smooth muscle, vessels, and ducts.

#### **Endocrinology**

- Estrogen (e.g., in pregnancy) and tissue-based estrogen receptors control glandular proliferation and secretory states in concert with progesterone and other hormones and growth factors.
- Cyclic increases in estrogen level cause swelling and promote glandular growth.



**Mammary Gland**

- Cyclic increases in progesterone increase glandular maturation; decreases are associated with menses.

### Sensory Innervation

- Cutaneous and deep, lateral cutaneous branches of T2-T6
- Nipple, T4, anterior and anterolateral (cutaneous) branches of 4th intercostal nerves
- Nerve compression by surrounding muscle can cause pain (e.g., Tietze's syndrome, T4).

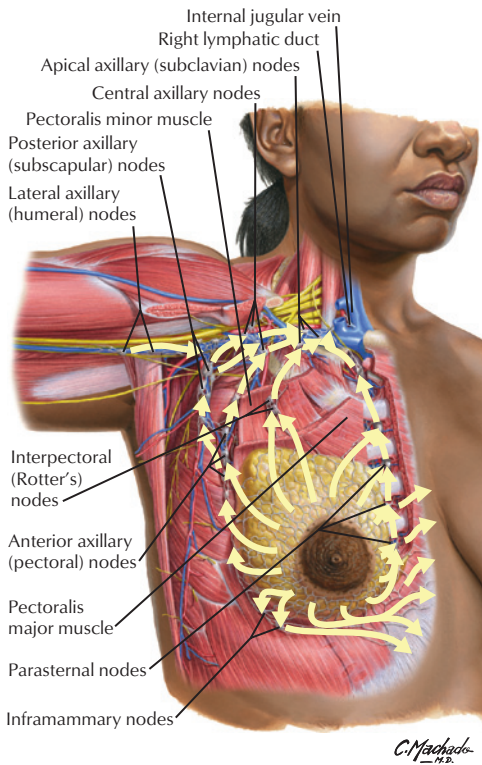
### Development and Embryology

- Ducts and alveoli of glands are formed from invaginating ectoderm.
- Supporting connective tissue, blood vessels, and lymphatics are formed from mesenchyme.
- Embryonic mammary ridges extend from axilla to inguinal region; all but the most superior usually regress.
- Accessory or supernumerary nipples may be found along "this milk line."
- Accessory axillary breast tissue is a developmental anomaly.

## VESSELS AND LYMPHATICS

### Arterial Supply

- Medial: internal thoracic (mammary) artery, branch of subclavian (first division)
- Superior: supreme thoracic artery, branch of axillary (first division)
- Lateral: thoracoacromial, lateral thoracic, circumflex scapular, subscapular, and thoracodorsal branches of the axillary artery (second and third divisions)



Lymphatic Drainage of Breast

- Inferolateral: contributions from lateral (perforating) branches of intercostal arteries

## Venous Drainage

- Drainage toward the axilla and axillary vein via named branches, including supreme thoracic, thoracoacromial, lateral thoracic, circumflex scapular, subscapular, and thoracodorsal
- Deep and medial drainage, including chest wall
  - Anteriorly to intercostal veins and into the internal thoracic (mammary) veins
  - Posteriorly through posterior intercostal veins into the azygos and hemiazygos vein systems

## Lymphatic Drainage

- Drainage is extensive and multidirectional.
- Main flow is lateral, to *axillary nodes*.
  - Level I: lateral and inferior to the lower border of the pectoralis minor
  - Level II: deep, posterior to the pectoralis minor, including Rotter's nodes between the pectoralis muscles
  - Level III: above or medial to the upper border of the pectoralis major, including subclavicular and supraclavicular nodes
- Deep flow is along internal thoracic (mammary) vessel pathways to parasternal nodes, draining toward subclavian, supraclavicular, and deep cervical nodes.
- Metastasis spreads through groups of nodes in an unpredictable manner.
- Location of sentinel node (nearest, with metastasis) in axilla depends on the patient's

specific drainage pattern from the tumor site.

- Dye, tracer, or biopsy can miss real sentinel nodes (false negatives).

## CLINICAL CORRELATES

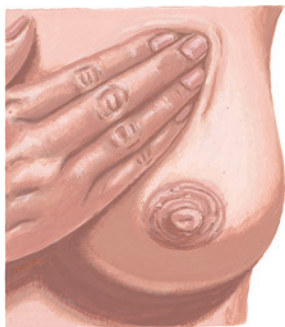### Diagnostic Procedures

- X-ray mammography is the gold standard.
  - ~90% sensitivity and specificity, overall
  - Sensitivity low in young women due to greater density of parenchymal tissue
- Magnetic resonance imaging (MRI) is helpful in determining the extent of disease.
- Given clinical exam and positive mammography evidence, diagnosis of malignancy must be made by a pathologist: care is needed in biopsy procedures.
  - Fine needle aspiration biopsy (FNAB)
  - Core needle biopsy (CNB)
  - Excisional biopsy: lesion plus margins; specimen should be anatomically oriented by labeling margins, so pathologist can identify margins that may be involved.
- Appropriate pathological analysis includes histological grading, estrogen and progesterone receptor levels, and Her-2/neu receptor status (if appropriate for systemic therapy).

### Benign Disease

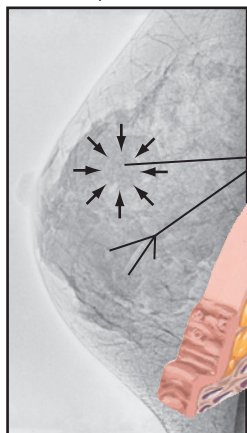
#### *Classification*

- Nonproliferative with no increased risk of neoplasia
- Proliferative, relative risk 1.5-2.0
- Proliferative with atypia, relative risk 4.5-5.0

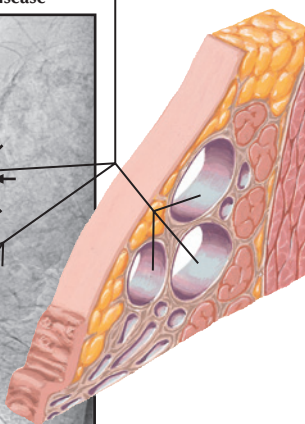


Often detected on self-examination as a mass that may fluctuate in size in different phases of the menstrual cycle

### Fibrocystic disease



Multiple, well-demarcated cysts within breast tissue



Fibrocystic Disease

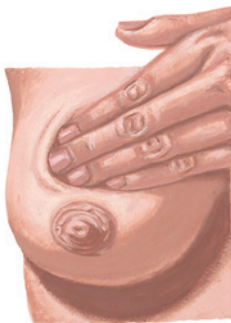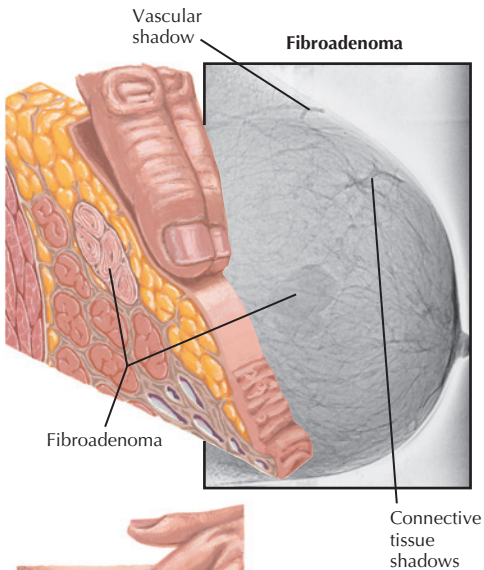
### *Fibrocystic Disease*

- Multiple types
- Symptoms: pain, nipple discharge, masses, lumps that vary with menstrual cycle
- Atypical ductal or lobular hyperplasia
- Sclerosing adenosis can appear as a cluster of calcifications without pain or apparent mass and might look like cancer on mammogram.

### *Other Benign Breast Diseases*

- Abscesses and infectious mastitis
  - May be associated with breast-feeding
  - Commonly caused by *Staphylococcus aureus*
- Fibroadenomas: most common in adolescents and young women
- Cysts: discrete, can feel hard before menses, are visible on ultrasound
  - Simple: might disappear after aspiration
  - Complex: might require excision, especially if solid components are imaged
- Ductal ectasia: ducts ending in areolar tissue, may become infected
- Papillomas
  - Intraductal are the most common cause of blood discharge from nipple.
  - Not premalignant, but studied for atypia
  - Excision is often recommended.
- Phyllodes tumors
  - Resemble fibroadenomas, but are pathologically distinguished by proliferation of stromal and epithelial cells compressing surrounding tissue
  - High recurrence rate, excision recommended





Usually palpated as a solitary, smooth, firm, well-demarcated nodule

JOHN A. CRAIG AD

Fibroadenoma

- Cystosarcoma phyllodes: malignant variant of phyllodes tumor
- Sclerosing adenosis and radial scars: can give radiological appearance of infiltrating cancer
- Superficial venous thrombophlebitis (cordlike) may be associated with trauma and strenuous activity (e.g., Mondor's disease).

### Premalignant Lesions

#### *Ductal Carcinoma in Situ (DCIS)*

- Considered a premalignant lesion
- 50% ipsilateral cancer risk with unresected lesions
- 5%-10% progress to contralateral breast cancer.
- Not palpable, with cluster calcifications
- Characterized by malignant duct cells that do not invade the basement epithelium
- Treatment
  - Lumpectomy with radiation or chemotherapy for small-focus lesions
  - Simple mastectomy for high-grade (comedo-type or multicentric or multifocal) lesions

#### *Lobular Carcinoma in Situ (LCIS)*

- Considered a marker for the development of cancer
- 40% progress to cancer.
- Not palpable, no calcifications
- Patients whose lesions progress to cancer are more likely to develop ductal carcinoma.
- Primarily a premenopausal disease
- Often found incidentally

## Breast Cancer

### *Carcinoma: Risk Factors*

- Risk is 1/9 for white American women; rate for Latin American and black women has been lower but is catching up.
- Lobular carcinoma in situ may be a precursor of invasive lobular disease.
- 5%-10% of patients have a mutation in *BRCA1* or *BRCA2* genes.
  - *BRCA1* (chromosome 17q): hereditary breast and ovarian cancer syndrome
  - *BRCA2* (chromosome 13, q12-13 region): in families with heredity male breast, prostate, or pancreatic cancer
- Other factors: personal history of breast cancer, prior exposure to ionizing radiation (e.g., therapeutic), increasing age
- Early onset of menses is associated with increased risk
- Current evidence is equivocal on risk with contraceptives and hormone therapy.
- About 2% of all breast cancers occur in men.

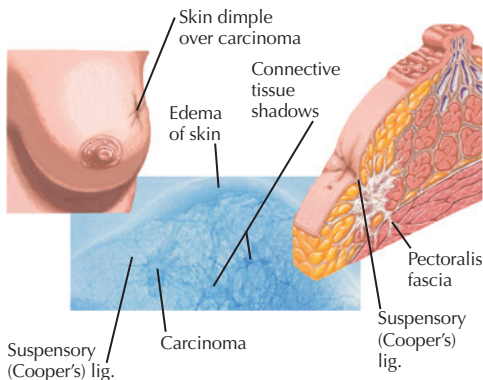
### *Paget's Disease of the Breast*

- Epithelial neoplasia beginning in nipple and areola, extending through ducts to deeper tissues
- Invasive disease is treated like ductal or lobular cancer.

### *Clinical Signs*

- Tumors involving Cooper's ligaments cause skin dimpling.
- Carcinoma involving the mammary ducts causes nipple retraction.

Dimpling of skin over a carcinoma is caused by involvement and retraction of suspensory (Cooper's) ligaments.



JOHN A. CRAIG, MD

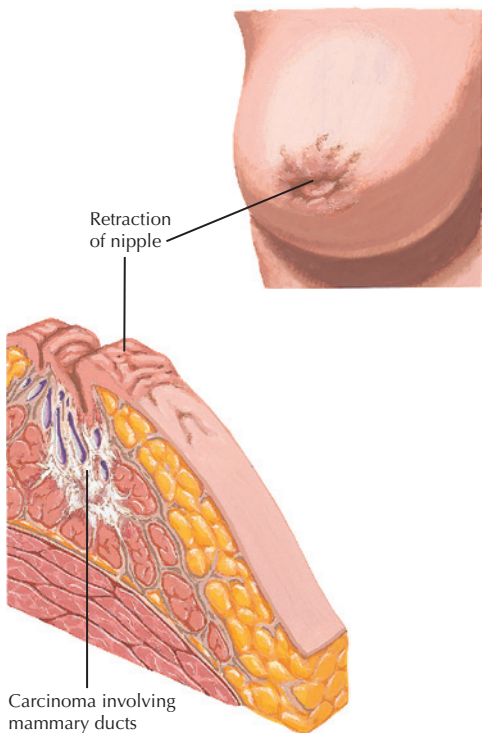
### Skin Dimpling

- Carcinomatous invasion of subcutaneous lymphatics causes lymphedema, with orange peel (peau d'orange) appearance of the skin.

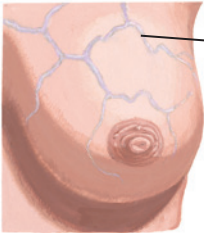
### Staging and Treatment

- Treatment has long been based on principles of tumor cell biology, which practically require staging, assessing the anatomical progression of tumors.

Carcinomatous involvement of mammary ducts may cause duct shortening and retraction or inversion of nipple.



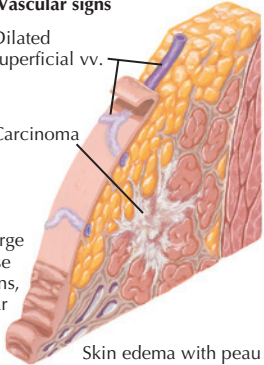
Nipple Retraction



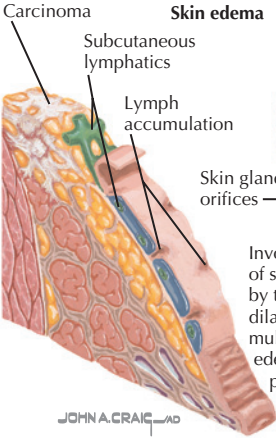
**Vascular signs**

Dilated superficial vv.

Carcinoma



Fast-growing tumor with large vascular demand may cause dilatation of superficial veins, creating prominent vascular pattern over breast.



**Skin edema**

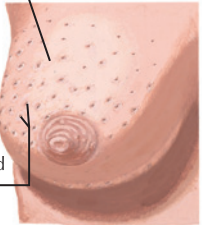
Carcinoma

Subcutaneous lymphatics

Lymph accumulation

Skin edema with peau d'orange appearance

Skin gland orifices



Involvement and obstruction of subcutaneous lymphatics by tumor result in lymphatic dilatation and lymph accumulation in the skin. Resultant edema creates "orange peel" appearance due to prominence of skin gland orifices.

JOHN A. CRAIG MD

**Clinical Signs of Breast Cancer**

- Staging
  - Current tumor/node/metastasis (TNM) system is based on clinical and pathological classification.
  - Primary tumor (T): scored by size and anatomical location, involvement of the chest wall
  - Lymph node status (N): scored by number, size, and location of affected nodes
  - Metastasis (M): scored based on evidence of spread to distant structures
  - Stages 0 through IV are based on a matrix of TNM scores, with stage 0 being newly diagnosed in situ disease (Tis) and stage IV being any combination of T and N scores with distant metastasis (M1).
  - With staging, indications for further treatment account for the specific location and extent of disease.
- Treatment
  - Lumpectomy
    - ▲ Breast-conserving therapy that excises identified lesions with surrounding clean margins.
    - ▲ Usually combined with x-ray therapy (XRT) as an alternative to simple mastectomy
  - Simple mastectomy (formerly total)
    - ▲ Standard of care for T1 and T2 cancers
    - ▲ Removal of entire breast, superficial and deep fascia, nipple and areola, level I and II axillary nodes
    - ▲ Reconstruction
  - Radical mastectomy
    - ▲ For stage II and III, as appropriate: entire breast, superficial and deep fascia, pectoralis

major, nipple, areola, axillary lymph node dissection (ANLD)

- ▲ Reconstruction, postoperative XRT, and systemic therapy
- ANLD must avoid damaging the long thoracic nerve (to serratus anterior), as it lies on the lateral thoracic wall (medial wall of axilla).
- Chemotherapeutic adjuncts, alternatives
  - ▲ Breast cancer systemic therapy
  - ▲ Adjuvant systemic therapy
  - ▲ Neoadjuvant (induction chemotherapy)



# 5

## Heart Diseases

### **ANATOMY OF THE HEART**

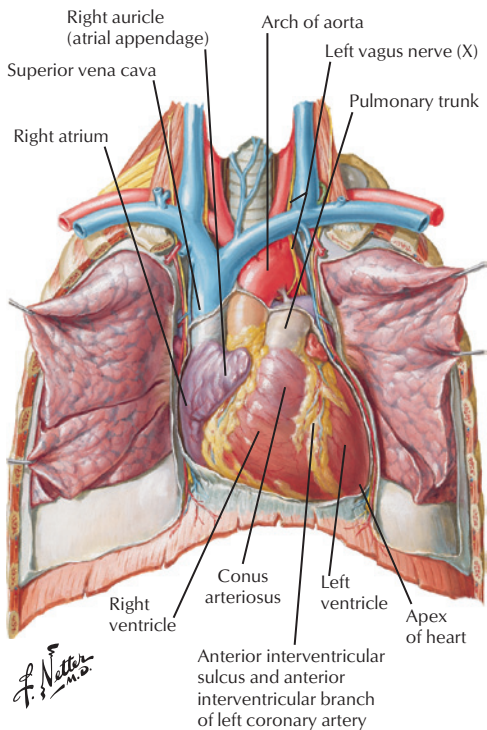
#### External Features of the Heart: Right to Left Heart (Circulatory) Approach

- Superior and inferior vena(e) cava(e) (SVC/IVC): drainage of upper and lower body
- Right atrium: auricle (atrial appendage), sinoatrial node, coronary sulcus
- Right ventricle: inferior border in frontal view; interventricular sulcus
- Pulmonary artery: trunk, with right and left arteries passing under aortic arch
- Pulmonary veins: posterior to the rest of the heart, short course into left atrium (LA)
- Left atrium: auricle
- Left ventricle: left upper aspect frontal view, apex, posterior interventricular sulcus
- Aorta: arch and brachiocephalic, carotid, and subclavian branches (see later)
- Coronary arteries
  - Right coronary artery and branches: sinoatrial (SA) nodal artery (~60%), marginal, posterior interventricular, atrioventricular (AV) nodal
  - Left coronary artery and branches: typical branches, anterior interventricular (descending), marginal, circumflex, SA nodal (~40%)
  - Variations in arterial branching patterns: left versus right dominant

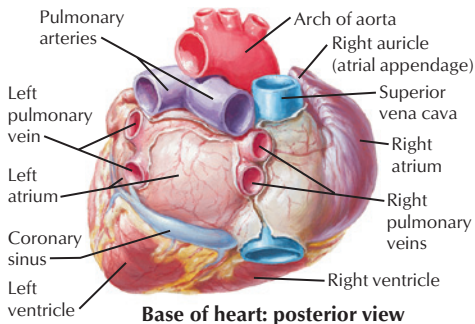
- Cardiac veins (great, middle, anterior, small) and coronary sinus

### Internal Features of the Heart: Right to Left Heart (Circulatory) Approach

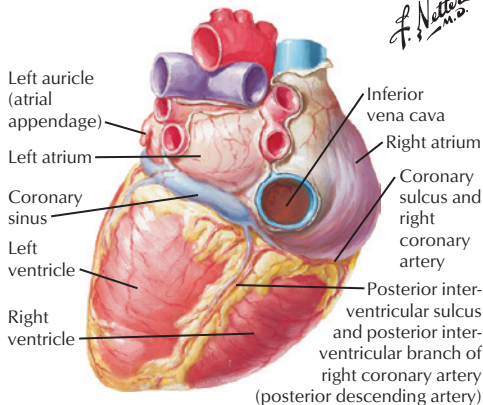
- Right atrium: smooth portion, pectinate muscles, crista terminalis, fossa ovalis, coronary sinus ostium (opening), valve, valve of IVC
- Tricuspid valve: cusps (“leaflets”), chordae tendineae, papillary muscles
- Right ventricle: trabeculae carneae, papillary muscles, septum
- Pulmonary artery: trunk, right and left
- Pulmonary valve: three semilunar cusps, like aortic,
- Pulmonary veins: typically four, two from each
- Left atrium: posterior position, septal wall
- Mitral valve (like a bishop’s miter): two leaflets (bicuspid), with chordae tendineae
- Left ventricle: trabeculae carneae, papillary muscles, septum
- Aortic valve: semilunar cusps—right, left, anterior/noncoronary
- Aorta: openings (ostia) of right and left coronary arteries above right and left valve cusps in aortic sinuses
- Cardiac conduction system: composed of specialized P cells and Purkinje fibers, different from typical branched, striated myocardial cells
- Sinoatrial node: the pacemaker, located in the anterior right atrial wall near the SVC
- Atrioventricular node: in posterior interatrial septum, near coronary sinus ostium



Heart in Situ



*F. Netter M.D.*



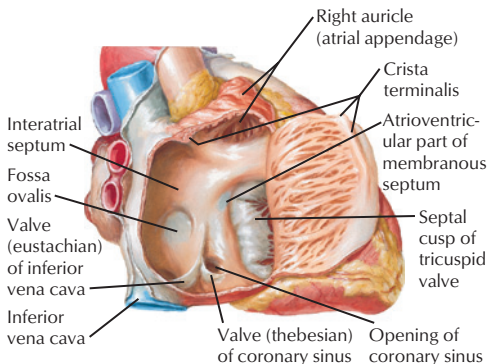
**Base and diaphragmatic surface:  
posteroinferior view**

### External Features of the Heart

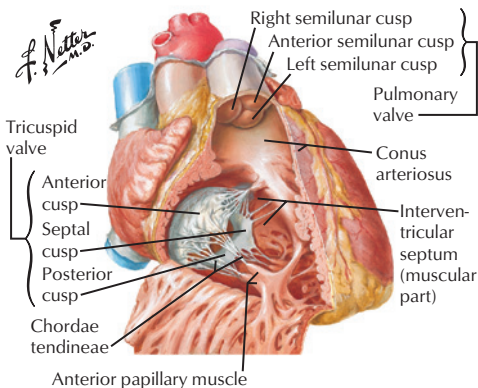
- Atrioventricular bundle (of His): discrete fiber bundle located in septum below the AV node, continuous with both the bundle branches
- Right bundle branch: spreads activation potentials into right ventricular (RV) myocardium
- Left bundle branch: spreads activation potentials into left ventricular (LV) myocardium
- Pacemaker rate and conduction controlled by sympathetic and parasympathetic innervation and circulating catecholamines

## Pericardium

- Collectively, the layers of the pericardium form a closed sac around the heart.
- Fibrous pericardium
  - Outermost, tough, *inexpansible* layer of pericardial sac merges with the adventitia around the ascending aorta, pulmonary trunk, venae cavae, and pulmonary veins.
  - Fuses to the central tendon of the diaphragm below the inferior (diaphragmatic) surface of the heart.
- Serous pericardium
  - *Serous mesothelial membrane* normally secretes small amount of fluid to permit the heart to move freely.
  - *Visceral (serous) pericardium* lines the myocardial surfaces of the heart and the initial sections of the great vessels; also known as *epicardium* on the cardiac surfaces.
  - *Parietal (serous) pericardium* lines the inner surfaces of the fibrous pericardial sac.
  - Visceral and serous layers are continuous, connecting at reflections around the great vessels.

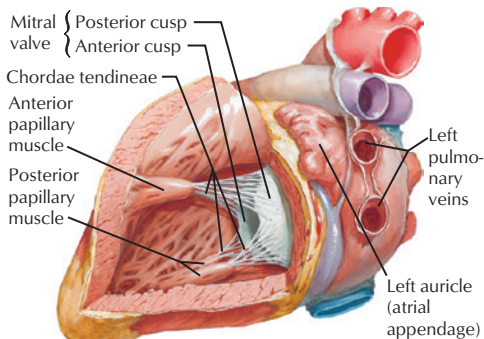


### Opened right atrium: right lateral view

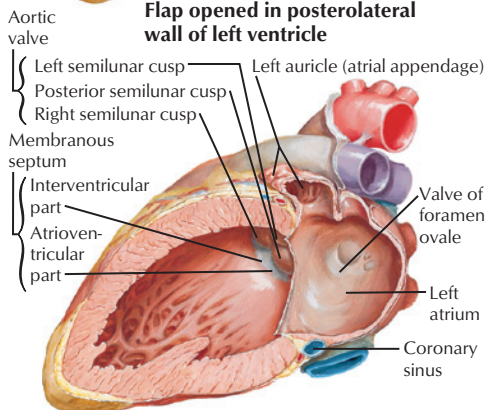


### Opened right ventricle: anterior view

Internal Features of the Right Atrium  
and the Right Ventricle



**Flap opened in posterolateral wall of left ventricle**



**Section through left atrium and ventricle with mitral valve cut away**

**Internal Features of the Left Atrium and the Left Ventricle**

*F. Netter M.D.*

- Pericardial reflections create “partitions” between the great vessels where they penetrate the pericardial sac.
- *Oblique pericardial sinus*: cul-de-sac posterior to the base of the heart, formed by pericardial reflections around the venae cavae and the pulmonary veins
- *Transverse pericardial sinus*: potential space between pericardial layers surrounding initial sections of the superior vena cava, aorta, and pulmonary trunk
- Pericardium receives bilateral blood supply from the *pericardiophrenic arteries*, which travel with the phrenic nerves and corresponding veins in neurovascular bundles running on the right and left surfaces of the sac.
- Pericardium receives *sensory innervation* via branches from the *phrenic nerves*.

## Cardiac Embryology

### *Early Development, Weeks 3 and 4*

- The cardiovascular system begins to develop at the end of the third week.
- Rostral to the neural plate, mesenchymal cells derived from the splanchnic mesoderm proliferate and form isolated cell clusters (“blood islands”), which soon coalesce into twin endocardial heart tubes.
- Other more caudal blood islands form the paired, longitudinal dorsal aortae.
- As the embryo folds anteriorly and laterally, the paired heart tubes meet at the midline and move inferior to the developing neural plate (“head”).



- The heart tubes fuse to form the primordial heart, which starts to beat at the beginning of the fourth week.
- Splanchnic mesoderm surrounding the heart tube condenses to form the primordial myocardium.
- The primordium of the heart consists of four partial “chambers”: bulbus cordis, ventricle, atrium, and sinus venosus (in rostral-caudal order).
  - The bulbus cordis develops into the trabeculated part of the right ventricle, the conus cordis (ventricular outflow path), and the truncus arteriosus.
  - The truncus is continuous with the aortic sac and roots.
- As the embryonic heart grows, it forms a cardiac loop and soon acquires the familiar “adult” conformation.

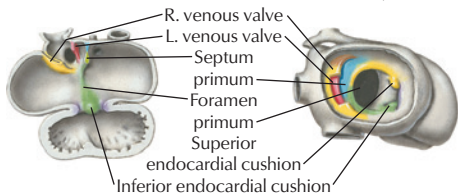
### *Septation, Weeks 4-7*

- The heart becomes completely partitioned into four chambers between the fourth and seventh weeks of development. Major septa form between 27 and 37 d.
- The further partitioning of atria and ventricles begins with the ingrowth of dorsal and ventral endocardial cushions. Fusion of the cushions creates right and left atrioventricular canals, around which the atrioventricular (tricuspid and mitral) valves will develop.
- Partitioning of the atria begins with the descent of a crescent-shaped septum primum, creating an interatrial foramen (or ostium) primum above the endocardial cushions.

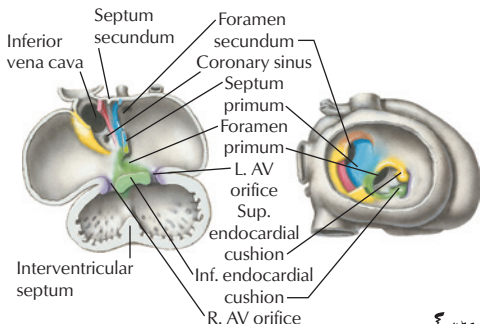
Inferior halves  
of heart  
viewed from  
above

Opened and  
viewed from  
right side

(Segment removed from  
R. venous valve to expose  
L. venous valve)



**6.5 mm (29 days)**



**9 mm (33 days)**

Division of the Heart Chambers

*F. Netter M.D.*

- Before the first foramen can close, the septum primum breaks down superiorly, creating the ostium secundum.
- Soon the septum secundum grows down just to the right of the primum, leaving a gap, the foramen ovale, with the septum primum forming its valve.
- During this same period, partitioning of the ventricles begins with the upgrowth of an inferior interventricular septum toward the endocardial cushions.
- As development progresses, an interventricular canal remains between the endocardial cushions and the muscular interventricular septum.
- As basic development is completed, a portion of the endocardial cushion produces the membranous septum, closing off the interventricular canal.
- The truncus arteriosus is partitioned into the pulmonary artery and the aorta by the ingrowth of conotruncal ridges in a spiral fashion.
  - Migrating neural crest cells form truncus swellings (cushions) in the right and left walls.
  - Similar swellings develop more inferiorly in dorsal and ventral walls of the conus cordis (conus swellings).
  - Truncus and conus swellings grow spirally upward, becoming fused conotruncal ridges.
  - Ridges from either side meet and fuse at the midline, forming the aortopulmonary septum.
  - The right ventricular outflow channel thus comes to lie anterolateral to the left ventricular outflow tract (posteromedial).

### *Aortic Arch Development*

- As the pharyngeal arches form during the fourth and fifth weeks of development, they are penetrated by arteries—the aortic arches—that arise from the aortic sac.
- During the sixth to eighth weeks of development, the aortic arches are transformed into the adult arterial arrangement of the carotid, subclavian, and pulmonary arteries.

### *Sinus Venosus Development*

- Three systems of paired veins drain into the sinus venosus of the primordial heart (starting in the 5th week):
  - Vitelline veins (which become the portal system draining the gut)
  - Cardinal veins (common, anterior, posterior, drain the body; form the caval system, brachiocephalic veins, and coronary sinus)
  - Umbilical system with ductus venosus (which involutes after birth)

### *Innervation*

- The cardiac nerve plexus is composed of vagal afferent and efferent, sympathetic efferent, and segmental (visceral) afferent components.
- Parasympathetic preganglionic fibers
  - Upper portion from cervical branches of the vagus
  - Thoracic portion from the vagus via the cardiac and pulmonary (peribronchial) plexuses
  - Ganglion cells located adjacent to sinoatrial and atrioventricular nodes

- Sympathetic postganglionic fibers
  - Via nerves from cervical and thoracic chains
  - From cervical ganglia and thoracic ganglia
- Sensory fibers (visceral afferent)
  - Vagus: stretch, chemoreceptor, nociceptor; to vagal ganglia
  - Segmental (parallel to sympathetics) with spinal nerves; to cervical and thoracic dorsal root ganglia

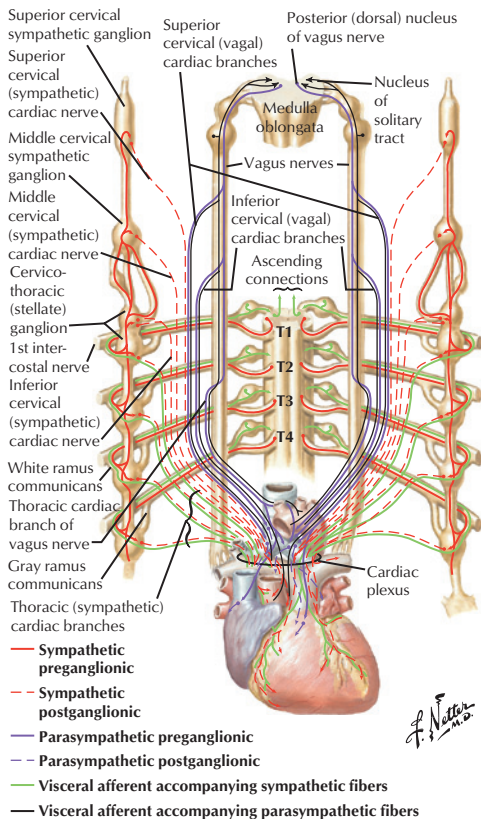
## VESSELS AND LYMPHATICS

### Arteries of the Heart

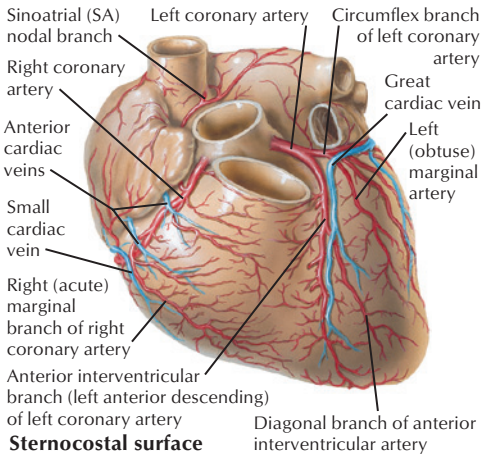
- Branching patterns variable and highly individual—“typical” branching scheme (ordinal) follows
- Right coronary artery: sinoatrial (nodal), right marginal (acute), posterior interventricular (descending)
- Left coronary artery: anterior interventricular (descending), diagonal, left marginal, circumflex
- Right dominant circulation: most common; posterior interventricular (descending) comes off of right coronary
- Left dominant circulation: posterior interventricular (descending) comes off of the circumflex branch
- Rare variants may include all right or all left circulations, with all branches off of a single main artery.

### Veins of the Heart

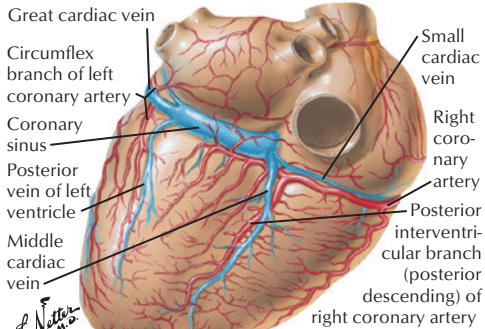
- Most of the cardiac veins drain myocardial blood into the *coronary sinus*, which empties into the right atrium; venous branches are highly variable.



Nerves of the Heart



**Sternocostal surface**



**Diaphragmatic surface**

**Arteries of the Heart**

- *Great cardiac vein* runs parallel to the anterior interventricular (descending) artery in the anterior interventricular sulcus; continues directly into the coronary sinus in the posterior atrioventricular sulcus.
- *Middle cardiac vein* runs parallel to the posterior interventricular (descending) artery in the posterior interventricular sulcus; continues directly into the terminal part of the coronary sinus.
- Typically, *left marginal* and *posterior left ventricular veins* drain the anterior and posterior aspects of the left ventricle; the former drains into the great cardiac vein (or left atrium) and the latter drains into the coronary sinus.
- *Small cardiac vein* drains the right ventricle, parallel to the right marginal artery; runs in the right atrioventricular groove to empty into the terminal part of the coronary sinus.
- *Anterior cardiac veins* drain from the anterior superior right ventricle directly into the right atrium (transmurally).

### Cardiac Lymph Vessels and Nodes

- Interstitial lymphatic drainage from the myocardium flows from subendocardial vessels to an extensive capillary plexus lying throughout the subepicardium.
- Lymphatic capillaries empty into valved drainage vessels that parallel coronary artery branches.
- Cardiac drainage vessels empty into cardiac, aortic arch (“ligamentum arteriosum”), bronchopulmonary, and superior mediastinal lymph



nodes, which then drain into the thoracic duct or right (subclavian) lymphatic duct; nodes vary individually.

- Lymphatic circulation is important in maintaining cardiac hemostasis by draining excess fluid, electrolytes, protein, and cells from interstitial fluid; important in failure, myocardial infarction (MI), infection.

## CLINICAL CORRELATES

### Congenital Heart Disease

- Congenital heart defects common: frequency ~6 to 8 per 1000 births
- Critical period of heart development extends from ~ day 20 to day 50 after fertilization.
- Although some cardiac birth defects may be caused by single gene or chromosomal defects or teratogen exposure (e.g., retinoic acid, rubella virus), most are considered to involve multifactorial inheritance factors.
- Because partitioning of the primordial heart results from complex cellular and molecular processes that are easily disrupted, defects of the cardiac septa are relatively common, particularly ventricular septal defects.
- Failure of appropriate circulatory changes to occur at birth is the cause of two of the most common congenital anomalies of the heart and great vessels: patent foramen ovale and patent ductus arteriosus.
- Congenital heart defects can include those involving the atria, ventricles, and major vessels and valves, frequently in combination (congenital heart disease).

- Some congenital anomalies result from abnormal transformation of the aortic arches into the adult arterial pattern (e.g., right aortic arch).

### Atrial Septal Defects (ASDs)

- Four clinically significant types
  - Ostium secundum defect
  - Endocardial cushion defect with a foramen (ostium) primum defect
  - Sinus venosus defect
  - Common atrium

### Ventricular Septal Defects (VSDs)

- VSD is the most common kind of congenital heart defect.
- VSDs usually involve the membranous part of the interventricular septum.
- Many of these smaller defects may close spontaneously during the first year after birth, but large VSDs may cause a massive left-to-right shunting of blood.
- VSDs frequently occur in combination with defects of the great arteries.
- Significant defects may necessitate surgical treatment to support normal growth and a more active life for the affected person.

### Arterial Abnormalities

- Transposition of the great arteries (aorta and pulmonary arteries) may occur due to abnormal development of the septation of the bulbus and truncus arteriosus.
- Remember that this aortopulmonary septation involves the migrating neural crest, so teratogens

affecting the crest may include transposition with other dysmorphologies (e.g., facial).

- Transposition of the great arteries is the most common cause of cyanotic heart disease in newborns.

## Valvular Abnormalities

- Aortic and pulmonary (semilunar) valves develop as part of the partitioning of the truncus arteriosus, with the cusps first appearing as minor anterior and posterior swellings (tubercles).
- After the atrioventricular cushions fuse, the atrioventricular valves are formed from dense mesenchyme at the rim of each atrioventricular orifice.
- Valves may be developmentally compromised by the following:
  - Incomplete truncus partitioning and endocardial cushion defects
  - Obstructive narrowing above or below in concert with other cardiac malformations (see [Tetralogy of Fallot](#))

## Patent Ductus Arteriosus

- In a normal birth, the ductus arteriosus “shunt” existing between the pulmonary artery and the aorta functionally closes down, as smooth muscle in the ductus contracts with increasing oxygen tension.
- Anatomic closure of the ductus arteriosus (producing the ligamentum arteriosum) typically occurs by the 12th week after birth.

- Premature infants or those born at high altitude may have a persisting ductus arteriosus, due to immaturity or low oxygen tension.
- Patent ductus arteriosus may accompany other kinds of congenital heart malformations (e.g., see [Tetralogy of Fallot](#)).

### Patent Foramen Ovale

- Most common form of ASD
- Small isolated defects frequently of little hemodynamic consequence
- However, in the presence of other defects, a large fraction of the blood flow may be shunted from right to left, bypassing the lung and producing cyanosis (bluish skin coloration indicating poor oxygenation).

### Tetralogy of Fallot

- Classic grouping of four cardiac defects:
  - Ventricular septal defect
  - Overriding aorta (dextroposition of the aorta)
  - Pulmonary artery stenosis (obstructed right ventricular outflow)
  - Right ventricular hypertrophy
- Mnemonics: VAPR or PROV

### Persistent Truncus Arteriosus

- Persistent truncus arteriosus (TA) occurs when the truncal ridges and the aorticopulmonary septum fail to divide the truncus into separate aorta and pulmonary artery trunks.
- Persistent TA may occur in several different ways, and a VSD is always present.

## Congenital Aortic and Pulmonary Stenoses

- Congenital aortic stenosis and pulmonary stenosis are obstructive narrowings of the individual valve channels.
- In valvular aortic stenosis, the thickening of valve cusps may be so complete that only a tiny opening remains for blood flow.
- Recall that pulmonary stenosis is one of the defining features of tetralogy of Fallot and that abnormal truncal partitioning resulted in a very small pulmonary artery and a larger, overriding aorta.

## Coarctation of the Aorta

- Coarctation (or congenital constriction) occurs in about 10% of children and adults with congenital heart defects.
- Coarctations may be proximal (preductal) or distal (postductal) to the ductus arteriosus, although in many cases, they may be directly opposite the ductus.
- With preductal coarctation, a patent ductus arteriosus conducts blood from the pulmonary artery to the distal aorta.
- With postductal coarctation, blood can be shunted to the distal aorta via collateral flow through the subclavian, internal thoracic (ITA), and intercostal arteries, with ITA pulse felt parasternally.

## Adult Cardiovascular Disease

- Coronary artery disease is still the most common cause of adult deaths in the United States.

- Risk factors: hypertension, smoking, hyperlipidemia, diabetes, family history
- Most atherosclerotic lesions proximal
- Complications of myocardial infarction
  - Papillary muscle rupture, free wall rupture
  - LV aneurysm—most common after large anterior transmural MI; Sx—congestive heart failure, arrhythmias, angina; surgical indications—refractory arrhythmias, Sx
  - VSD: 3-5 days post MI; pansystolic murmur, increase in O<sub>2</sub> content between right atrium and ventricle due to L→R shunt; transesophageal echo best for assessment

### *Treatments*

- Medical: statins, dietary change, weight loss, nitrates (vasodilators), aspirin
- Percutaneous transluminal coronary angioplasty (PTCA): rate of restenosis 20%-30% <1 year
- Saphenous vein bypass graft: 80%-90% 5-year patency
- Internal mammary (thoracic) artery: currently considered best coronary angioplasty bypass graft; anastomotic pathway between subclavian and superior epigastric arteries; >90% 10-year graft patency rate
- Coronary artery bypass graft (CABG) procedure
  - Potassium and cold solution cardioplegia: arrests heart in diastole, protects, keeps it still during grafting
- CABG indications
  - Left main disease or equivalent (left anterior descending artery [LAD] >70% occl. + prox. L complications)

## Cardiovascular disease in the elderly

**Stroke**

**Coronary artery disease (CAD)**

↑ incidence of comorbidities: → high risk of adverse drug effects with polypharmacy

Absolute risk of CAD/MI and stroke increases with age: ~85% of cardiovascular deaths occur after age 65

**Clinical signs** Atypical initial presentation of CAD (sx: dyspnea or heart failure) may delay diagnosis

Dyspnea

Signs of congestive heart failure (CHF)

**Management goals**

Aggressive management of hypertension

Primary and secondary prevention by LDL reduction

Significant decrease in morbidity and mortality from cardiovascular event

## Cardiovascular disease in women

**Risk factors**

Diabetes in women is a more powerful risk factor than in men (3-7 times increase in CAD development)

Smoking: stronger risk factor for MI in middle-aged women than men.

Cardiovascular disease is leading cause of death in both men and women. More women die of cardiovascular disease than of breast cancer.

*C. Machado*  
—M.D.

**Clinical presentation**

“Heartburn”-type symptoms due to CAD

Back pain is a common “anginal equivalent” in women.

## Cardiovascular Disease in the Elderly and in Women

- Three-vessel disease
- Two-vessel disease + proximal LAD stenosis + either LV ejection <50% or extensive ischemia on noninvasive imaging
- One- or two-vessel disease with stable angina, large area viable myocardium + high-risk criteria on noninvasive testing *or* with life-threatening arrhythmias *or* with disabling stable angina despite medications when acceptable risk
- High mortal risk factors for CABG: emergency operation (#1), age, reoperation, low ejection fraction

### Valvular Disease

- Most common cause of valve dysfunction: rheumatic heart disease—mitral most common
- Most common valve lesion: aortic stenosis
- Stenosis is predominant; regurgitation occurs with progressive degeneration.
- Calcification causes stenosis.

### *Aortic Stenosis*

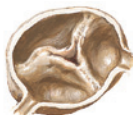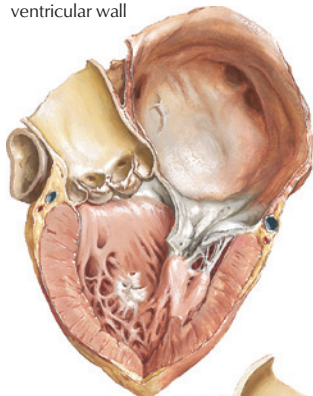
- Normal systemic pressures and adequate output maintained until late stage
- Left ventricular hypertrophy leads to decreased compliance, pulmonary congestion
- LV failure ultimate outcome
- Main symptoms
  - Angina (in ~65%; average survival 5 years)
  - Syncope (in ~25%; average survival 3 years)
- Indication for surgery: symptomatic

### *Aortic Insufficiency*

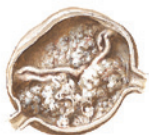- Volume load strain on left ventricle
- LV dilates, wall tension increases (Laplace's law)



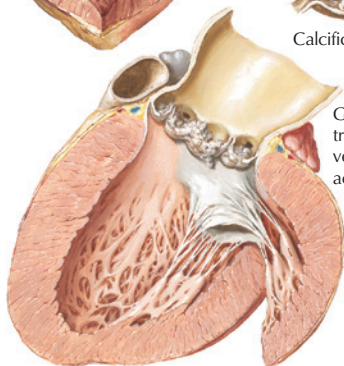
Thickened stenotic mitral valve: anterior cusp has typical convexity; enlarged left atrium; "jet lesion" on left ventricular wall



Stenosis and insufficiency (fusion of all commissures)



Calcific stenosis



Great hypertrophy of left ventricle in aortic stenosis

*F. Netter M.D.*

Elongation of left ventricle with tension on chordae tendineae, which may prevent full closure of mitral valve

## Valvular Heart Disease

- Cardiac output can be  $>30$  L/m
- Surgical repair indicated for functional class II heart failure, shortness of breath with exertion
- Sx may not develop until irreversible cardiac dysfunction present

### *Mitral Stenosis*

- Leads to pulmonary congestion
- Mural thrombi can develop; can go to cerebral vessels (~50%)
- Surgical indications: symptomatic, typically with valve area  $<1$  cm<sup>2</sup>

### *Mitral Regurgitation*

- Left ventricle dilates, wall tension increases
- End-stage disease: left atrium becomes less compliant; pulmonary congestion and right-sided heart failure develop; atrial fibrillation common
- Ventricular function is key index of disease progression
- Surgical repair indicated for functional class II heart failure, shortness of breath with exertion
- Sx may not develop until irreversible cardiac dysfunction present

### *Endocarditis*

- Symptoms: fever, chills, sweats
- Staphylococcus aureus: accounts for 50% of cases
- Native valve infections: mitral most common
- Prosthetic valve infections: aortic most common
- Most commonly left sided in non-drug-abusers
- Antimicrobial therapy: first Tx; 75% successful; 50% valve sterilized

- Surgical treatment: indicated in medical Tx failure, valve failure, pericarditis, perivalvular abscesses
- Endocarditis prophylaxis: periprocedural Tx indicated for patients with rheumatic heart disease, prosthetic valves, congenital malformations, mitral prolapse with regurgitation, previous hx of endocarditis

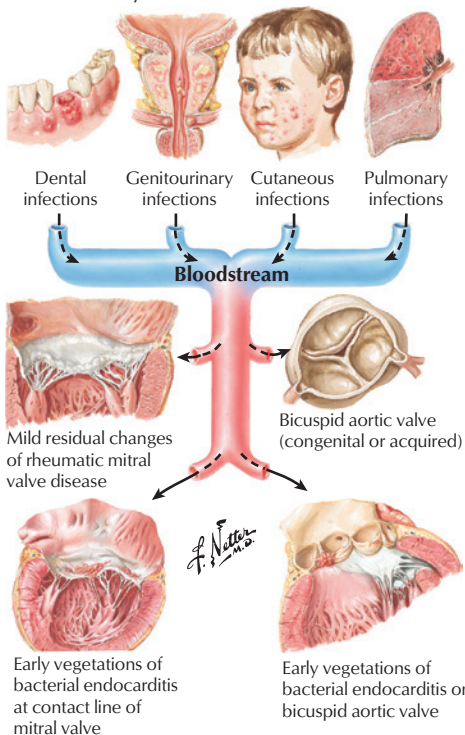
### Pacemakers and Defibrillators

- Endocardial leads are usually introduced via subclavian or brachiocephalic vein (left or right side), then positioned and tested.
- Pocket for the pulse generator is commonly made below the midclavicle adjacent to the venous access for the pacing leads. Incision is parallel to the inferior clavicular border, approximately 1 inch below it.
- Pulse generator is placed either into the deep subcutaneous tissue just above the prepectoralis fascia or into the submuscular region of the pectoralis major.

### Cardiac Tamponade

- Intrapericardial fluid accumulation decreases diastolic ventricular filling, produces hypotension
- First sign: decreased diastolic filling of right atrium on echocardiogram
- Beck's triad: jugular venous distension, hypotension, muffled heart sounds
- Tx: emergency; O<sub>2</sub> administration, initial fluid resuscitation, inotropic drugs; requires pericardiocentesis or pericardial window
- Positive pressure ventilation to be avoided due to possible decrease in venous return
- Pericardiocentesis blood is nonclotting.

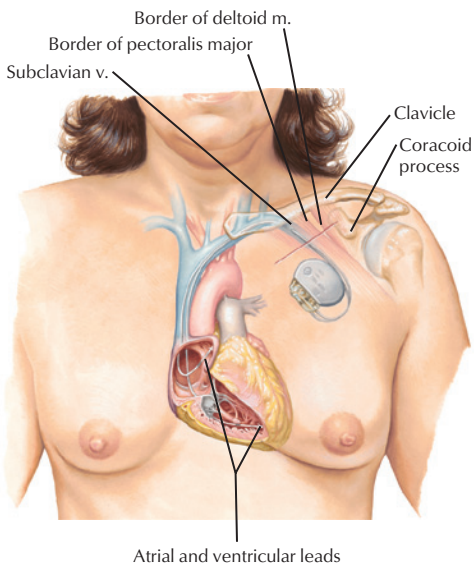
### Common portals of bacterial entry in bacterial endocarditis



### Common predisposing lesions

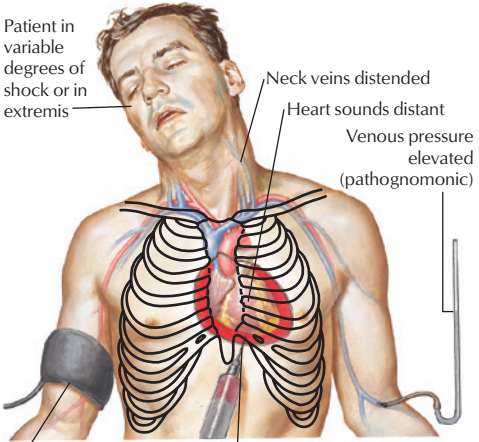
Endocarditis

## Implantable cardiac pacemaker (dual-chamber cardiac pacing)



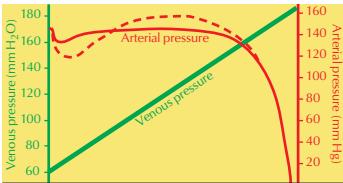
*C. Machado*  
— M.D.

Cardiac Pacemaker



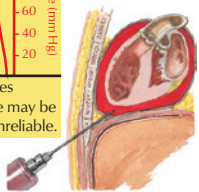
Decreased arterial and pulse pressures often exist but not pathognomonic

Pericardial tap at Larrey's point (diagnostic and decompressive)



In cardiac tamponade venous pressure rises progressively and linearly; arterial pressure may be normal or elevated and is diagnostically unreliable.

*F. Netter M.D.*



Cardiac Tamponade

# 6

## Lung Diseases

### ANATOMY OF THE LUNGS

#### External Features of the Lungs

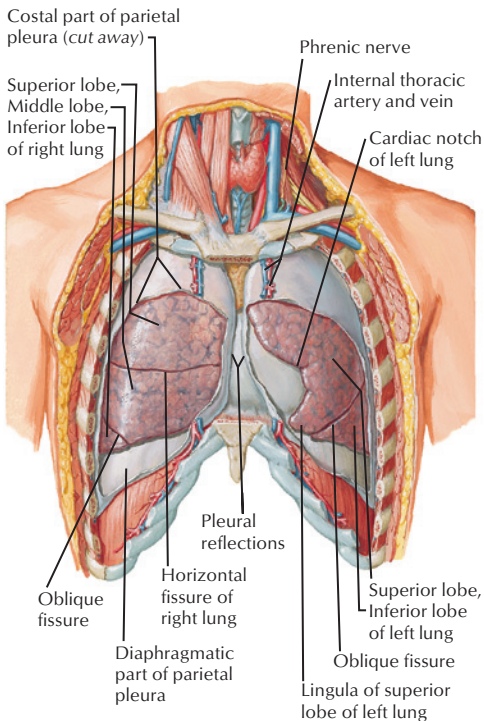
- Parenchymal surfaces of the lungs are enclosed by visceral pleura.
- Parietal pleura covers the inner chest walls, mediastinum, and upper diaphragmatic surfaces.
- Parietal pleura is continuous with the visceral pleura over the root of the lungs.
- Pleura is mesothelium, and parietal pleura typically produces 1-2 L/day of serous fluid, which is normally resorbed by visceral lymphatics.
- The apex of the lung extends above the thoracic inlet, into the neck region, and lies in close contact with the dome of cervical pleura called the cupola.
- Consequently, the cupola and lung may be injured by wounds to the neck, producing a pneumothorax (air within the pleural cavity) or hemothorax (blood within the pleural cavity).
- The base of the lung rests on the dome-shaped surface of the diaphragm. The diaphragm is slightly higher on the right side due to the dome of the liver.
- The root of the lung connects the medial surface (hilum) of the lung to the trachea and heart. Each root contains the following:
  - A primary bronchus
  - A pulmonary artery carrying venous blood from the right ventricle

- Pulmonary veins (2) for returning oxygenated blood to the left atrium
- Bronchial arteries for supplying the lung parenchyma (airways) and visceral pleura
- Bronchopulmonary lymph nodes and lymphatic vessels
- Pulmonary nerve plexuses (these are autonomic nerve plexuses)
- Parasympathetic (vagal) fibers innervate airway smooth muscle (bronchoconstriction), bronchial glands, and capillaries (vasodilation); sympathetic fibers produce bronchodilation and vasoconstriction; visceral afferents (vagal and segmental) carry sensory activity from airway irritant and stretch receptors.
- The contents of each root of the lung are surrounded by a sleeve of pleura that hangs below the root as the pulmonary ligament.
- Each lung has three surfaces (costal, mediastinal, and diaphragmatic), and the lungs are divided into lobes by fissures.
- The left lung is divided into two lobes (superior and inferior) by the oblique fissure. The superior lobe has a “defect,” the cardiac notch (incisure) on its anterior border, due to the bulge of the heart.
- The right lung is divided into three lobes (superior, middle, and inferior) by the horizontal and oblique fissures.

## Trachea

- Runs from the lower border of cricoid cartilage of the larynx in the neck (~C6) to the T4 level, where it bifurcates into the mainstem bronchi.





F. Netter  
M.D.

Lungs in Situ

- ~20 C-shaped rings of hyaline cartilage surround the anterior and lateral tracheobronchial mucosa.
- Tracheal (respiratory) mucosa is pseudostratified columnar epithelium underlaid by a loose connective tissue, lamina propria.
- Trachealis smooth muscle joins the posterior parts of the cartilage rings (membranous trachea).
- Longitudinally running elastic fibers, blood and lymphatic vessels, nerves, and glands are embedded in the mucosa.
- Cartilaginous plates become complete circles just before bronchi enter the lungs, and the muscle layer becomes circular within the rings.
- Trachealis muscle is nonsphincteric, but bronchiolar muscle can occlude airways.

### Bronchi and Bronchopulmonary Segments of the Lungs

- Right and left primary or main bronchi form at the bifurcation of the trachea at the level of the sternal angle (or 4th thoracic vertebra).
- Right primary bronchus is wider, shorter, and more vertical than the left bronchus.
- Accidentally inhaled objects (pills, temporaries) may thus lodge more frequently in the right bronchus.
- Each main bronchus divides into secondary or lobar bronchi (two on the left and three on the right).
- Each lobar bronchus divides into tertiary or segmental bronchi, which supply specific parts of the lungs called the bronchopulmonary segments.

- Each bronchopulmonary segment has the following common characteristics:
  - It is a subdivision of a lung lobe.
  - It is pyramidal in shape with the apex toward the lung root.
  - It is surrounded by connective tissue.
  - It contains a segmental bronchus, segmental artery, lymphatics, and autonomic nerves.
  - A segmental vein lies in the connective tissue between adjacent bronchopulmonary segments.
  - A diseased segment, because it is a structural unit, can be removed surgically.
- The airway system progressively subdivides in a pattern mathematically described as fractal.
- Beyond the segmental bronchi, about 23-25 generations of airway subdivisions give rise to microscopic terminal bronchioles, which then give rise to successive generations of respiratory bronchioles, alveolar ducts, and, finally, alveolar sacs (alveoli).
- Bronchioles have no submucosal cartilage: airway dilation is maintained by elastic fibers extending into parenchyma.
- Bronchiolar mucosa is aglandular, transitioning from ciliated columnar to ciliated cuboidal as size decreases.
- Submucosal bronchiolar smooth muscle constricts with vagal (cholinergic) stimulation and dilates with sympathetic (adrenergic) stimulation.
- Alveolar ducts and sacs are lined with type I (squamous) cells interspersed with surfactant secreting type II (great alveolar) cells.

- Respiratory gas exchange takes place between alveolar ducts/sacs and pulmonary capillaries.

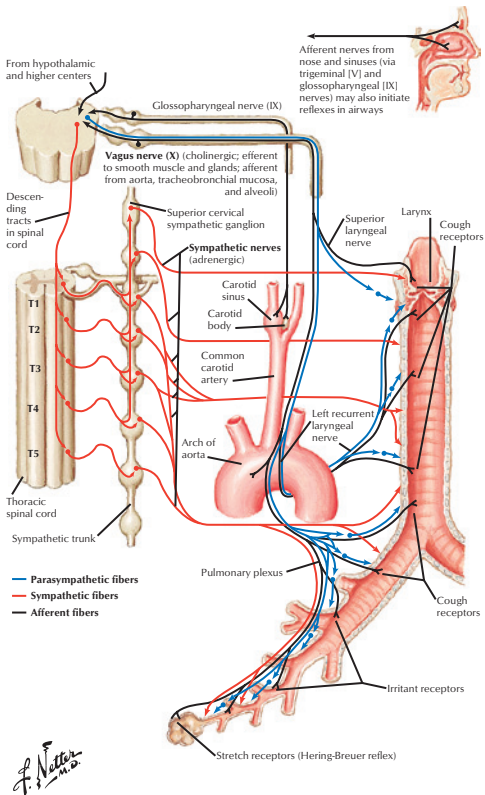
### Innervation

- Pulmonary nerve plexus (anterior and posterior to bronchi) is composed of vagal afferent and efferent, sympathetic efferent, and segmental afferent/sensory components that innervate the lower airways, lungs, and visceral pleurae.
- Parasympathetic preganglionic fibers
  - Upper (cervical) portion from the recurrent laryngeal nerve
  - Thoracic preganglionic portion from the vagus via the pulmonary plexus (peribronchial)
  - Ganglion cells located in pulmonary plexus
  - Motor to airway smooth muscle (constriction), glands (secretomotor), inhibitory to vascular smooth muscle (vasodilation)
- Sympathetic postganglionic fibers
  - Via nerves from cervical and thoracic chains
  - From cervical ganglia and thoracic ganglia
- Sensory fibers (visceral afferent)
  - Vagus: chemoreceptor, stretch, Hering-Breuer; vascular pressoreceptors; to vagal afferent ganglia
  - Segmental (parallel to sympathetics) with spinal nerves; to cervical and thoracic dorsal root ganglia; primarily nociceptive from visceral pleurae and bronchi

## VESSELS AND LYMPHATICS

### Pulmonary Arteries

- Pulmonary trunk bifurcates and directs right heart deoxygenated blood into right and left (main) pulmonary arteries.



Innervation of Tracheobronchial Tree: Schema

- Branches distribute segmentally with the bronchi, stay close to corresponding airways
- Give rise to progressively smaller branches (lobar, segmental, etc.) leading to the pulmonary capillaries that exchange gas with alveoli

### Pulmonary Veins

- Postcapillary venules empty into pulmonary vein tributaries, which drain intersegmentally.
- Deeper airways and tissue supplied by bronchial arteries drain into the pulmonary veins.

### Bronchial Arteries

- Branches of the thoracic aorta: bronchial arteries (proper), bronchial branches of intercostal and esophageal arteries
- Supply blood to the airways and the lung parenchyma

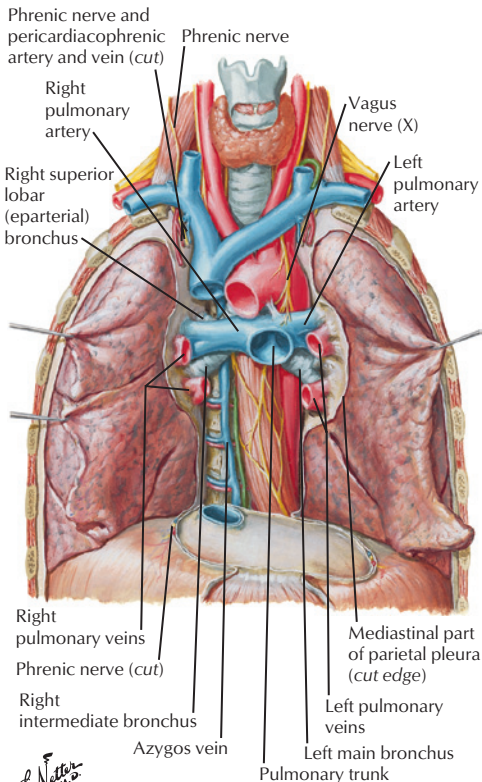
### Bronchial Veins

- Drain the airways, tissues, and pleura proximal to lung roots that are supplied by bronchial arteries
- Connect to the azygos/hemiazygos system

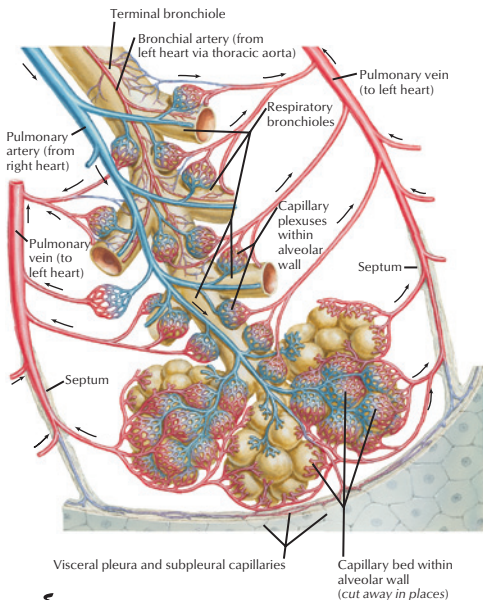
### Lymphatic Drainage

#### *Right Side*

- All lobes drain into pulmonary and bronchopulmonary (hilar) nodes
- Then into inferior tracheobronchial (carinal) nodes, right superior tracheobronchial nodes, and right paratracheal nodes
- Which drain via the bronchomediastinal lymphatic trunk or inferior deep cervical (scalene) node
- Then into the right brachiocephalic vein



Main Vessels of the Lungs and Mediastinum

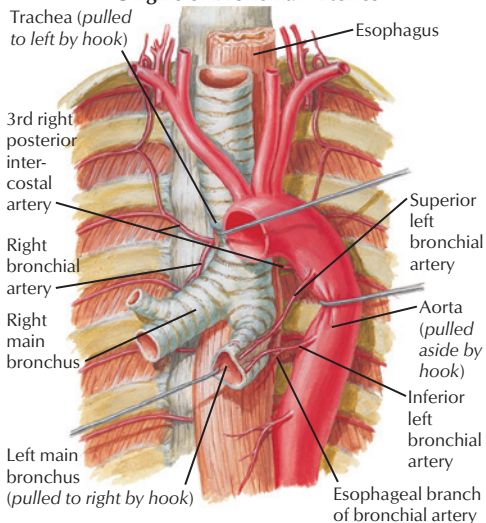


*F. Netter  
M.D.*

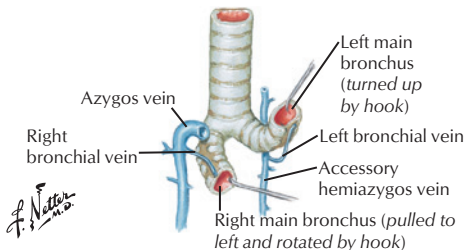
## Intrapulmonary Blood Circulation



## Origins of Bronchial Arteries



## Bronchial veins



## Bronchial Arteries and Veins

### *Left Side*

- Upper/superior lobe drains into pulmonary and bronchopulmonary (hilar) nodes
- Then into inferior tracheobronchial (carinal) nodes, left superior tracheobronchial nodes, and paratracheal nodes or node of the ligamentum arteriosum
- Which drain via the bronchomediastinal lymphatic trunk or inferior deep cervical (scalene) node
- Into the left brachycephalic vein
- Lower/inferior lobe drains into pulmonary and bronchopulmonary (hilar) nodes
- Then into inferior tracheobronchial (carinal) nodes
- Then crossing over to mostly right superior tracheobronchial and right paratracheal nodes
- Which drain via the bronchomediastinal lymphatic trunk or inferior deep cervical (scalene) node
- Into the right brachiocephalic vein

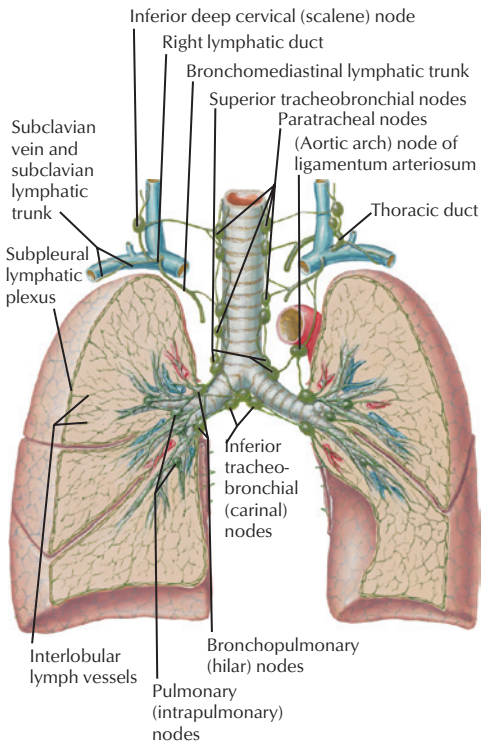
## **CLINICAL CORRELATES**

### **Pneumothorax**

- High risk professions for spontaneous pneumothorax: pilot, diver, mountain climber
- Ruptured blebs more common on right, in apex of upper lobe, in tall, thin individuals
- Recurrence risks: ~20% after first occurrence, ~60% after second, ~80% after third

### **Hemothorax**

- Common in both penetrating and nonpenetrating chest injuries

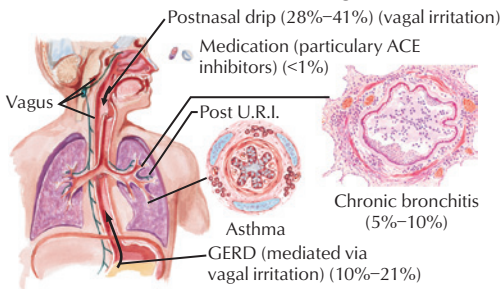


### Drainage routes

Lymph Vessels and Nodes of Lung Routes of Lymphatic Drainage of Lungs

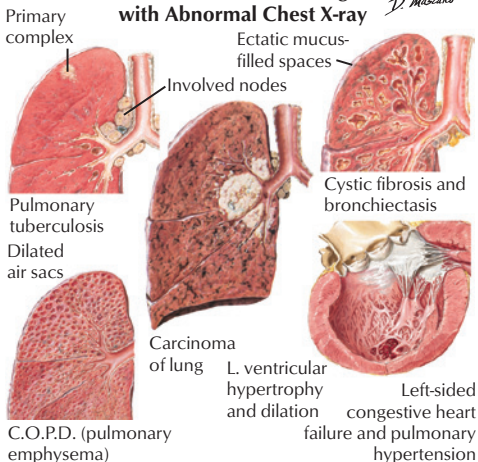
*F. S. Netter M.D.*

### Causes of Chronic Cough



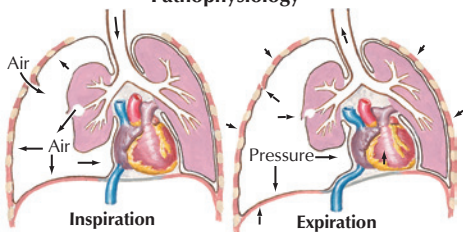
### Causes of Chronic Cough with Abnormal Chest X-ray

JOHN A. CRAIG, MD  
D. Mascaro



### Causes of Chronic Cough

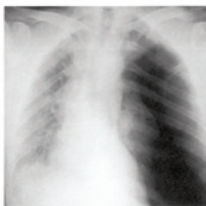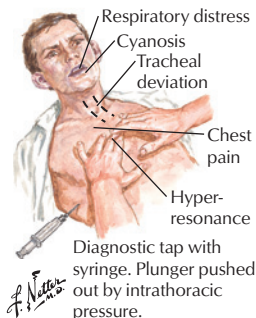
## Tension pneumothorax Pathophysiology



Air enters pleural cavity through lung wound or ruptured bleb (or occasionally via penetrating chest wound) with valvelike opening. Ipsilateral lung collapses and mediastinum shifts to opposite side, compressing lung.

Intrapleural pressure rises, closing valvelike opening, thus preventing escape of pleural air. Pressure is thus progressively increased with each breath. Mediastinal and tracheal shifts are augmented, diaphragm is depressed, and venous return is impaired.

### Clinical manifestations



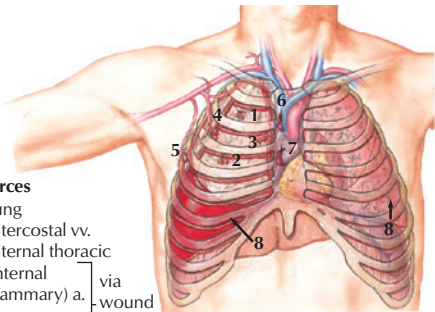
Left-sided tension pneumothorax. Lung collapsed, mediastinum and trachea deviated to opposite lung.

### Tension Pneumothorax

- Pleural spaces represent large potential volumes that may be filled with accumulating blood.
- Large hemothorax may cause hypovolemic shock and reduce vital capacity by lung compression.
- Blood in pleural spaces tends not to clot because of defibrinating action of respiratory movements and smooth pleural surfaces.
- Hemothorax is classified by degree (minimal, moderate, or massive) and source of bleed (lung versus thoracic vessels versus heart versus abdominal structures); see figure for details.
- Persistent hemothorax typically due to intercostal or internal thoracic (internal mammary) hemorrhage, less commonly to hilar bleeding
- Thoracentesis and chest tube (with underwater drainage) indicated for moderate or massive hemothorax
- Thoracotomy may be indicated to arrest bleeding

### Pulmonary Embolism

- Most common source veins: external iliac, femoral, deep femoral, popliteal, posterior tibial, soleal plexus
- Less common sources: right side of heart; veins—gonadal (ovarian or testicular), uterine, pelvic plexus, great saphenous, small saphenous
  - Frequently, no definitive source can be identified
  - Superficial thrombophlebitis associated with deep vein thrombosis occurs in <33% of cases

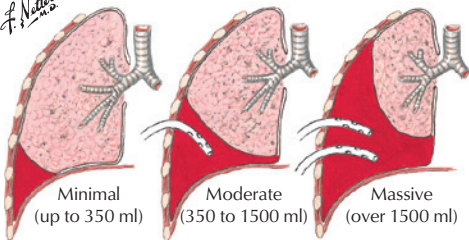


### Sources

1. Lung
  2. Intercostal vv.
  3. Internal thoracic (internal mammary) a.
  4. Thoracoacromial a.
  5. Lateral thoracic a.
  6. Mediastinal great vessels
  7. Heart
  8. Abdominal structures (liver, spleen) via diaphragm
- } via wound track

### Degrees and management

*F. Netter M.D.*



Blood usually resorbs spontaneously with conservative management. Thoracentesis rarely necessary.

Thoracentesis and tube drainage with underwater-seal drainage usually suffices.

Two drainage tubes inserted since one may clog, but immediate or early thoracotomy may be necessary to arrest bleeding.

### Hemothorax

- Signs of deep vein thrombosis may be difficult to detect in lower extremity until circulation extensively compromised.
- Pelvic veins may be suspected sources in complicated obstetric manipulations, pelvic inflammatory disease, or septic abortion with supportive thrombophlebitis.
- Venous stasis may be associated with thrombosis in a normal person, especially an elderly person, after prolonged knee flexion in auto or airplane rides.
- Other predisposing factors include prolonged bed rest, major abdominal surgery trauma, polycythemia with increased coagulability, and oral contraceptive use.
- Pulmonary embolization without infarction most common; clinical manifestations, subtle unexplained tachypnea, dyspnea, anxiety, vague substernal pressure, occasional syncope
- Massive embolus in main pulmonary artery or overriding both branches:
  - Is a dire emergency that elicits acute cor pulmonale and circulatory collapse
  - May be difficult to distinguish from an acute myocardial infarction
  - Chances of clinical recognition may depend on perceived disposition to embolization
  - Support for dx provided by S1-Q3 pattern in electrocardiogram, “P pulmonale” pattern, new right axis shift, or new incomplete right bundle branch block
- Pulmonary infarction secondary to embolization more common than massive embolization, but <10%



- Roentgenographic appearance of pulmonary embolization
  - Depends on size and number of emboli, presence of pulmonary infarction, and if present infarction reaches pleural surface, causing pleuritis and effusion
  - Massive embolus at major pulmonary artery branch origin causes ipsilateral hypoperfusion with decreased vascular markings.
  - Increase in major hilar vessel size or abrupt cutoff (“knuckle sign”) is supportive sign, if present.
  - Areas of lung may show unusually small vessels, if not distinctly oligemic.
  - Occasionally, only obvious sign may be pulmonary infiltrate, ipsilateral pleural effusion, or an unusually high hemidiaphragm on the affected side.
  - Pulmonary angiogram is the only definitive method of establishing large occlusion, but risk needs clinical justification.

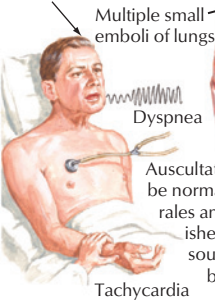
## Lung Cancer and Tumors

### *Bronchogenic Carcinoma*

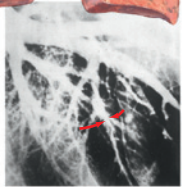
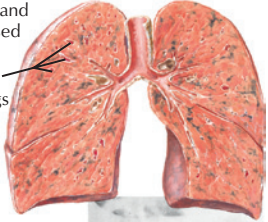
- ~95% of all lung carcinomas are bronchogenic carcinomas.
- Classification: % of all carcinomas, male versus female (M:F), location tendency (variable), smoking relation, growth rate, metastasis tendency, resectability
  - Epidermoid (squamous cell): ~50%; M:F = ~4:1; hilar; smoking relation great; relatively slow growth; late metastasis, then primarily to hilar nodes; fair resectability

### Embolism of lesser degree without infarction

Sudden onset of dyspnea and tachycardia in a predisposed individual is cardinal clue.

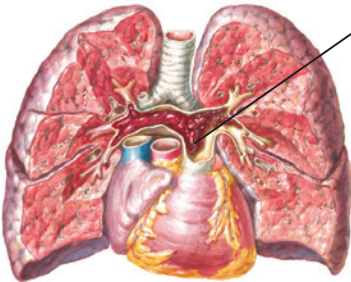


Multiple small emboli of lungs



Angiogram showing small emboli (arrows)

### Massive embolization



Saddle embolus completely occluding right pulmonary artery and partially obstructing main and left arteries

*F. Netter M.D.*

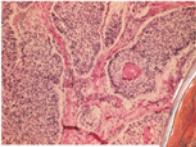
### Pulmonary Embolism

- Small cell anaplastic (oat cell): ~30%; M:F = ~3:1; hilar, but metastasis often present at discovery; smoking relation great; very rapid; very early, to mediastinum or distally; unresectable
- Adenocarcinoma: ~14%; M:F = ~1.3:1; peripheral (usually <4 cm); little smoking relation; intermediate growth rate; intermediate metastasis rate; poor resectability
- Large cell anaplastic: ~8%; M:F = ~3:1; variable location, peripheral or central; smoking relation great; rapid growth; early metastasis; poor resectability
- Paraneoplastic syndromes (secretory): squamous cell—parathormone (PTH); small cell—antidiuretic hormone (ADH) and adrenocorticotrophic hormone (ACTH); small cell—ACTH most common (atypical Cushing syndrome with facial edema and cachexia); gonadotropin effects may be seen with small cell, squamous, or adenocarcinoma tumors

### *Pancoast Syndrome*

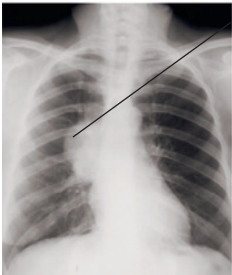
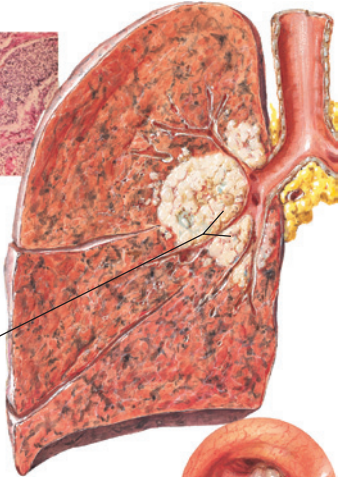
- Uncommon superior mediastinal presentation of bronchogenic carcinoma
- Chest wall and subpleural lymphatics invaded
- Posteriorly, tumor may spread through contact to the sympathetic chain and stellate ganglion, with loss of sympathetic tone and appearance of Horner syndrome: meiosis, ptosis, flushing, anhydria, enophthalmos on affected side of face.
- Growing tumors can involve vertebrae and upper ribs, with the latter leading to intractable shoulder pain.

### Bronchogenic carcinoma: epidermoid (squamous cell) type

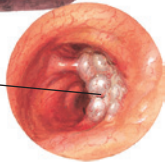


Nests of tumor cells separated by fibrous bands

Tumor typically located near hilus, projecting into bronchi



Tumor



Bronchoscopic view

*F. Netter M.D.*

Bronchogenic Carcinoma

- May compress subclavian vessels, producing upper limb paresthesias.
- Upper limb paresthesias (in C8-T1 ulnar distribution) may result from invasion of lower trunk of brachial plexus.

### *Superior Vena Cava (SVC) Syndrome*

- Bronchogenic carcinoma (especially small cell) occasionally compromises blood return through the SVC via compression or tumor invasion.
- Patient complaints: feeling of fullness in head and neck, blurring of vision, headache, dyspnea (especially recumbent)
- Physical signs: rubor and edema of head and neck (especially eyelids), facial plethora, prominence of superficial veins of upper body; veins remain distended when limb raised

### *Mesothelioma*

- Most malignant lung tumor, with local and nodal invasion and metastases often present at discovery
- History of asbestos exposure common

### *Bronchial Adenomas*

- Malignant tumors: mucoepidermoid, mucous gland, adenoid cystic; slow growing, no metastases; Tx—resection
- Adenoid cystic adenoma: from submucosal glands; perineural lymphatic spread beyond lumen; slow growing; Tx—resection (~10-year survival if incomplete); x-ray therapy can provide good palliation if no resection

### *Hamartomas*

- Generally benign (75% of all benign lung tumors), usually formed of connective tissue (cartilage,

fat, etc.); most form in connective tissue outside of lungs, although ~10% in bronchial lining; more common in men; popcorn-like appearance on radiography; if Tx, resection

### *Other Benign Tumors*

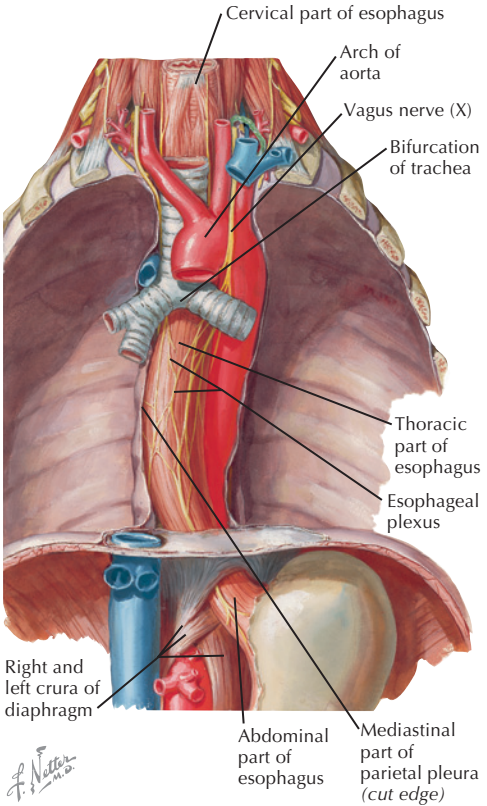
- Fibroma: peripherally located interlacing mass of collagen and fibroblasts
- Chondroma: composed almost entirely of cartilage, covered with bronchial epithelium; rare; small, endobronchial; large, parenchymal
- Others: endobronchial lipomas (rare); leiomyomas (smooth muscle + fibrous connective tissue), single or diffuse nodules throughout tracheobronchial tree; benign mesotheliomas; vascular—hemangiomas, endotheliomas, fistulae (very rare)

# 7

## Esophageal Diseases

### **ANATOMY OF THE ESOPHAGUS**

- Fibromuscular tube (~25 cm) running from the pharynx in the neck, through the thorax and diaphragm, to the stomach in the abdomen
- Runs just posterior to the trachea and anterior to vertebral bodies in the neck and superior mediastinum
- Runs just posterior to the heart (left atrium and left ventricle) in the posterior mediastinum
- Tends to run to the left below T4 but is pushed to the center by the arch of the aorta and the root of the left lung
- Esophageal hiatus of the diaphragm is to the left of midline, at the level of the T10 vertebra.
- Upper esophageal sphincter: circular muscle of the superior esophagus, including the cricopharyngeus, the first region of anatomical constriction
- Also compressed in its course by 3 structures, as seen on barium swallow (when expanded)
  - Arch of the aorta
  - Left main bronchus
  - Diaphragm: passes between the superior fibers of the right crus
- Ends at the cardiac orifice of the stomach, left of midline
- Retropharyngeal danger space: possibility of infection spreading retroesophageally into the thorax



Esophagus in Situ



## Microscopic Anatomy

### *Mucosa*

- Highly folded stratified squamous epithelium, with walls in apposition unless distended by swallowing
- Mucous glands more numerous inferiorly

### *Tunica Muscularis*

- Inner circular: continuous superiorly with the circumferential fibers of the inferior pharyngeal constrictor
- Outer longitudinal
  - Upper third is striated (voluntary muscle) like the pharynx.
  - Middle third is a combination of striated and smooth muscle.
  - Lowest third is smooth muscle.

### *Tunica Adventitia*

- Fibrous, not serous
- Has embedded arterial, venous, and nerve plexuses

## Innervation

- The esophageal nerve plexus is composed of vagal afferent and efferent, sympathetic efferent, and segmental sensory components.
- Parasympathetic preganglionic fibers
  - Upper (cervical) portion from the recurrent laryngeal nerve
  - Thoracic portion from the vagus via the pulmonary plexus (peribronchial)
  - Ganglion cells located in myenteric plexuses

**Anterior view**

Esophagus

Recurrent laryngeal nerves

Superior cervical sympathetic ganglion

Vagus nerve

Branch to esophagus and recurrent nerve from stellate ganglion

Cervicothoracic (stellate) ganglion

Esophageal plexus (anterior portion)

Branches to esophageal plexus from sympathetic trunk, greater thoracic splanchnic nerve, and thoracic aortic plexus

**Posterior view**

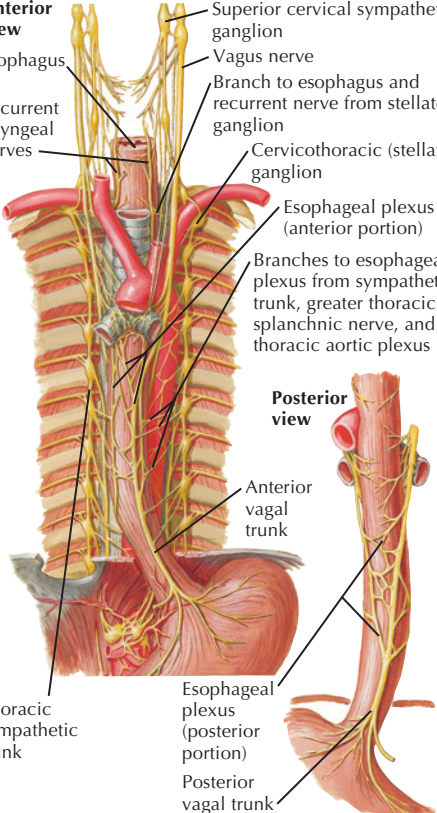
Anterior vagal trunk

Thoracic sympathetic trunk

Esophageal plexus (posterior portion)

Posterior vagal trunk

Nerves of Esophagus



- Sympathetic postganglionic fibers
  - Via nerves from cervical and thoracic chains
  - From cervical ganglia and thoracic ganglia
- Sensory fibers (visceral afferent)
  - Vagus: stretch, chemoreceptor, nociceptor; to vagal ganglia
  - Segmental (parallel to sympathetics) with spinal nerves; to cervical and thoracic dorsal root ganglia

## **VESSELS AND LYMPHATICS**

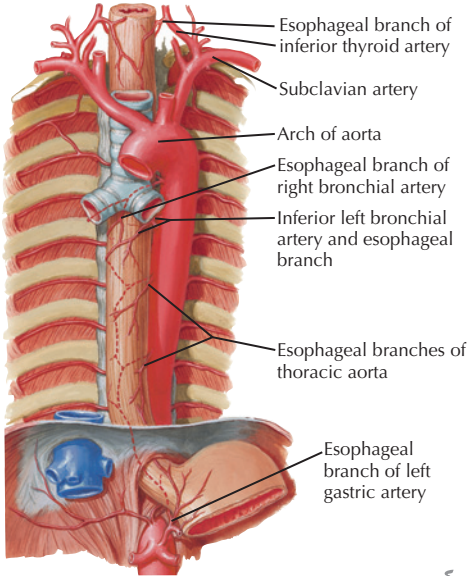
- Extensive submucosal vascular plexuses allow mobilization of large extents of the esophagus with reduced risk of ischemia.

### **Arterial Supply**

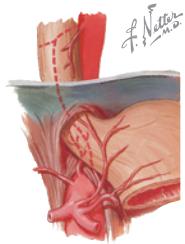
- Cervical portion is supplied by branches of the inferior thyroid arteries from thyrocervical trunks of the right and left subclavian arteries.
- Thoracic branches (unpaired) from the adjacent aorta
- Abdominal portion supplied by branches of the celiac (left gastric) and left inferior phrenic arteries

### **Venous Drainage**

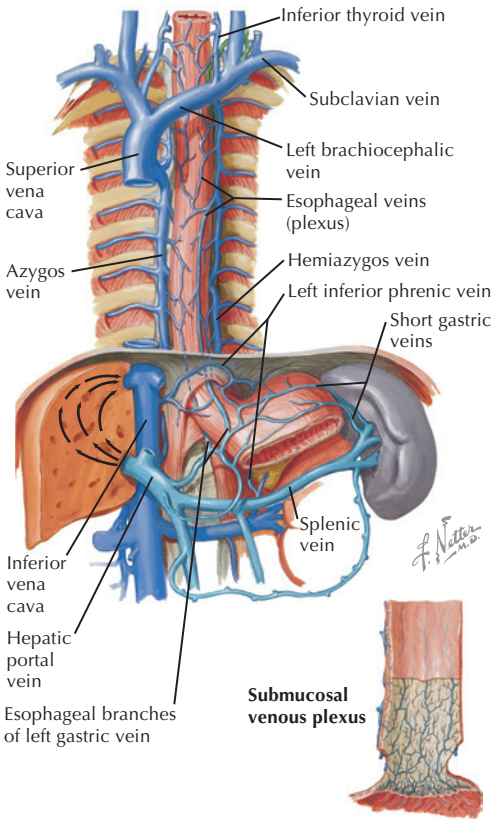
- Esophageal venous plexus has multiple connections.
  - Right and left azygos venous channels, segmental body wall drainage (into superior vena cava); includes hemiazygos and accessory hemiazygos on left
  - Inferior thyroid veins into subclavian veins (and superior vena cava)



Common variations: Esophageal branches may originate from left inferior phrenic artery and/or directly from celiac trunk. Branches to abdominal esophagus may also come from splenic or short gastric arteries.



### Arteries of Esophagus



Veins of Esophagus

- Inferiorly into the portal vein (directly), splenic vein, and superior gastric venous plexus
- Because of portal and systemic (azygos, etc.) connections of the submucosal veins, they can become enlarged (varices) in portal hypertension.
- Risk of rupture of varices and esophageal hemorrhage with alcoholic cirrhosis
- Venous plexus can also be distended in caval obstruction, by venous return shunted through azygos system.

### Lymphatic Drainage

- Parallels the arterial supply
- Upper portions drain into paratracheal and inferior deep cervical nodes.
- Abdominal drainage is into left gastric lymph nodes, then into celiac nodes.
- Extensive submucosal lymphatic channels allow metastatic cells ready access to the deeper drainage.

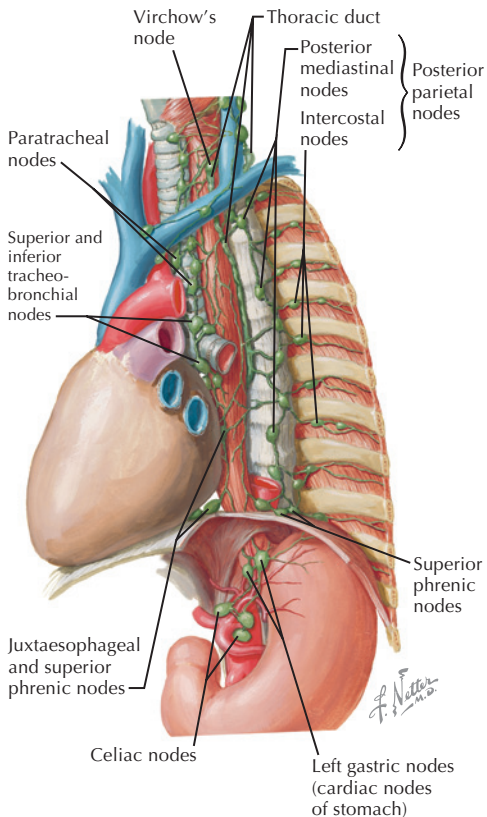
## CLINICAL CORRELATES

### Surgical Approaches to the Esophagus

- Cervical: left sided preferred, because esophagus runs slightly to the left of the trachea
- Upper (1/3) thoracic: right, avoids aorta
- Lower (2/3) thoracic: left, because esophagus here typically lies to the left of midline

### Zenker's Diverticulum

- False (posterior) diverticulum
- Occurs between the cricopharyngeus and the rest of the inferior constrictor
- Caused by increased swallowing pressure



Lymph Vessels and Nodes of Esophagus

- Symptoms: upper esophageal dysphagia, halitosis, choking
- Treatment: cricopharyngeal myotomy, resected or suspended (without removal of diverticulum) via left cervical incision

### Traction Diverticulum

- True diverticulum, typically lateral
- Caused by granulomatous disease, chronic inflammation, or tumor
- Typically in mid-esophagus

### Achalasia

- Failure of peristalsis and lack of lower esophageal sphincter relaxation with swallowing
- Secondary to neuronal degeneration in muscular layers
- Can lead to dilated esophagus and diverticula (epiphrenic)
- *Trypanosoma cruzi* can produce similar symptoms
- Treatment: calcium channel blocker, nitrates, and sphincter dilation; surgery with failure
- Surgical treatment: left thoracotomy with Heller myotomy (upper and lower circular muscle transection)

### Gastroesophageal Reflux Disease (GERD)

- Failure of normal anatomical mechanisms: lower sphincter competence, normal esophageal structure, normal gastric reservoir
- Symptoms: heartburn 30-60 min. after meals, worse lying down, can have cough, asthma, choking
- Pharmacologic therapy first: omeprazole



# Complications of peptic reflux (esophagitis and stricture)

Peptic esophagitis      Peptic stricture  
Endoscopic views

Inflammation of esophageal wall  
Esophagitis and ulceration

Chronic inflammation may result in esophageal stricture and shortening

Stricture

Barium study shows peptic stricture

JOHN A. CRAIG M.D.

## Gastroesophageal Reflux Disease

- Surgical indications: failure of medical treatment, GERD with pH monitoring, complications including stricture, Barrett's esophagus, cancer
- Surgical treatment: Nissen fundoplication
- Most patients with significant reflux have type I hiatal hernia (see next).

### Hiatal Hernia (see [Chapter 12, p. 143](#))

- Type I
  - Dilation of hiatus with sliding hernia
  - Most common
  - May be associated with GERD, although most type I patients do *not* reflux
- Type II
  - Paraesophageal, hole in diaphragm next to the esophagus
  - Symptoms: dysphagia, chest pain, early satiety
- Type III: combined
- Type IV
  - Entire stomach in thorax
  - Other organ such as spleen or colon may be included.

### Esophageal Cancer

- Adenocarcinoma, typically found distally, is now more common in the U.S.
- Squamous cell carcinoma can be found anywhere in esophagus and is more common worldwide.
- Diet is implicated as a causative factor in developing countries.
- Tobacco and alcohol are prominent risk factors in the Western world.
- Adenocarcinoma may be seen in patients with long-standing GERD.

- Barrett's esophagus (BE) is metaplastic replacement of normal squamous mucosa by specialized intestinal epithelium.
  - A high-risk precursor to adenocarcinoma
  - Requires biopsy and monitoring
- Symptoms: dysphagia (primary), weight loss, dyspnea, hoarseness, chest pain (especially in advanced disease)

### Leiomyoma

- Most common benign tumor of the esophagus
- Submucosal, hyperproliferating smooth muscle with connective tissue capsule
- Radiographic and endoscopic study
- Biopsy contraindicated owing to risk of scarring
- Symptoms: dysphagia and lower esophageal pain

### Esophageal Polyps

- Second most common type of benign tumor
- Usually in cervical region
- Symptoms: dysphagia and hematemesis

### Perforations

- Spontaneous: Boerhaave's syndrome, associated with forceful prolonged retching and extended vomiting
- Traumatic: blunt or penetrating
- Iatrogenic: associated with endoscopic and surgical procedures

### Caustic Injury

- Stricture and death can follow severe injuries.
- Survivors tend to develop long strictures.
- Primary treatment for strictures: esophageal dilation (risk of perforation)

*Degrees of Chemical (or Caustic) Injury*

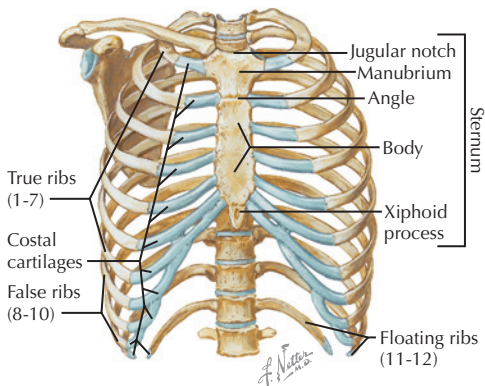
- Primary burn: hyperemia
  - Treatment: conservative therapy and observation
  - IV fluids, antibiotics, spitting
  - Can lead to strictures, cervical or near aortic impression, or shortening
- Secondary burn: ulcerations, exudates, sloughing
  - Treatment: conservative therapy and observation
  - Surgery on indications: sepsis, peritonitis, mediastinitis, free or mediastinal air, pneumothorax, crepitance, contrast extravasation, air in stomach walls
- Tertiary burn: charring, deep ulcers, lumen narrowing
  - Treatment: conservative therapy and observation, esophagectomy typically needed
  - Surgery on indications: sepsis, peritonitis, mediastinitis, free or mediastinal air, pneumothorax, crepitance, contrast extravasation, air in stomach wall
- Acid: causes coagulation necrosis and gastric injury
- Alkali (e.g., drain cleaner): causes deep necrosis with liquefaction, worse than acid

# 8 Ribs and Thorax Fractures

## ANATOMY OF THE RIBS AND THORAX

### Ribs

- Mature rib: largely cancellous bone, light, easily fractured
- Cortical bone can fracture into sharp spicules, damaging pleura, lungs, and neurovasculature.
- Parts and landmarks: head, neck, tubercle, angle, shaft/body, notch, costal cartilage
- Ribs are overlaid and protected superiorly by pectoral girdle bones and muscles: pectoralis major and minor, subclavius, serratus anterior, scapula, rhomboids, and trapezius.
- Intercostal muscles span the intervals between successive ribs, from T1-T12: external, internal, and innermost layers.
- Intercostal neurovascular bundles lie between internal and innermost intercostal muscles.
  - Superior (large) lie along the lower borders of ribs, within costal notches.
  - Inferior (small, variable) lie just above the lower rib of each intercostal space.
- Proximal articulations are synovial.
  - Costovertebral joints: articular facets of heads of ribs with hemifacets on bodies of *successive* vertebrae

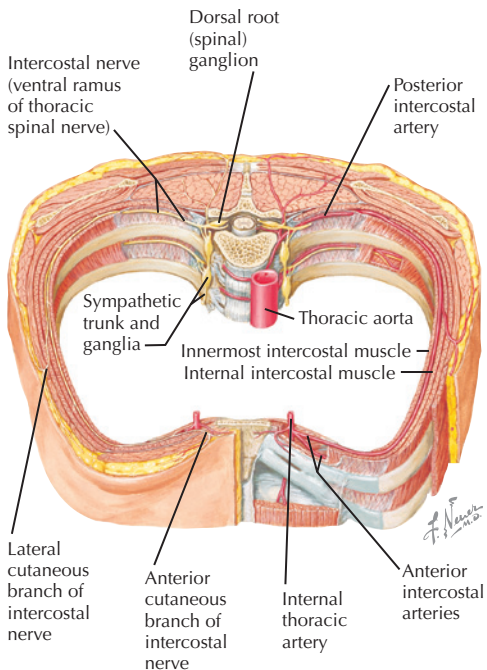


### Thoracic Skeleton

- Costovertebral joints: between articular tubercles of ribs and transverse processes of related vertebrae
- First sternocostal (distal rib) joint: fibrous
- Sternocostal joints T2-T7: synovial
- Costochondral joints: costal cartilages of T8-T10 (false ribs) attach to T7 cartilage
- T11 and T12 floating ribs with no distal joints
- Free movement of most rib joints needed for unrestricted ventilation in normal thorax

### Sternum

- Formed from sternabrae (multiple ossification centers) during development: gaps can persist
- Manubrium: articulations with clavicles, jugular (suprasternal) notch



Thoracic Wall: Intercostal Nerves and Vessels

- Body: lateral articular recesses for synovial, sternocostal joints
- Xiphoid process: may be bifid, notched, perforated
- Manubriosternal joint: symphysis (secondary cartilaginous), between manubrium and body (sternal angle of Louis); site of rib 2 articulations
- Xiphisternal joint: synchondrosis (primary cartilaginous) between body and xiphoid process

## NEUROVASCULAR SUPPLY

- Intercostal neurovascular bundles usually run in the intercostal space in top-down order: vein, artery, nerve (VAN).

### Intercostal Nerves

- Anterior primary rami of spinal nerves
- Run with vessels in intercostal spaces below numbered ribs, between internal and innermost intercostal muscles
- Divide proximally into superior and inferior trunks, running in costal angle and above next rib, respectively
- Provide innervation for the layers of intercostal muscles as well as parietal pleura, dermis, and epidermis (with cutaneous sensation in overlapping strips corresponding with spinal segment dermatomes)

### Arterial Supply

- Intercostal arteries have anatomical connections with
  - Thoracic aorta
    - ▲ Posterior, bilateral, segmental posterior intercostal arteries, T1-T11 levels
    - ▲ Subcostal arteries, T12



- Aortic arch → subclavian → internal thoracic (mammary) arteries
  - ▲ Anterior intercostal arteries, T1-T6 levels
  - ▲ Intercostal branches of musculophrenic arteries below T6

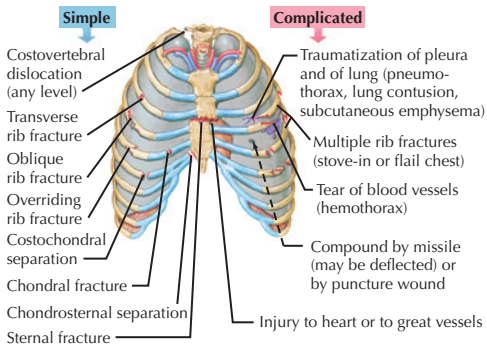
## Venous Drainage

- Intercostal veins parallel intercostal arteries.
- Anterior drainage into internal thoracic (mammary) veins → subclavian veins → brachiocephalic veins → superior vena cava
- Posterior drainage into azygos, hemiazygos, accessory hemiazygos, right and left superior intercostal veins (upper few segments)
- Azygos system drains into superior vena cava and connects with ascending lumbar veins, which connect with inferior vena cava; bypass pathway in caval obstruction

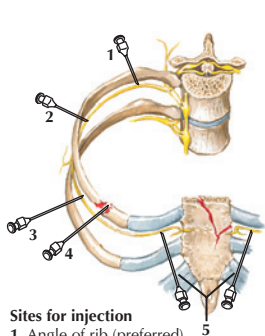
## CLINICAL CORRELATES

### Fractures in Thoracic Injuries

- Rib fracture types: oblique, transverse, overriding, costochondral separation, compound by penetration, multiple
- Complications
  - Trauma to costal pleura, visceral pleura, lung, intercostal vessels
  - Pneumothorax
  - Hemothorax
  - Spleen rupture (left posterior inferior)
  - Subcutaneous emphysema
- Rib fractures may be accompanied by sternal fractures.
- Subclavian arteries and veins pass above T1 ribs anterolaterally (trauma risk).

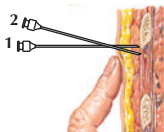


### Intercostal nerve block to relieve pain of fractured ribs



#### Sites for injection

1. Angle of rib (preferred)
2. Posterior axillary line
3. Anterior axillary line
4. Infiltration of fracture site
5. Parasternal



Needle introduced to contact lower border of rib (1), withdrawn slightly, directed caudad, advanced 1/8 in. to slip under rib and enter intercostal space (2). To avoid pneumothorax, aspirate before injecting anesthetic.

*F. J. Natter*  
M.D.

## Thoracic Cage Injuries and Anesthesia

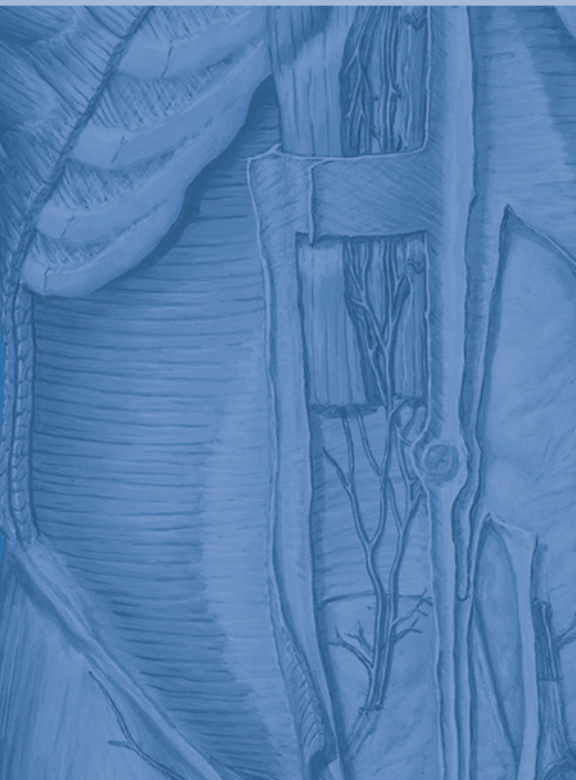
- Flail chest (life threatening)
  - Detached area of chest wall produced by fractures of 2 or more adjacent ribs in 2 places each
  - Paradoxical motion: affected segment moving inward on inspiration instead of expanding with undamaged thorax
  - About 50% mortality rate with flail chest, respiratory failure frequently due to associated pulmonary contusion
- Children's ribs
  - Extremely pliable, may be fractured by relatively low force
  - Underlying lung may be contused with few external signs of trauma.

### Intercostal Nerve Block

- To relieve pain of rib fracture
- Anesthetic infiltration sites
  - Preferred site dorsal, at angle of rib
  - Posterior axillary line
  - Anterior axillary line
  - Fracture site
  - Parasternal site
- Aspirate before injecting to prevent pneumothorax.

This page intentionally left blank

# Abdomen



This page intentionally left blank

# 9

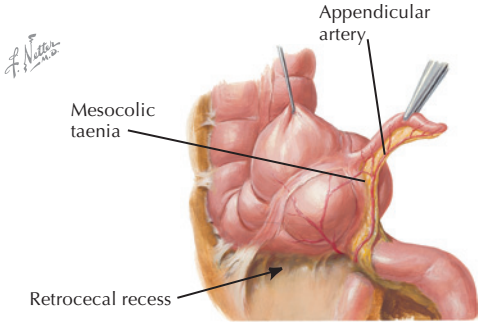
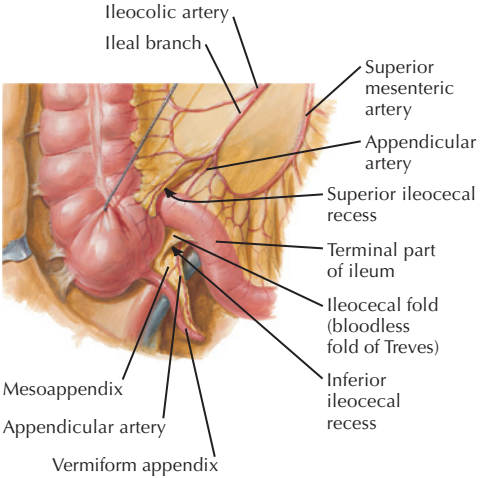
## Appendix Diseases

### ANATOMY OF THE APPENDIX

- Appendix develops as a diverticulum of the cecum (cecal bud) in embryonic week 8, as part of caudal midgut.
- Appendix is variable in length (2-20 cm) and may become inflamed and enlarged owing to fecal impaction and/or infection (appendicitis).
- Small mesentery (mesoappendix) connects with terminal ileum and contains appendiceal blood vessels and lymphatics.
- Tissue layers include mucosa, lamina propria, inner circular and outer longitudinal smooth muscle, and adventitia (peritoneum and mesentery).
- Low mucosa contains numerous goblet cells, intestinal glands, and crypts of Lieberkühn.
- Taeniae coli (triple longitudinal muscle bands of the cecum) merge into a single, outer longitudinal muscle layer on appendix.
- Lamina propria contains masses of lymphoid nodules with germinal centers.

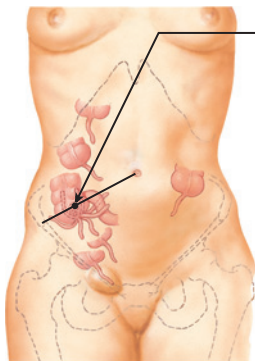
### Location and Position of Appendix

- Typical locations: retrocecal-retrocolic, pelvic (descending), subcecal, ileocecal (anterior to ileum), ileocecal (posterior to cecum)
- Variable by time and between individuals
- Can depend on size of mesoappendix

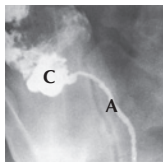


Ileocecal Region and Appendix



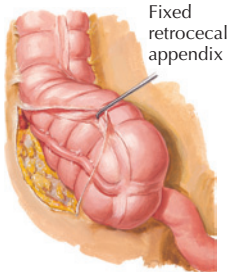


McBurney's point (on spinoumbilical line)



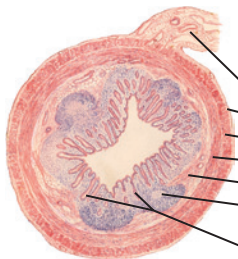
Barium radiograph of unusually long appendix (A, Appendix; C, Cecum)

**Variations in position of appendix**



Fixed retrocecal appendix

*F. Netter M.D.*



Mesoappendix  
 Serosa (visceral peritoneum)  
 Longitudinal muscle  
 Circular muscle  
 Submucosa  
 Aggregate lymphoid nodules  
 Crypts of Lieberkühn

**Vermiform Appendix**

- May be displaced into pelvis in pregnancy, with attendant differences in symptoms

## Mesentery and Folds

### *Mesoappendix*

- Runs from the posterior leaf of the mesentery of the terminal ileum
- Runs posterior to the terminal ileum and is often attached to it
- Attaches to left side of cecum and to the entire length of the appendix
- Triangular
- Contains appendicular artery (branch of ileocolic) and its variants

### *Ileocolic or Superior Ileocecal Fold*

- In the terminal ileal mesentery
- Contains anterior cecal artery
- Forms anterior wall of ileocolic or superior ileocecal fossa
- Overlies terminal ileum to posterior wall of fossa

### *Ileocecal or Inferior Ileocecal Fold*

- Anterior to mesoappendix
- Extends from right and anterior terminal ileum
- Forms anterior wall of ileocecal or inferior ileocecal fossa
- Mesoappendix: posterior wall of fossa
- Contains no vessels: “bloodless” fold of Treves

## **VESSELS AND LYMPHATICS**

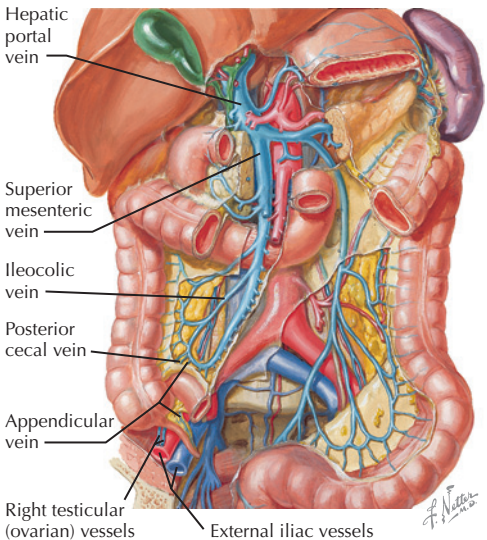
### Appendicular (Appendiceal) Artery

- Branch of the ileocolic artery or of the ileal or colic branch of the ileocolic (branches from the superior mesenteric artery)

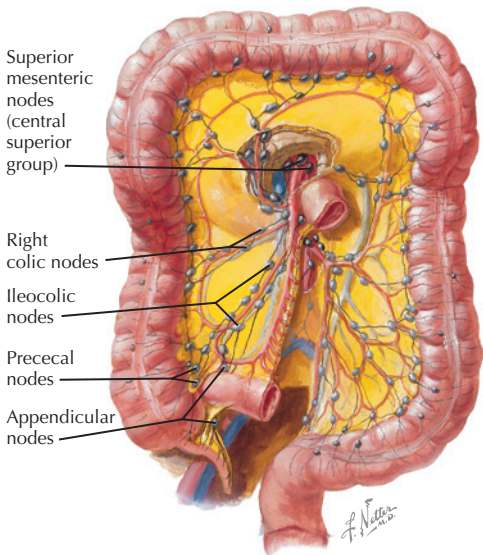
- Base of the appendix may be supplied by the anterior or posterior cecal artery.
- Appendiceal artery typically passes behind the terminal ileum, within the mesoappendix.

### Appendicular (Appendiceal) Vein

- Joins ileocolic vein, which joins superior mesenteric vein (portal vein drainage)



Veins of Large Intestine



Lymph Drainage of Large Intestine

### Lymphatics

- Local drainage of nodes within mesoappendix through vessels and nodes along appendiceal and ileocolic arteries
- Draining toward superior mesenteric lymph nodes

## CLINICAL CORRELATES

- Appendicitis is considered primarily a disease of adolescents and young adults.
- Rare in infants
- Lifetime risk for Western populations is ~7%; incidence varies with age.

### Etiology (Most Common)

- Children: hyperplasia, can follow infection
- Adults: fecalith

### Symptoms (Classic Presentation)

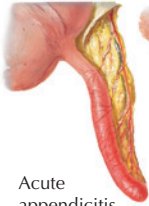- Anorexia, periumbilical pain, vomiting
- Locus of pain shifts to right lower quadrant with onset of peritonitis.

### Differential Diagnosis

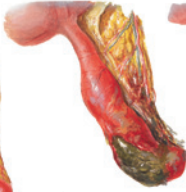
- Differential diagnosis for appendicitis is extensive.
- Other conditions to be ruled out: other gastrointestinal, gynecologic, urologic, neoplastic diseases.

### Appendicitis during Pregnancy

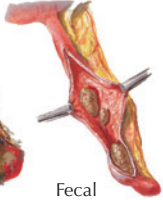- Most common cause of first-trimester acute abdominal pain
- More likely to occur in second trimester, but *not* the most common cause of acute pain
- More likely to perforate in third trimester (confused with contraction pain)
- Right upper quadrant pain can occur in third trimester.
- Fetus can die with rupture (35%).



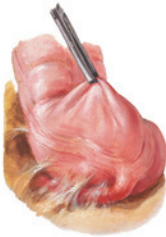Acute appendicitis



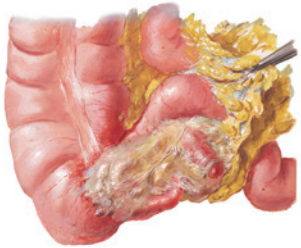
Gangrenous appendicitis



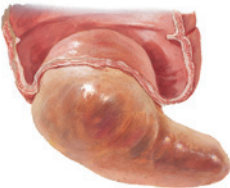Fecal concretions in inflamed appendix



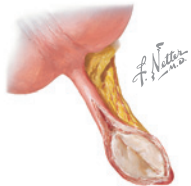Inflamed retrocecal appendix with adhesions



Appendiceal abscess



Mucocele of appendix



Carcinoid of appendix

Diseases of the Appendix

## Prophylaxis

- Suspected, but uninflamed appendix may be removed during laparotomy for a ruptured ovarian cyst, thrombosed ovarian vein, or regional enteritis (non-cecal).

## Clinical Signs and Landmarks

- McBurney's point: surface projection on abdomen of appendix attachment to cecum; 1/3 of the way along line from right anterior superior iliac spine to umbilicus; near anterior cutaneous branch of iliohypogastric nerve
- McBurney's sign: deep tenderness at McBurney's point
- Aaron's sign: rebound pain with applied pressure
- Most common site of appendicular perforation: midpoint of antimesenteric border

## CT Signs of Appendicitis

- Diameter  $>7$  mm or wall thickness  $>2$  mm
- Bull's eye appearance

## Surgical Appendectomy

- Gold standard remains exploratory laparotomy and appendectomy
- McBurney approach: oblique incision divides external oblique fascia parallel to its fibers
- Rocky-Davis incision: right lower quadrant transverse incision may be preferred in specific instances

## Carcinoid of the Appendix

- Most common site for carcinoid tumor (~50%)
- Ileum and rectum next most common sites

This page intentionally left blank



## ANATOMY OF THE EXTRAHEPATIC BILIARY SYSTEM

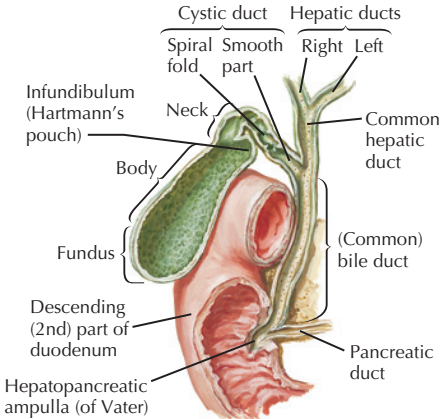
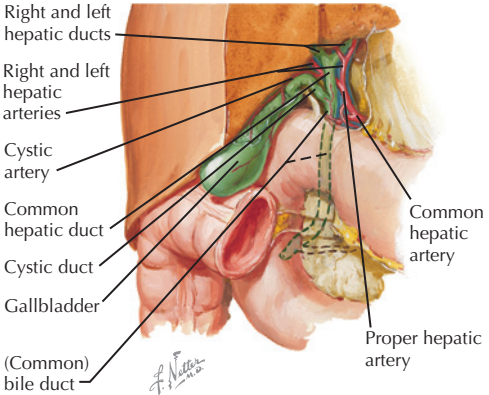
- Anatomy of the biliary system is highly *variable*, and this includes ducts, arteries, veins, and lymphatics.

### Common Hepatic Duct

- Intrahepatic biliary duct systems converge on right and left hepatic ducts.
- Right and left hepatic ducts typically form the common hepatic duct.
- Left duct is usually longer.
- Junction of the ducts may be intrahepatic (e.g., in hepatomegaly).
- Accessory hepatic ducts can occur.
- There may be no common hepatic duct if the cystic duct empties into right and left hepatic duct junction (bile duct branch variant).

### Gallbladder

- Normally lies between hepatic segments IV and V, in a ventral fossa between the anatomical right and left lobes
- Ventral surface typically lies in contact with the descending part of the duodenum.



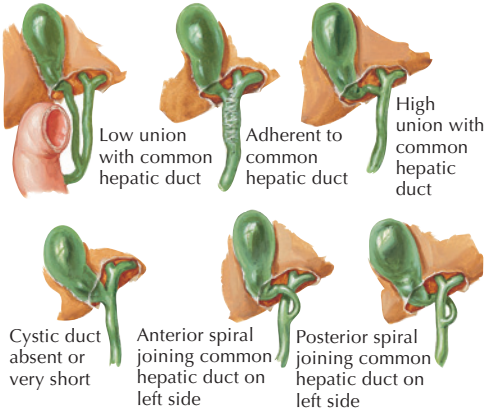
Viscera: Gallbladder and Extrahepatic Ducts

- Peritoneum surrounds fundus and attaches body and neck to the ventral surface of the liver.
- Hepatic surface of the gallbladder has fibrous tissue connections to liver capsule.
- Mucosa
  - Columnar epithelium, no submucosa
  - Actively absorbs  $\text{Na}^+$  and water, concentrating bile
- Smooth muscle of the fibromuscular layer is primarily oriented longitudinally.
- Parasympathetic preganglionic innervation from left (anterior) vagus fibers contracts gallbladder and relaxes bile duct sphincter.
- Postganglionic sympathetic fibers from the celiac ganglion are driven by preganglionic fibers from T7-T10 spinal segments traveling in greater splanchnic nerves.
- Visceral afferent fibers (e.g., pain) travel back toward thoracic spinal ganglia, through the celiac plexus and greater splanchnic nerve, alongside incoming sympathetics.

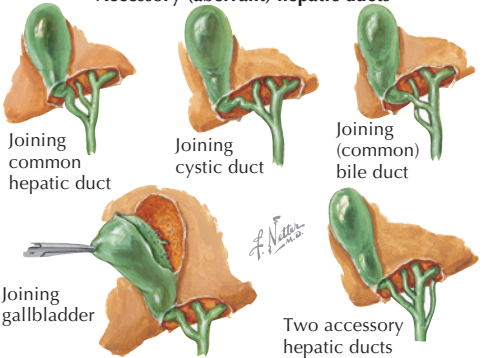
### Cystic Duct

- Proximal portion is convoluted; spiral fold keeps the duct open.
- Distal portion is smooth.
- Typical cystic duct joins the common hepatic duct well below the right and left hepatic duct junction.
- Triangle of Calot: classic configuration (shown above) with cystic duct right, common bile duct left, liver above, and right hepatic artery passing through

Variations in cystic duct



Accessory (aberrant) hepatic ducts



Variations in Cystic and Hepatic Ducts

## Cystohepatic Junction

- Classic normal
  - High, subhepatic origin of the common hepatic duct
  - Joined inferiorly, at an angle from the right, by the cystic duct (<3 cm)
  - Produces the (common) bile duct some distance above the descending duodenum
- Variations
  - Short or absent cystic duct
  - Cystic duct parallel to hepatic duct
  - Insertion into right hepatic duct
  - Low insertion of cystic duct, crossing anterior to common hepatic duct, inserting behind the duodenum
  - Low medial insertion of (anterior crossing) cystic duct into bile duct
  - Low anterior insertion of (posterior crossing) cystic duct into bile duct
- Anatomical types of cystohepatic junction: angular, parallel, spiral

## Ducts of Luschka

- Small biliary ducts that connect directly from liver to the gallbladder
- Potential source of leakage following cholecystectomy

## (Common) Bile Duct

- Formed by the union of hepatic and cystic ducts
- Portions: supraduodenal, retroduodenal, pancreatic, intraduodenal
- Bile duct sphincter: smooth muscle surrounding the distal end of the duct, part of the complex sphincter of Oddi

### Dimensions

- 4-8 mm diameter normal undilated
- Diameter tends to increase with advanced age.
- Heuristic: normal duct diameter in mm = age/10

### Hepatopancreatic Ampulla (Vater)

- Formed by the union of the (common) bile duct and the main pancreatic duct
- Ampulla empties posteromedially through the major duodenal papilla (of Vater) into the retroperitoneal, descending (second) part of the duodenum.
- Hepatopancreatic sphincter (of Oddi): formed from a complex of smooth muscle surrounding the terminal part of the ampulla and its contributing duct

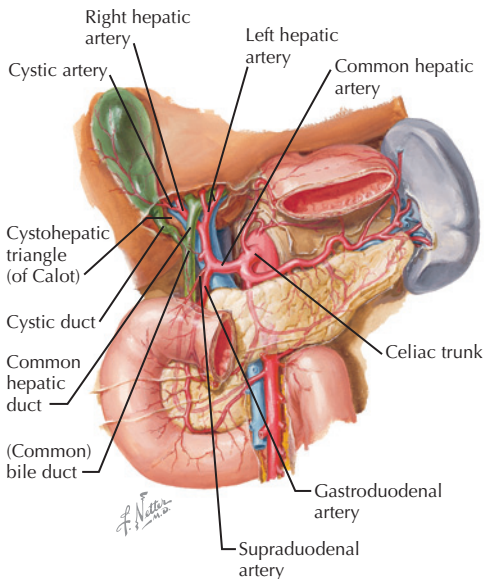
### Bile Secretion

- Increased by cholecystikinin (CCK), secretin, and vagal activity
- Decreased by vasoactive intestinal peptide (VIP), somatostatin, sympathetic activity
- CCK causes tonic gallbladder contraction.
- Bile mediates absorption of fat-soluble vitamins and excretion of bilirubin and cholesterol.

## VESSELS AND LYMPHATICS

### Arteries

- Gallbladder is supplied by cystic artery, typically a branch of the right hepatic artery (from the hepatic artery proper, off common hepatic, celiac axis).
- Source and course of the cystic artery *vary widely*: this must be carefully determined in cholecystectomy.



### Biliary System Arteries

- Variants include origins from common hepatic, left hepatic, and superior mesenteric arteries, passing anterior or posterior to hepatic or bile ducts.
- Bile ducts: supplied by branches of posterior superior pancreaticoduodenal, retroduodenal, right, and left hepatic arteries (celiac axis)

## Veins

- Cystic veins are variable; veins from the body typically pass directly into the liver to drain into hepatic sinusoids.
- Other veins from the neck and cystic duct typically drain directly into the right portal venous system, and some veins drain the biliary duct system.

## Lymphatics

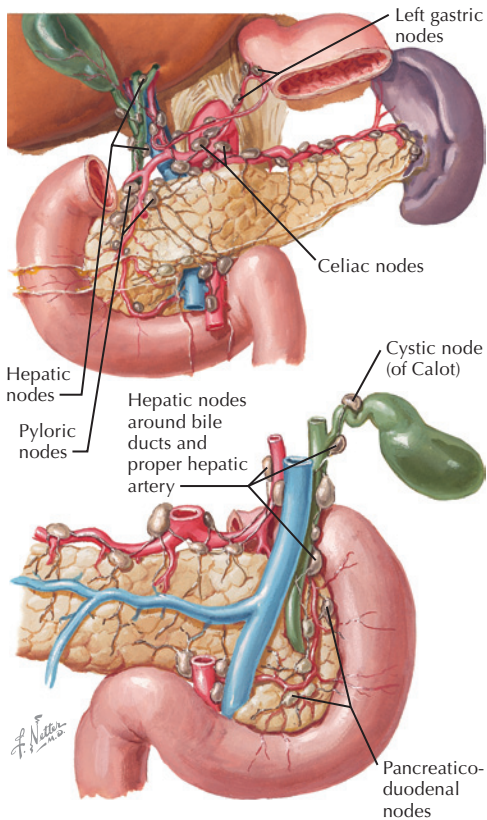
- Cystic lymph nodes cluster around the neck.
- Cystic lymphatics also drain into hepatic nodes clustered around the upper bile duct.
- Deeper drainage into celiac nodes around the arterial trunk

## CLINICAL CORRELATES

### Normal Bile Production

- 500 to 1000 mL/day
- Secretin production and meals rich in fats increase bile production.
- Bile constituents: electrolytes, bile salts, proteins, cholesterol, fats, and bile pigments
- Major salts: cholic, deoxycholic, and chenodeoxycholic acids; anionic and conjugated with taurine or glycine
- Contains unesterified cholesterol, lecithin, and fatty acids
- pH of 5.6-8.6 is normal range.
  - More alkaline at higher secretion rates
  - More acidic with protein in meals
- Cholesterol solubility and lack of stone precipitation depend on a balance among cholesterol, bile salts, and lecithin (in micelles).





Lymph Vessels and Nodes of Pancreas

- Gallbladder also secretes mucus, which protects tissues from the lytic action of bile.

### Control of Bile Secretion

- Bile produced by the liver is shunted to the gallbladder, with the sphincter of Oddi tonically closed (between meals).
- Cholecystokinin is secreted by intestinal mucosa in response to ingestion of food.
- Gallbladder contracts and pushes bile into the ductal system.
- Sphincter of Oddi relaxes, and bile is released into duodenum.

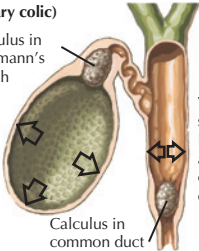
### Cholelithiasis

- Incidence: about 10% of the population, with most asymptomatic
- Diabetics not at increased risk, though inflammatory responses can complicate late-detected cases, with higher incidence of open surgery
- Only about 10% of bile stones are radiopaque.
- Nonpigmented stones
  - Most common type in U.S. (~75%)
  - Increased insolubilization of cholesterol
  - Factors can include cholestasis, increased H<sub>2</sub>O reabsorption, Ca<sup>2+</sup> nucleation by mucin glycoprotein, and decrease in bile acids and lecithin.
- Pigmented stones
  - Occurrence ~25% in U.S., most common worldwide
  - Precipitation of calcium bilirubinate and insoluble salts, with solubilization of unconjugated bilirubin

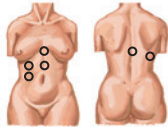
## Mechanisms of biliary pain

### Sudden obstruction (biliary colic)

Calculus in Hartmann's pouch



Calculus in common duct

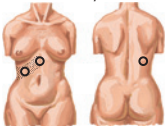


Sites of pain in biliary colic

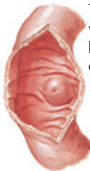Visceral pain, mediated by splanchnic nerve, results from increased intraluminal pressure and distention caused by sudden calculous obstruction of cystic or common duct.

*F. Netter M.D.*  
JOHN A. CRAIG, MD

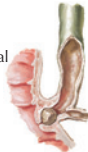### Persistent obstruction (acute cholecystitis)



Sites of pain and hyperesthesia in acute cholecystitis

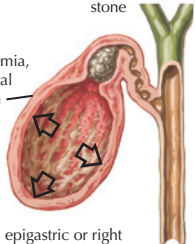


Transduodenal view of bulging of ampulla



Ampullary stone

Edema, ischemia, and transmural inflammation



Patient lies motionless because jarring or respiration increases pain. Nausea is common.



Parietal epigastric or right upper quadrant pain results from ischemia and inflammation of gallbladder wall caused by persistent calculous obstruction of cystic duct. Prostaglandins are released.

## Cholelithiasis

- Black stones may be caused by cirrhosis, hemolytic disorders, ileal resection, or chronic total parenteral nutrition (TPN).
- Usually found only in the gallbladder

## Diagnostic Procedures

- Liver and biliary function tests
  - Serum alkaline phosphatase: very sensitive to obstruction; sensitivity increased by isoenzyme data blood levels
  - Serum glutamic-oxaloacetic transferase (AST/SGOT) blood levels
  - Serum glutamate-pyruvate transaminase (ALT/SGPT) blood levels
  - Lactic acid dehydrogenase (LDH) blood levels
  - Blood bilirubin levels
- Ultrasound
  - Often the first test ordered for suspected biliary tract disease
  - Safe, inexpensive
  - 95% sensitivity for stones, identifies gallbladder morphology and mechanical versus metabolic sources of jaundice
- Endoscopic retrograde cholangiopancreatography (ERCP)
  - Catheter from a side-viewing endoscope is inserted into the ampulla of Vater.
  - Contrast agent is injected.
  - Radiographs are taken.
  - Device can perform sphincterotomy if needed.
  - Standing questions: What are indications for performing an ERCP before a lap chole? Blocked bile duct? May identify variants and reduce injuries?

## Cholecystitis

- Gallbladder wall distention and inflammation
- Most common cause is obstruction of the cystic duct by a stone.
- Classic right upper quadrant pain referred to right scapula and shoulder
- Pain mediated by segmental visceral afferent fibers traveling with the splanchnic nerves (to thoracic spinal segments)
- Nausea, vomiting, loss of appetite, pain
- Symptoms often occur after fatty meal, with persistent pain.
- Murphy's sign: patient resists deep inspiration owing to pain, with deep palpation of right upper quadrant
- Ultrasound ~95% sensitivity for stones
- Risk factors for stones: female, obesity, age >40 y, pregnancy, rapid weight loss, vagotomy, TPN, ileal resection

## Cholecystectomy

- Laparoscopic cholecystectomy (lap chole) has been the treatment of choice for many years, preferred to formerly traditional open cholecystectomy.
- Complicated laparoscopic case may be converted to an open cholecystectomy.
- Open cholecystectomy uses conventional surgical instruments with a right upper quadrant or midline abdominal incision.
- Lap chole essentials
  - General anesthesia, subumbilical incision for CO<sub>2</sub> (insufflation) trocar

- 3 trocars placed (for laparoscope and specialized tools) in right subcostal region
- Retraction of gallbladder, incision of triangle of Calot
- Dissection and ligation of cystic duct and artery
- Dissection and removal of gallbladder
- Most common bile duct injuries associated with laparoscopic cholecystectomy
  - (Common) bile duct mistaken for cystic duct and transected
  - Variable extent of extrahepatic biliary tree excised with gallbladder
  - Right hepatic artery injured with dissection

### Gallstone Pancreatitis

- Estimated 40% of acute pancreatitis cases result from transient obstruction of pancreatic duct flow by stones blocking bile duct or ampulla of Vater.
- Mechanism of such pancreatitis not known
- Symptoms: epigastric and radiating back pain, nausea, vomiting, elevated serum lipase and amylase levels
- Treatment can complicate the timing of a related cholecystectomy.
- ERCP may be needed if an impacted ampulla is suspected.

### Carcinoma of the Biliary Tract

- Can occur at any point along the intra- or extrahepatic biliary tree and gallbladder
- Gallbladder carcinoma is the most common biliary cancer and the fifth most common GI cancer.

# 11

## Colon Diseases

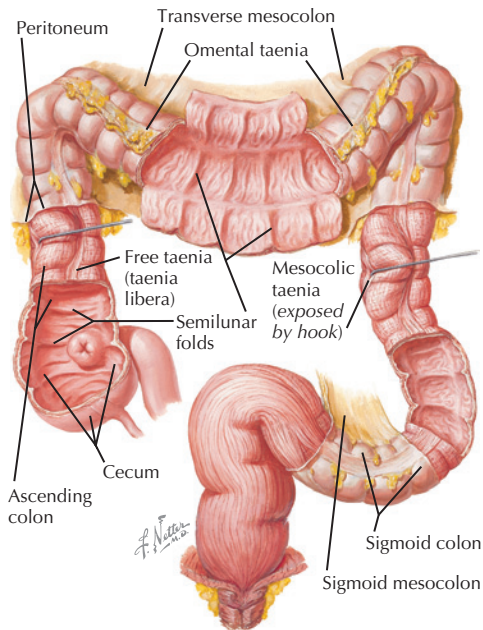
### ANATOMY OF THE COLON

#### Parts and Landmarks

- Cecum, appendix, and ascending, transverse, descending, and sigmoid colon ~150 cm total length
- Cecum has the largest diameter: with obstruction, this is the most likely location for a perforation (greatest increase in pressure, per Laplace's law).
- Colon externally distinguished by omental (epiploic) appendices, haustra (sacculations), and taeniae coli (triple bands of longitudinal smooth muscle)
- Only transverse and sigmoid portions typically have mesenteries.
- Greater omentum is fused to the transverse mesocolon and may be carefully separated surgically.
- Inferior ascending colon can have a mesentery (~10%) and is very mobile (risk for volvulus).
- See also appendix and anorectal topics.

#### Microscopic Anatomy

- Mucosa
  - Epithelium: enterocytes (absorptive), goblet cells
  - Lamina propria
  - Muscularis mucosa



### Viscera: Mucosa and Musculature of Large Intestine

- Submucosa: strongest layer (connective tissue); Meissner's plexus (neuronal network)
- Muscularis
  - Auerbach's plexus: myenteric neurons
  - Inner circular muscle



- Outer longitudinal layer reduced to 3 bands: *taeniae coli*
  - ▲ Mesocolic: posterior, attached to sigmoid and transverse mesocolon
  - ▲ Omental: to which the epiploic appendages (appendices) are attached
  - ▲ Free: with no omental or mesenteric attachments
  - ▲ The taeniae merge into a continuous layer in the appendix and the rectum.
- Serosa: peritoneum
- Haustra: sacculations of the wall between the taeniae

## Embryology

- From the cecum to the splenic flexure of the transverse colon, the colon was derived from the caudal midgut and is supplied by the superior mesenteric artery and vagus.
- From the descending colon through the rectum, the colon was derived from the hindgut and is supplied by the inferior mesenteric artery and sacral parasympathetics.

## Innervation

### *Parasympathetic*

- Preganglionic fibers
  - Vagus: innervate colon from ileocecal junction to splenic flexure
  - Pelvic splanchnic nerves (S2-S4): innervate descending and sigmoid colon
- Postganglionic fibers
  - Meissner's plexus: inner submucosal layer contains parasympathetic ganglion cells

- Auerbach's plexus: outer, myenteric, contains parasympathetic ganglion cells

### *Sympathetic*

- Preganglionic fibers distributed via splanchnic nerves to superior and inferior mesenteric plexuses
- Postganglionic fibers from cells in the following
  - Superior mesenteric ganglion to the ascending and transverse colon via superior mesenteric plexus
  - Inferior mesenteric ganglion to the descending and sigmoid colon via inferior mesenteric plexus

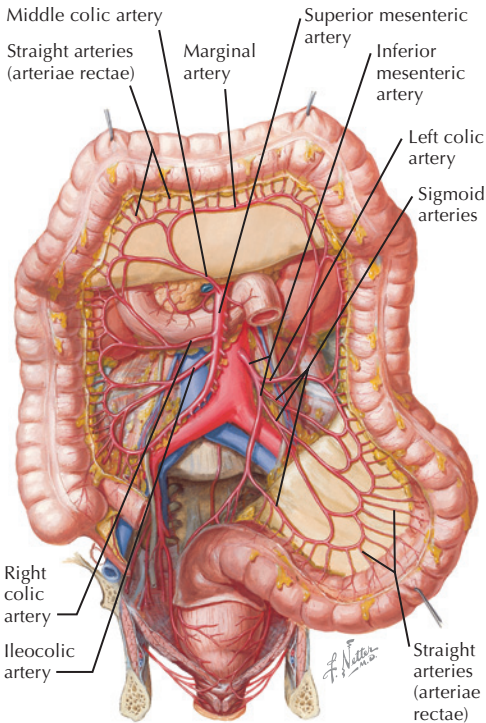
### *Sensory Fibers*

- Vagal afferents from ascending and transverse colon
- Segmental visceral afferents for ascending and transverse colon travel parallel to sympathetics through the superior mesenteric plexuses and splanchnic nerves.
- Descending and sigmoid colon send visceral afferents through the inferior mesenteric, hypogastric, and pelvic plexuses.

## **VESSELS AND LYMPHATICS**

### **Arterial Supply**

- Superior mesenteric artery branches
  - Ileocolic artery (with appendicular branch)
  - Right colic artery
  - Middle colic artery
- Inferior mesenteric artery branches
  - Left colic artery (retroperitoneal)
  - Sigmoid arteries (3 or 4)
  - Superior rectal artery



Arteries of Large Intestine

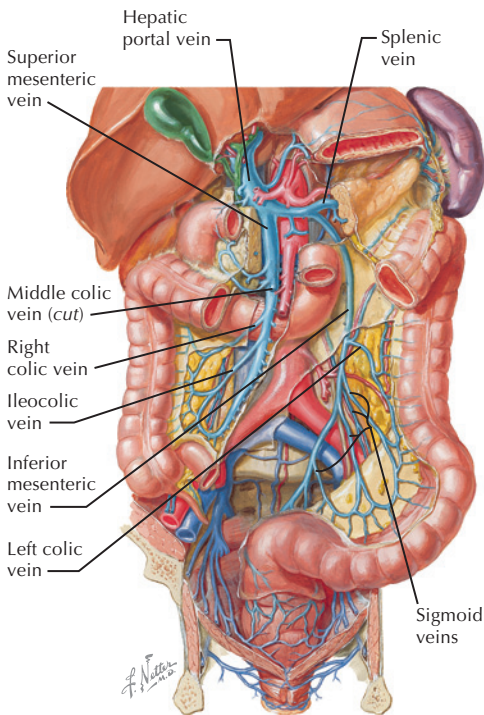
- Marginal artery anastomoses between the superior and inferior mesenteric arteries
- Internal iliac artery branches
  - Middle rectal artery
  - Inferior rectal artery
- Rectal arteries anastomose: inferior mesenteric to internal iliac branches

### Venous Drainage

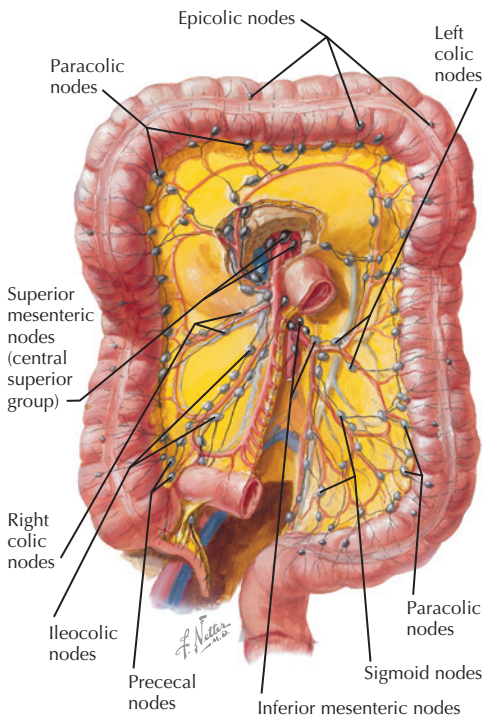
- Superior mesenteric vein (right portal vein tributaries)
  - Ileocolic vein (with appendicular branch)
  - Right colic vein
  - Middle colic vein
- Inferior mesenteric vein (drains into splenic: left portal vein tributaries)
  - Left colic veins
  - Sigmoid veins
  - Rectosigmoid veins
  - Superior rectal veins
- Internal iliac veins (inferior vena cava tributaries)
  - Middle rectal veins
  - Inferior rectal veins
- Rectal veins anastomose in “hemorrhoidal plexus” of rectum, the site of portocaval shunting and hemorrhoids in portal hypertension (see also anorectal topics, [Chapter 18](#)).

### Lymphatic Drainage

- Parallels the arterial supply
- Right-sided mucosal and epicolic nodes drain along superior mesenteric branches into superior mesenteric nodes.



Veins of Large Intestine



Lymph Vessels and Node of Large Intestine

- Left-sided nodes drain along inferior mesenteric artery branches into inferior mesenteric and lateral aortic nodes.
- Deeper drainage superiorly into nodes along aorta and into the cisterna chyli

## CLINICAL CORRELATES

### Diverticula

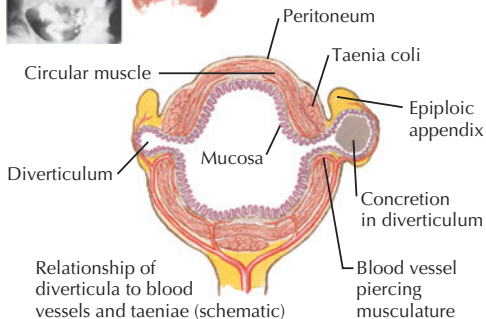
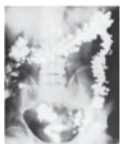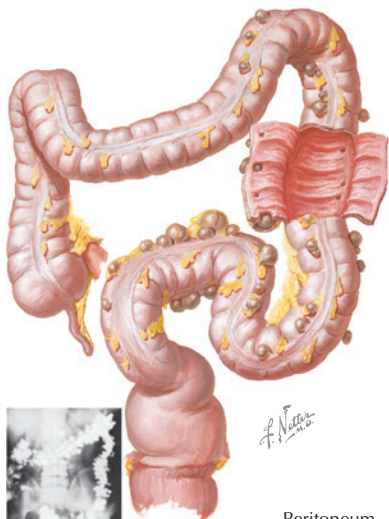
- True (congenital) diverticulum: consists of entire gut wall, not usually seen in colon (e.g., Meckel's diverticulum [in terminal ileum])
- False (acquired) diverticulum: mucosa protruding through muscle wall, typical of colon
- Acquired diverticula usually occur adjacent to taeniae coli, where nutrient arteries penetrate the bowel wall.

### Diverticulosis

- Incidence: 5%-10% of persons older than 45 years, 50%-60% by age 60 years, approaching 80% by 80 years
- 80%-90% of diverticula seen in sigmoid colon
- Cause thought to be increased intraluminal pressure owing to slowed fecal transit
- High-fat, low-fiber diets a contributing factor
- About 3 times more likely in men
- About 20% of cases in persons younger than 50 years
- Much less prevalent currently in less industrialized societies
- Visualized with abdominal CT

### Diverticulitis

- Inflamed diverticula and/or perforation, assumes diverticulosis



Diverticulosis of Colon



- Usually manifests with fever and left lower quadrant pain
- Diffuse abdominal pain can indicate perforation.
- A very redundant sigmoid can produce symptoms in any quadrant.
- Constipation, nausea, and vomiting can occur.
- Occurs in 5%-10% of patients with diverticulosis, over a 5-year period
- Occurrence increases to 35% over 20 years.

## Polyps

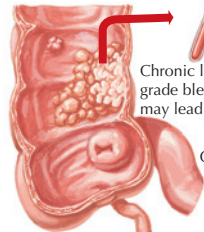
- *Categories*: nonmalignant, premalignant, malignant
- Sessile: flat
- Pedunculated: stalked
- Juvenile polyps
  - In patients younger than 10 years
  - Typically nonmalignant hamartomas
- Adenomas
  - Benign, premalignant
  - Types: tubular, villous, or mixed
  - Peak incidence at ~50 years

## Cancer

- Colorectal cancer: diagnosed in ~130,000 Americans per year
- Adenocarcinoma most common type
  - Ulcerative: most common, central depression with raised edges
  - Polypoid: large, as described for polyps
  - Annular: apple core appearance on contrast study, associated with obstruction
  - Diffusely infiltrating:
    - ▲ Thickening of bowel wall
    - ▲ May be flat
    - ▲ Difficult to diagnose

Clinical manifestations of colorectal cancer

Right (ascending) colon



Chronic low-grade bleeding may lead to anemia

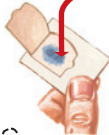
Liquid fecal stream passes lesion

Bleeding diluted by fecal stream

Obstruction uncommon because of large lumen and liquid fecal contents

Solid stool

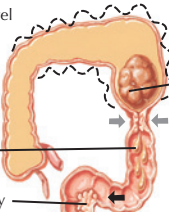
Lesions of right colon often asymptomatic, or "silent," until disease is in advanced stage



Bleeding diluted by feces results in normal-appearing but guaiac-positive stool

JOHN A. CRAIG, MD

Change in bowel habits may be first symptom of left colon lesions



Cramping pain

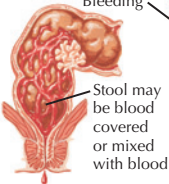
Constipation and obstruction

Paradoxical diarrhea

Tenesmus and urgency

Bleeding

Left (descending) colon



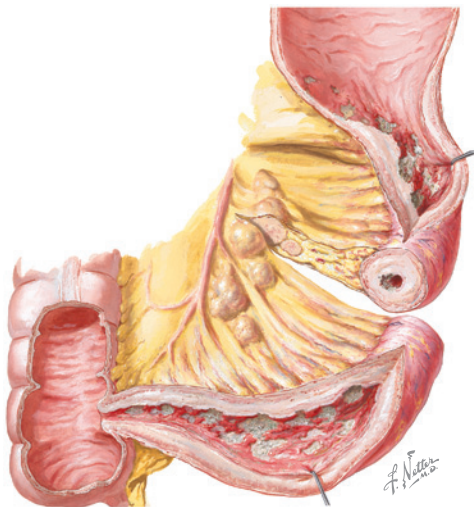
Stool may be blood covered or mixed with blood

Cancer of left colon and rectum frequently causes bleeding and bowel obstruction due to solid feces

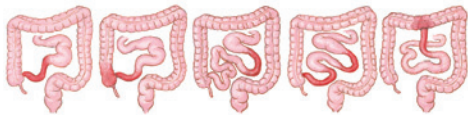Colorectal Cancer

## Colitis (by Type)

- Amebic colitis
  - Site of primary infection by *Entamoeba histolytica*
  - Risk factors include travel in Mexico, alcohol ingestion
- Ischemic colitis: caused by low flow state or inferior mesenteric ligation
- Pseudomembranous colitis
  - Caused by *Clostridium difficile* infection
  - Can occur after antibiotic treatment
- Crohn's disease
  - Idiopathic inflammatory bowel disease, usually involving small and large intestine, but lesions can occur in GI tract from mouth to anus
  - Higher rate of occurrence in Ashkenazi Jews
  - Terminal ileum is the most commonly involved segment.
  - Asymmetrical distribution of lesions
  - Discrete (aphthous) and longitudinal ulcers common
  - Gross bleeding may be absent (25%-30%).
  - Rectum often spared (~50%)
  - Perianal disease ~75%
  - Fistulization
  - Granulomas 5%-75%
  - Discontinuous mucosa involvement
  - Mucosal friability uncommon
  - Relatively normal surrounding mucosa
  - Cobblestoning in severe cases
  - Normal vascular pattern
  - Surgery *not* curative (unlike ulcerative colitis)



Regional enteritis  
confined to terminal ileum

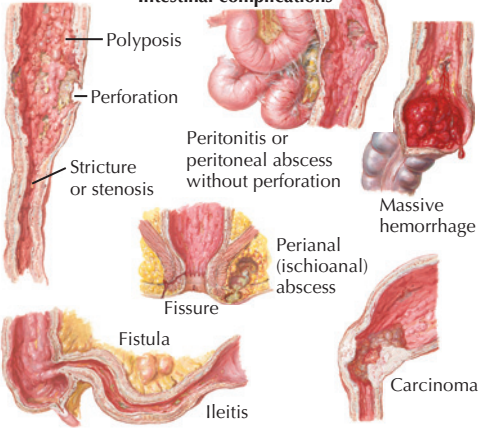


Involving  
cecum

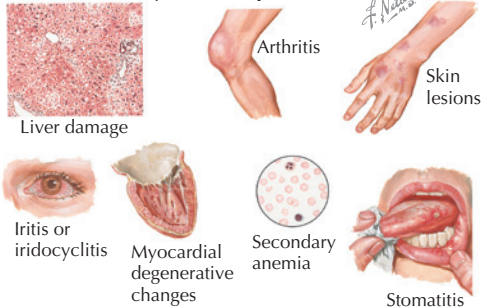
At ileo-  
colostomy

Crohn's Disease

## Intestinal complications



## Systemic complications



## Ulcerative Colitis

- Ulcerative colitis
  - Restricted to colon
  - Continuous distribution of lesions starting distally
  - Rectum involvement ~90%
  - Gross bleeding
  - Perianal disease rare but may be severe
  - No fistulization
  - No granulomas
  - Contiguous mucosa involvement
  - Discrete (aphthous) and longitudinal ulcers rare
  - Abnormal surrounding mucosa
  - No cobblestoning
  - Rectal involvement ~90% of cases
  - Mucosal friability common
  - Distorted vascular pattern

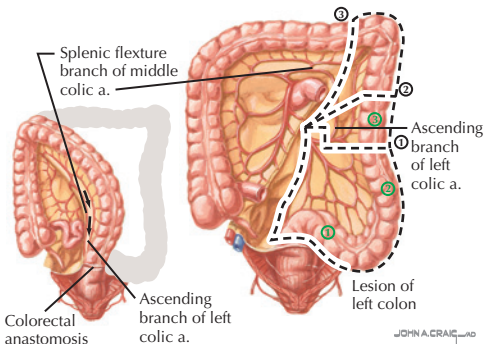
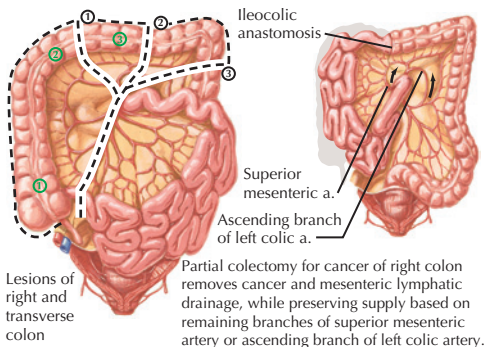
### Large Bowel Obstruction

- Cancer and diverticular disease: most common causes of bowel obstruction in the U.S.
- Volvulus: rare cause of obstruction in the U.S. but most common cause in third world countries (associated with extra-high dietary fiber intake)

### Volvulus

- Twisting of the bowel, causing a blind loop with obstructions at both ends (Latin *volvere*, “to twist, to turn”)
- More common in sigmoid colon (with redundancy and mesentery) and cecum
- In ~11%: very mobile ascending colon with mesentery, predisposing to volvulus
- Midgut volvulus can occur in pediatric patients with malrotations.

### Aspects of Colectomy (Below)



Partial colectomy for cancer of left colon requires transection of inferior mesenteric artery at origin and depends on communication of splenic flexure branch of middle colic artery and ascending branch of left colic artery for vascular supply.

**Broken lines and black, circled numbers = resection, depending on site of lesion (green, circled numbers).**

## Surgical Resection of Colon Cancer

This page intentionally left blank



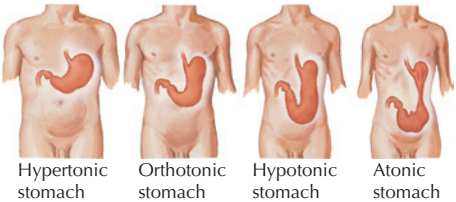
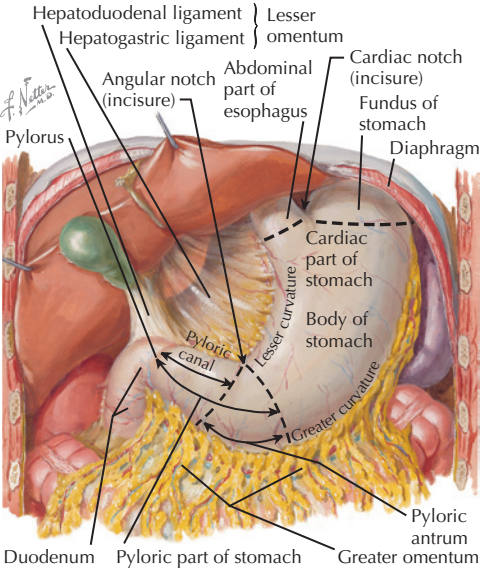
## ANATOMY OF THE STOMACH AND DUODENUM

### Parts of the Stomach

- Cardia(c) portion joins the abdominal esophagus.
- Fundus: uppermost curvature to the left of the cardia
- Greater curvature, lesser curvature, inferior and superior borders (respectively) of the voluminous body of the stomach
- Pyloric region
  - Angular incisure (notch): distal end of the lesser curvature and start of the antrum
  - Antrum: entryway to the pyloric canal, very muscular and peristaltic
  - Pylorus: thickened circular muscle layer
- Rugae: folds in the mucosal surface of the relaxed stomach

### Functional Anatomy and Motility

- Receptive relaxation and accommodation occur in the proximal 1/3 of the stomach, with swallowing and entry of food.
- True peristalsis occurs in the distal 2/3, with waves of contraction driving the contents back and forth between the body and antrum (trituration).



Variations in position and contour of stomach in relation to body habitus

Stomach in Situ

- Small amounts of triturated stomach contents pass through the pylorus with successive peristaltic waves.
- Myoelectric pacemaker for peristalsis is located high on greater curvature.

## Gastric Microscopic Anatomy

### *Mucosa*

- Epithelium
  - Mucus-secreting cardia glands
  - Oxyntic glands in the fundus and body
    - ▲ Chief cells secrete pepsinogen.
    - ▲ Parietal cells secrete  $H^+$  and intrinsic factor.
  - Antrum and pylorus glands
    - ▲ Both secrete  $HCO_3^-$  and mucus.
    - ▲ G cells release gastrin.
    - ▲ D cells secrete somatostatin, inhibiting release of gastrin and  $H^+$ .
- Lamina propria: supportive, loose connective tissue deep to epithelium
- Muscularis mucosae: layer of smooth muscle at the boundary between mucosa and submucosa

### *Submucosa*

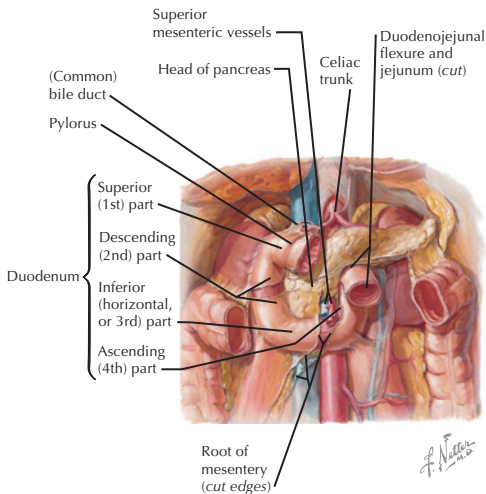
- Strongest layer
- Connective tissue
- Meissner's plexus (neuronal network)

### *Muscularis (Smooth Muscle)*

- Auerbach's plexus: myenteric neurons
- Inner circular muscle
- Outer longitudinal layer

### *Serosa*

- Peritoneum



Duodenum in Situ

### Anatomy of the Duodenum

- Most fixed portion of small bowel, surrounds head of the pancreas
- Superior (first) part
  - Length ~5 cm, lies anterolateral to L1 body
  - Overlain by liver and gallbladder
  - Ampulla (cap)—first 2 cm—bears a mesentery, the hepatoduodenal ligament, part of the lesser omentum.
  - Distal 3 cm retroperitoneal

- Descending (second) part
  - Length 7-10 cm, lies along right sides of L1-L3 bodies
  - Receives the outflow from bile and pancreatic ducts via the hepatopancreatic ampulla (Vater) through the greater duodenal papilla (Vater)
  - Receives outflow from the accessory pancreatic duct through the lesser duodenal papilla
- Horizontal (third) part
  - Length 6-8 cm, crosses the L3 body
  - Lies posterior to the main trunk of the superior mesenteric artery
- Ascending (fourth) part
  - Length ~5 cm, left of L3 to the upper border of L2
- Ligament of Treitz (suspensory ligament of the duodenum): marks duodenal-jejunal junction
- Plicae circulares: internal circular folds of the wall due to circular muscle, increase surface area per length

## Duodenal Microscopic Anatomy

### *Mucosa*

- Epithelium: enterocytes (absorptive), goblet cells, Paneth cells, enterochromaffin cells
- Lamina propria: contains Peyer's patches (lymphoid aggregations with B cells in germinal centers and T cell in interfollicular zones)
- Muscularis mucosa
- Water and nutrients absorbed across the mucosa

### *Submucosa*

- Strongest layer
- Connective tissue

- Meissner's plexus (parasympathetic ganglion cells and neuronal network)

### *Muscularis*

- Inner circular muscle
- Outer longitudinal layer
- Auerbach's plexus: myenteric neurons and parasympathetic ganglion cells

### *Serosa*

- Peritoneum

### *Inner Surface*

- Mucosal surface area specializations: microvilli, villi, plica circulares (valvulae conniventes)
- Total absorptive surface: 200-550 cm<sup>2</sup>

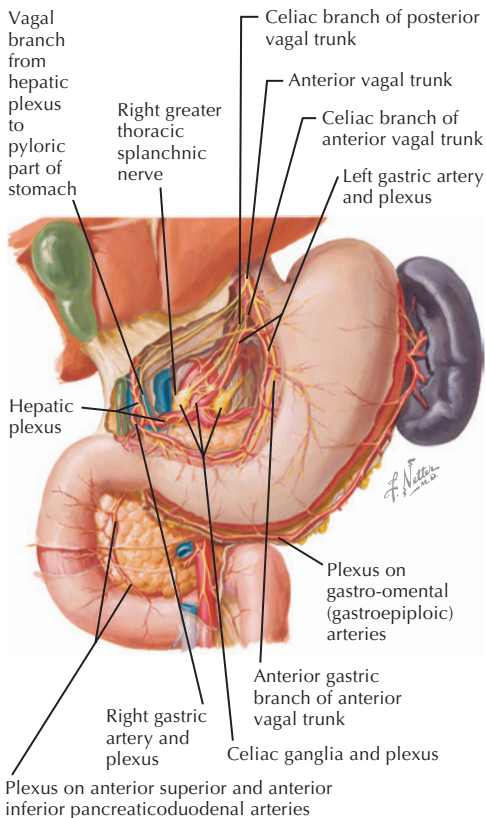
## Gastroduodenal Embryology

- Stomach has two mesenteries during development.
  - Dorsal mesogastrium, attached to the greater curvature, grows very redundant, overlaps, and becomes the greater omentum.
  - Ventral mesogastrium, part of the original septum transversum, becomes the following.
    - ▲ Lesser omentum (hepatogastric ligament)
    - ▲ Peritoneal serosa of liver, gallbladder
    - ▲ Falciform ligament, with embedded round ligament of the liver
- Greater curvature is initially dorsal, then the stomach rotates along its longitudinal axis until the dorsal curve lies to the left.
- Stomach also rotates around an axis through the gastroesophageal junction, until the greater curvature lies in its final left inferolateral position.

- Duodenum also rotates with the stomach, as well as around an anteroposterior axis, so that it surrounds the pancreas.
  - First two parts of the duodenum (down to the bile duct), the terminal portion of the foregut: supplied by the celiac axis
  - Lower second through fourth parts of the duodenum, the initial segment of the midgut: supplied by the proximal superior mesenteric artery

## Innervation

- Parasympathetic
  - *Left* vagal trunk lies *anterior* as it crosses the gastroesophageal junction and runs anteriorly along the lesser curvature toward the duodenum.
  - *Right* vagal trunk lies *posterior* as it crosses the gastroesophageal junction and runs posteriorly along the lesser curvature toward the duodenum.
  - Ganglion cells are located in myenteric (Auerbach's) and submucosal (Meissner's) plexuses in stomach and duodenum.
- Sympathetic
  - Preganglionic fibers from T8-T10 lateral column distributed via splanchnic nerves.
  - Postganglionic fibers are distributed from ganglion cells in celiac and superior mesenteric ganglia, traveling along respective arterial branches.
- Sensory fibers (general visceral afferent)
  - Vagal afferents, including stretch, chemo-, and "satiety" receptors
  - Segmental afferents travel back parallel to sympathetics, through the celiac and superior

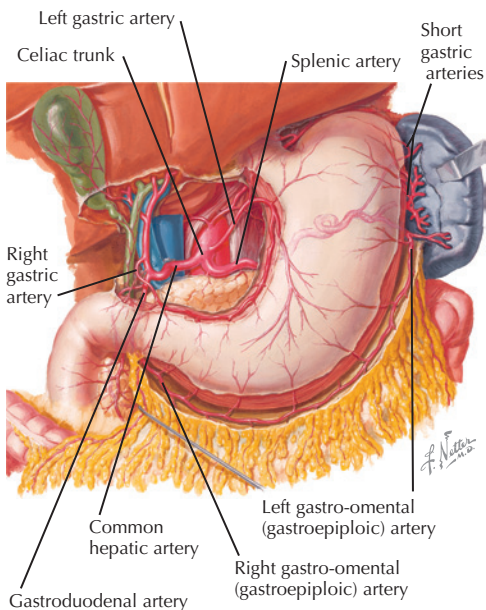


Nerves of the Stomach and Duodenum

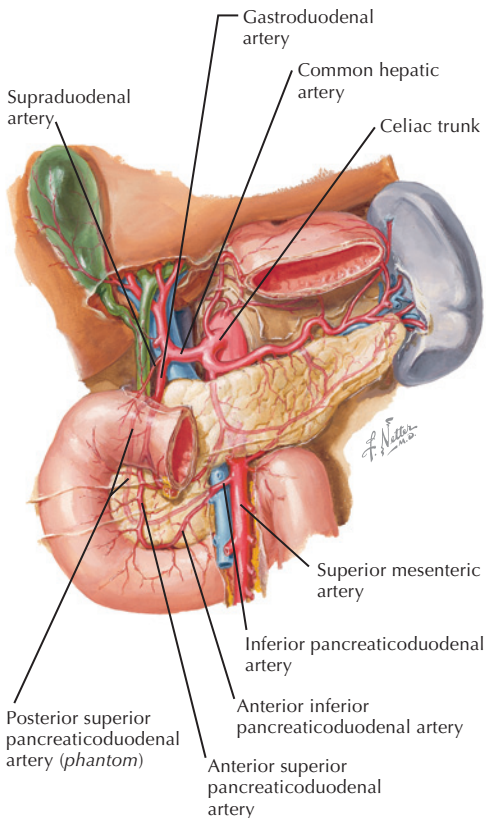


mesenteric plexuses and the splanchnic nerves to thoracic spinal nerves, dorsal root ganglia, and spinal segments.

## ARTERIES, VEINS, AND LYMPHATICS



Arteries of the Stomach



Arteries of the (Pancreas) Duodenum (Spleen)

## Arteries

### *Celiac Trunk (Axis) Branches* *(Highly Variable)*

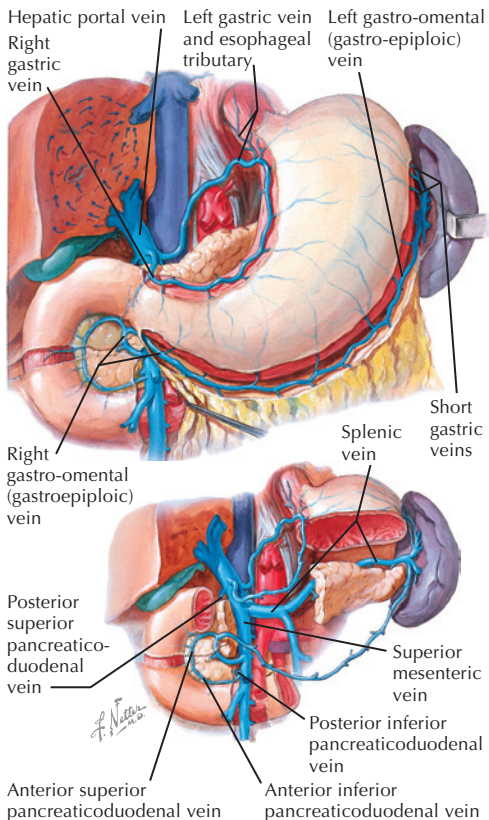
- Left gastric artery: typically the largest gastric branch, to left side of lesser curvature
- Splenic artery branches
  - Posterior gastric artery: to posterior body and fundus
  - Left gastro-omental (gastroepiploic) artery
    - ▲ To left side of greater curvature
    - ▲ Anastomoses with right gastro-omental
  - Short gastric arteries: to fundus region
- Common hepatic artery branches
  - Right gastric artery: to right side of lesser curvature (may be off left or right hepatic)
  - Proper hepatic artery
  - Gastroduodenal artery
    - ▲ Right gastro-omental (gastroepiploic) artery: to right side of greater curvature
    - ▲ Superior pancreaticoduodenal: to first and upper second part of duodenum

### *Superior Mesenteric Artery*

- Inferior pancreaticoduodenal artery
  - Anterior and posterior branches anastomose with superior pancreaticoduodenal branches.
  - Supply duodenum distal to bile duct

## Venous Drainage

- Gastric and duodenal veins parallel arterial branches.
- Portal vein tributaries
  - Right gastric (lesser curvature)
  - Left gastric (coronary; prominent in varices)
  - Superior mesenteric vein (right portal)



Veins of the Stomach, Duodenum, and Pancreas

- ▲ Pancreaticoduodenal veins
- ▲ Right gastro-omental (gastroepiploic) vein
- Splenic vein (left portal)
  - ▲ Short gastric vein
  - ▲ Left gastro-omental (gastroepiploic)

## Lymphatic Drainage

- Parallels the venous drainage (see figure)

## CLINICAL CORRELATES

### Upper Gastrointestinal Bleeding

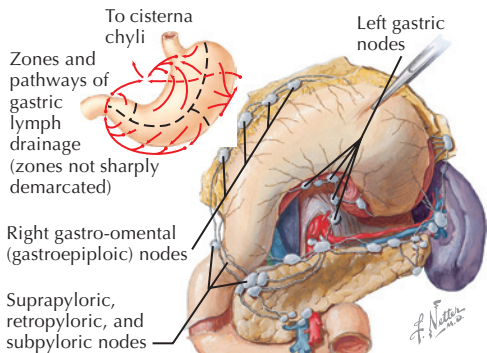
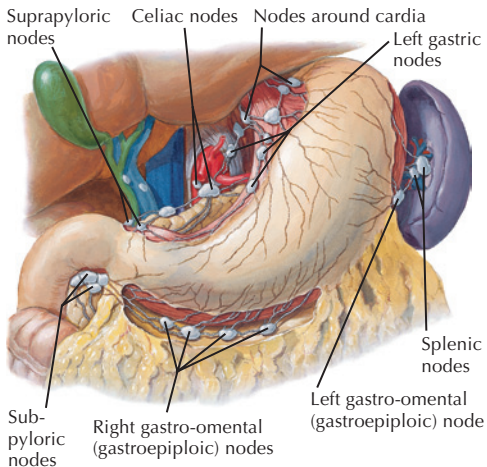
- Differential diagnosis includes gastritis, ulcer, and cancer.

### Gastritis

- Stress gastritis occurs 3-10 days after event; lesions first appear in fundus.
- Chronic
  - Type A: in fundus, associated with autoimmune disease and pernicious anemia
  - Type B: in antrum, associated with *Helicobacter pylori*

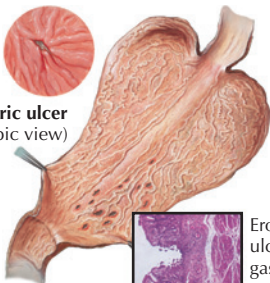
### Peptic Ulcer

- 70%-80% in lesser curvature of the stomach
- Type I: in lesser curvature of the stomach
- Type II: in lesser curvature of the stomach and in the duodenum
- Type III: prepyloric ulcer
- Type IV: in lesser curvature in cardiac region
- Type V: ulcer associated with NSAIDs
- Most (type I and IV) are due to loss of mucosal defensive function with normal acid secretion.



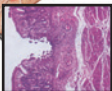
Lymph Vessels and Nodes of Stomach

**Acute gastric ulcer**  
(gastroscopic view)



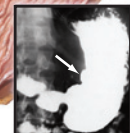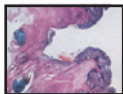
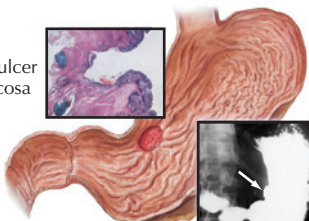
**Acute gastric ulcer**

Erosion of acute ulcer into the gastric mucosa



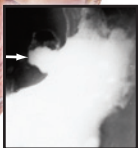
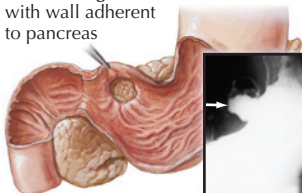
Erosion of chronic ulcer into the gastric mucosa and submucosa

**Chronic gastric ulcer**



Barium contrast image of chronic ulcer

**Perforated gastric ulcer**  
with wall adherent to pancreas



Barium contrast image of perforated ulcer

*F. Netter M.D.*

## Peptic Ulcer Disease

- Duodenal ulcers are most common in the superior part, in the posterior superior wall, and within ~3 cm of the pylorus.
- Duodenal ulcer usually results from mucosal defense being overcome (decreased secretion of mucus and bicarbonate).
- Risk factors: male gender, tobacco, ethanol consumption, NSAIDs, *H. pylori* infection, uremia, stress, steroids, chemotherapy
- Hemorrhage associated with higher mortality

### Hiatal Hernia

- Type I
  - Dilation of hiatus with sliding hernia
  - Most common
  - May be associated with GERD, although most type I patients do *not* reflux
- Type II
  - Paraesophageal, hole in diaphragm next to the esophagus
  - Symptoms: dysphagia, chest pain, early satiety
- Type III: combined
- Type IV: entire stomach in thorax, other organs may be included (e.g., spleen or colon)

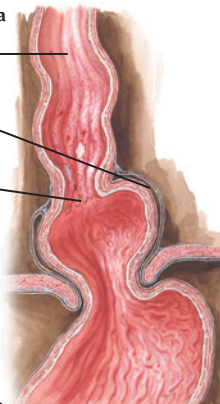
### Cancer

- Adenocarcinoma of the small bowel
  - Most common small bowel malignancy
  - Rare, but occurs more commonly in duodenum
  - Risk factors: familial adenomatous polyposis, Gardner's syndrome, polyps, adenomas, von Recklinghausen's syndrome



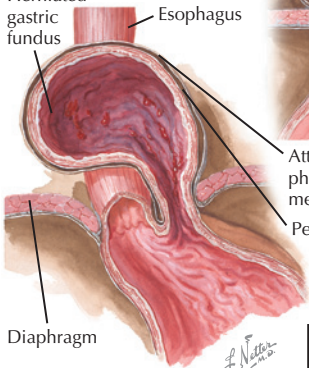
### Sliding hernia

Esophagus  
Peritoneal sac  
Squamo-columnar junction



### Paraesophageal hernia

Herniated gastric fundus  
Esophagus

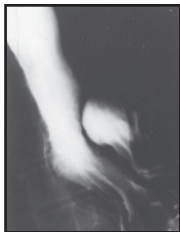

Attenuated phrenoesophageal membrane  
Peritoneal sac

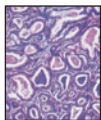
Diaphragm

*F. Natter M.D.*

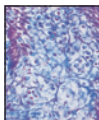
Barium study shows paraesophageal hiatus hernia.



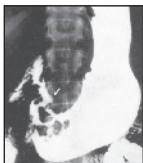### Hiatal Hernias

**Polypoid adenocarcinoma**

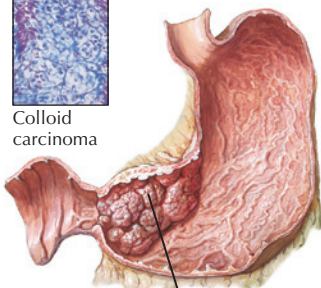
Adenocarcinoma



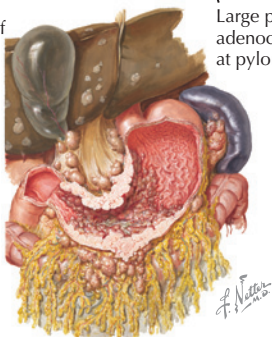
Colloid carcinoma



Radiographic appearance of polypoid adenocarcinoma



Large polypoid adenocarcinoma at pyloric antrum

**Carcinoma of stomach**

Extensive carcinoma of stomach with metastases to lymph nodes, liver, omentum, tail of pancreas, and hilus of spleen; biliary obstruction

**Gastric Carcinoma**

- Adenocarcinoma of the stomach
  - More than 20,000 new U.S. cases per year (rate declining)
  - Dietary risk factors might include spicy and smoked food.
  - Associated with atrophic gastritis with hypoacidity
  - Chronic *H. pylori* infection is a major risk factor.
  - 7%-10% of ulcers associated with an adenocarcinoma
  - Hyperplastic gastric polyps (most common, 80%) have little risk.
  - Adenomatous gastric polyps have a 15% risk of developing malignancy.
  - Polyps of either kind may be asymptomatic or associated with vague abdominal discomfort.
- Lymphoma
  - Can occur as a manifestation of diffuse lymphoma (more common)
  - Isolated gastric disease
  - 50% of all lymphomas occur in the stomach
  - Primary gastric lymphoma can be treated by partial gastrectomy.
- Gastrointestinal stromal tumor (GIST): 3% of gastric malignancies

### Billroth Procedures

- Billroth I: antrectomy with gastroduodenal anastomosis
- Billroth II: antrectomy with gastrojejunal anastomosis
- Increased marginal ulceration with diarrhea with Billroth procedures, compared with Roux-en-Y gastrojejunostomy

## Zollinger-Ellison Syndrome

- Tumors may be multiple and metastatic.
- Pancreatic tumors may be surgically enucleated from the gastric wall.
- Enucleation and resection are considered necessary for effective palliation and reduced need for drug treatment.
- Total gastrectomy is indicated with nonresectable tumors for best long-term quality of life.
- See figure on [page 264](#) for more information.

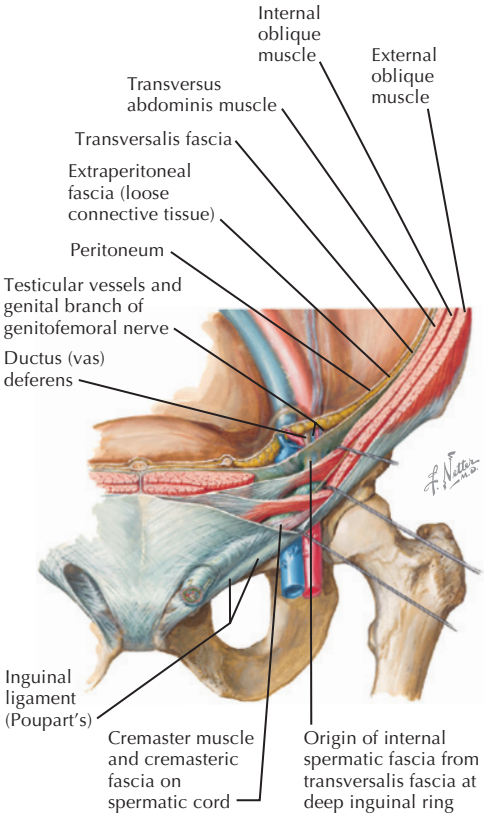
## ANATOMY OF THE ABDOMINAL WALL

### Abdominal Wall Layers

- Following are layers from the surface in.
  - Skin
  - Superficial fascia with a variable amount of subdermal fat: Camper's fascia, overlying membranous Scarpa's fascia (subumbilical level)
  - Muscle bellies and aponeuroses of the rectus abdominis, external and internal obliques, and transversus abdominis muscles
  - Transversalis fascia
  - Endoabdominal fascia and the peritoneum (greater sac)

### External Oblique (EO) Muscle

- Bilateral origins off of the lower ribs, lumbar fascia, and iliac crest
- On each side, the lower border of its aponeurosis attaches to anterior superior iliac spine and pubic tubercle to form the inguinal ligament.
- Distally, a portion of EO aponeurosis fibers arch posteriorly to insert on the superior pubic ramus, forming the lacunar ligament (of Gimbernat).
- Most lateral of these deep (lacunar) fibers continue to run along the pectin of pubis as the pectineal ligament (of Cooper).



Abdominal Wall: Inguinal Region

- Some of the most distal fibers arch upward, avoid the pubic tubercle, and merge with the opposite side's fibers as the reflected inguinal ligament.
- Most muscle and aponeurotic fibers run superolateral to inferomedial (“hands in pockets” orientation).
- Medial part of the EO aponeurosis contributes the most anterior fibers of the rectus sheath.
- Superficial (external) inguinal ring: division in the most inferior aponeurosis; spermatic cord or round ligament passes through
- External oblique fascia contributes to external spermatic fascia.
- Fibers of the medial crus (of the superficial ring) attach to the pubic crest.
- Fibers of the lateral crus attach with the rest of the inguinal ligament to the pubic tubercle.
- EO aponeurosis is relatively weak superiorly, very strong inferiorly.
- Innervation: anterior rami T7-T12 (thoracoabdominal and subcostal nerves)

### Internal Oblique (IO) Muscle

- Bilateral origins off the lower ribs, lumbar fascia, and iliac crest
- Fibers run deep, approximately perpendicular to the external oblique layer, from the deep lumbar aponeurosis, curving anteriorly then medially.
- Cremaster muscle and fascia: IO layer surrounding internal spermatic fascia
- Medial IO aponeurosis layer splits to pass around the rectus, as the middle layer of the rectus sheath, above the semicircular lines (of Douglas).

- On each side, the inferior triangle of the IO aponeurosis fuses with the transversus aponeurosis to form the conjoined (conjoint) tendon.
- Innervation: anterior rami T7-T12 (thoracoabdominal nerves) and L1

### Transversus Abdominis (TA) Muscle

- Bilateral origins off the lower ribs, lumbar fascia, and iliac crest
- Fibers run deep to the internal oblique layer, mostly posteriorly, becoming largely aponeurotic laterally in the deep back.
- Medial aponeurotic fibers pass posterior to the rectus, as the posterior layer of the rectus sheath, above the semicircular lines (of Douglas).
- On each side, the inferior triangle of the TA aponeurosis fuses with the internal oblique aponeurosis to form the conjoined (conjoint) tendon.
- Deep (internal) inguinal ring: gap in the transversus abdominis, lateral to the inferior epigastric arteries
- Innervation: anterior rami T7-T12 (thoracoabdominal nerves) and L1

### Rectus Abdominis Muscle

- Parallel segments of muscle with vertically running fibers; segments joined end-to-end by tendinous insertions (inscriptions)
- Upper segments well separated at the midline
- Lower segments close together at the midline
- External oblique aponeurosis is always the most superficial (anterior) component of the rectus sheath.



- Internal oblique aponeurosis splits to run in front of and behind rectus in the sheath above the semilunar lines (somewhat above umbilicus).
- External and internal oblique and transversus aponeuroses components of rectus sheath pass anterior to the rectus below the semicircular lines (below the umbilicus).
- Pyramidalis muscle, present in ~80%
  - Lies anterior to the inferior part of the rectus
  - Attaches to the anterior pubis and anterior pubic ligament
  - Inserts on the linea alba and tenses it
- Innervation: anterior rami T7-T12, thoracoabdominal nerves

### Linea Alba

- Midline, tendinous junction between right and left portions of the rectus sheath and the underlying midline tendons of the rectus muscle segments
- Tends to be broader, more well developed superiorly
- Umbilical gap lies about 2/3 of the way down from the linea origin at the xiphoid process.

### Transversalis Fascia

- Tough fascial layer just deep to the transversus muscle and aponeurosis, rectus sheath, and rectus abdominis anteriorly
- Overlies the endoabdominal fascia (and fat) superficial to the peritoneum
- Male transversalis fascia outpockets through the deep (internal) inguinal ring, a gap in the transversus abdominis, lateral to the inferior epigastric arteries.

- Internal spermatic fascia: transversalis fascia layer surrounding the layers of the tunica vaginalis around the descended testis, its duct, and vessels
- Iliopubic tract: thickened inferior margin of the transversalis fascia, running parallel, posterior, and deep to the inguinal ligament (reinforcing)
- Round ligament passes through the deep inguinal ring in the female.

### Hesselbach's Triangle

- Anatomical area (on either side) of the inferior and anterior abdominal wall, lying between the inferior epigastric artery and the midline
- Lies deep to the conjoint tendon
- Anteromedial to the deep inguinal ring
- Direct inguinal hernias directly penetrate the wall (i.e., conjoint tendon) in this region.
- Indirect inguinal hernias pass through the deep ring lateral to this region (and the inferior epigastric artery).

### Inguinal Canal Boundaries

- Anterior: external oblique aponeurosis
- Posterior: transversalis fascia and a variable amount of transversus abdominis fascia
- Inferior: inguinal and lacunar ligaments
- Superior: internal oblique and transversus abdominis muscles and aponeuroses
- Internal (deep) inguinal ring: entry point through a transversus abdominis muscle gap for spermatic cord or round ligament
- External (superficial) inguinal ring: division in external oblique aponeurosis that passes the spermatic cord or round ligament

## Spermatic Cord Layers and Contents

- External spermatic fascia (external oblique fascia)
- Cremasteric layer and cremasteric artery
- Internal spermatic fascia (from transversalis)
- Parietal tunica vaginalis (peritoneal origin)
- Visceral tunica vaginalis around deeper viscera
  - Vas and ductus deferens, deferential artery
  - Testicular veins and pampiniform plexus
  - Testicular artery
  - Nerves (testicular, autonomic, sensory)
  - Testis with tunica albuginea

## Nerves Near the Spermatic Cord

- Iliohypogastric: superficial if seen
- Ilioinguinal: typically superficial to cord
- Genitofemoral: usually posterior to cord

## VESSELS AND LYMPHATICS

### Regional Arteries and Veins

- External iliac arteries and veins run across the pelvic brim, passing under the inguinal ligament to become the femoral arteries and veins.
- Inferior epigastric vessels arise from the external iliac vessels just before they pass through the inferior abdominal wall.
- Inferior epigastric vessels run superiorly through the deep surface of the rectus abdominis, to anastomose within it with branches of superior epigastrics.
- Testicular arteries pass down from their source on the aorta (renal levels) to enter deep inguinal

ring with ductus deferens and pass with spermatic cord through inguinal canal to attach to testis.

- Superficial epigastric arteries and veins arise from the femoral vessels (below the inguinal ligament) and curve superomedially to supply anterior inferior abdomen superficially.
- Small cremasteric branches of inferior epigastric vessels accompany spermatic cord.

### Lymphatics

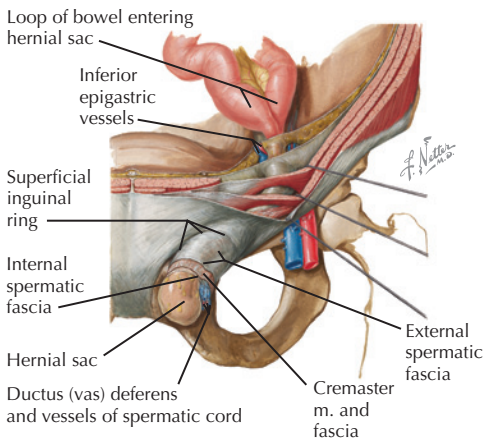
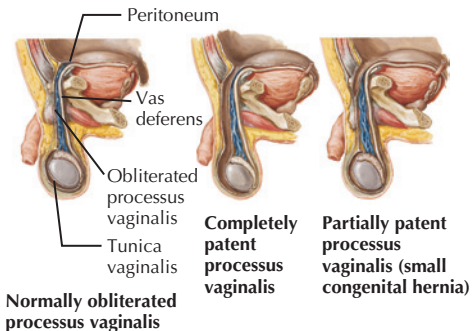
- Superficial lymphatics of abdominal wall above umbilicus drain into axillary nodes.
- Superficial lymphatics of abdominal wall below umbilicus drain into inguinal nodes.
- Enlarged inguinal nodes should not be mistaken for an inguinal hernia because of their placement below inguinal ligament.

### CLINICAL CORRELATES

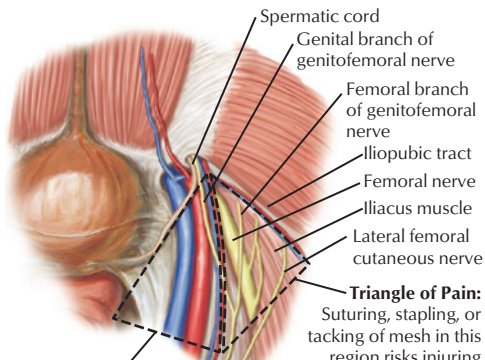
- In hernias, portions of peritoneum (sac), abdominal fat, or adjacent viscus or viscera protrude through defects or gaps in abdominal wall.
- Incarceration: abdominal contents are trapped in the hernia, can progress to strangulation (acute: emergency)
- Strangulation: blood vessels to a viscus are compressed, causing ischemia and necrosis
- Reduction: hernia contents are returned to their normal position in the abdomen

### Inguinal Hernia

- 80%-90% of abdominal hernias



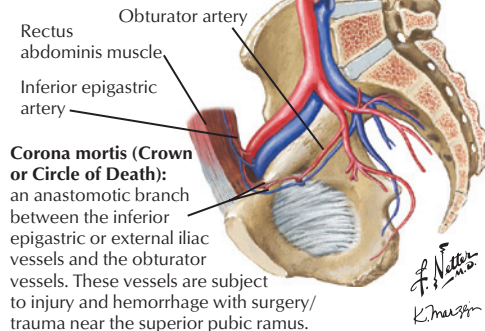
**Indirect Inguinal Hernia**



**Triangle of Doom:**

Suturing, stapling, or surgical dissection in this region risks perforation of the external iliac vessels with hemorrhage.

**Triangle of Pain:**  
Suturing, stapling, or tacking of mesh in this region risks injuring branches of the genitofemoral, lateral femoral cutaneous, or femoral nerves.



**Corona mortis (Crown or Circle of Death):**

an anastomotic branch between the inferior epigastric or external iliac vessels and the obturator vessels. These vessels are subject to injury and hemorrhage with surgery/trauma near the superior pubic ramus.

*F. Netter M.D.*  
*K. Morrison*

Inguinal Landmarks in Hernia Repair:  
Warning Triangles and Corona Mortis

## Types

- Indirect
  - Passes through deep (internal) inguinal ring, inguinal canal, and finally through superficial (external) inguinal ring; follows course of spermatic cord
  - Typically congenital, associated with a persistence of the fetal processus vaginalis (peritoneal tract accompanying the descending testis)
  - Hernial sac lies within the spermatic cord, necessitating dissection in herniorrhaphy
  - More than 2/3 of inguinal hernias are indirect.
  - Hydrocele: excess fluid in persistent processus vaginalis
- Direct
  - Passes directly through posterior wall of inguinal canal, through defect in transversalis fascia, within Hesselbach's triangle
  - Can extend through inguinal canal into scrotum

## Approaches

- Anterior approaches for herniorrhaphy
  - Bassini repair: used for both direct and indirect herniorrhaphy, approximation of the conjoint tendon and transversalis fascia superior to the free edge of the inguinal ligament
  - Cooper's ligament (McVay) repair: approximation of the conjoint tendon and transversalis fascia above Cooper's (pectineal) ligament
  - Prosthetic repair: with mesh in large defect with wall tension

- Posterior (preperitoneal) approach
  - May be preferred for recurrent, strangulated, or complicated hernias
  - Transverse incision through external oblique aponeurosis and rectus sheath, separation of muscle layers, incision of transversalis fascia, opening of preperitoneal space
  - Peritoneum is separated from anterior abdominal wall and posterior inguinal canal.
  - Hernia is exposed and reduced, and the sac excised when appropriate.
- Laparoscopic approach
  - Indicated in recurrent or bilateral hernias
  - May be transabdominal or extraabdominal

### Femoral Hernia

- Passes through the femoral canal
- Deep to the iliopubic tract and inguinal ligament
- Medial to the femoral vein
- Lateral to the insertion of the iliopubic tract into the lacunar (Cooper's) ligament
- Hernial sac lies below inguinal ligament, in groin or superior thigh.
- More common in women

### Umbilical Hernia

- Usually congenital; small defects typically closed by age 2 years
- Early defects >2 cm or those persisting beyond age 4 years require repair.
- Acquired hernias: typically due to increased abdominal pressure in pregnancy, morbid obesity, ascites



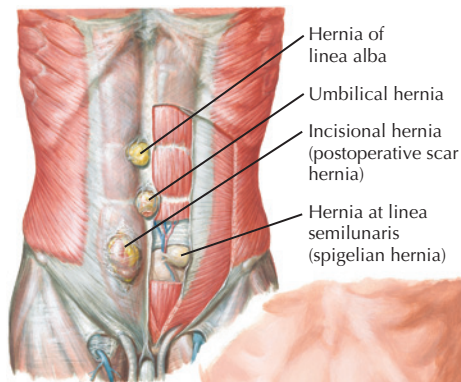
- Valsalva maneuver produces a reducible bulge; defect can be palpated.
- Rarely, can be confused with a lipoma or epigastric hernia
- Apparent lipoma may be incarcerated hernia
- Treatment: incision, reduction of hernial sac, and return of contents to abdominal cavity
- Heavy sutures for closure, prosthetic repair necessary for large defects
- Recurrence and complications uncommon

### Incisional Hernia

- Ventral: the great majority occur at site of a previous abdominal incision.
- Causes include clinical or subclinical wound infection, poor healing, ascites, malnutrition, pregnancy, chemotherapy, steroids, and strain on the wound.
- Fascial edges separate; hernia protrudes.
- Valsalva maneuver produces a bulge that reduces on expiration.
- Edges of the fascial defect can be palpated.
- High recurrence rate: contributing factors may need attention, including obesity, malnutrition, uncontrolled diabetes, steroids
- Unless factors interfere, repair is recommended at or near diagnosis.
- Open reduction usually involves opening the original incision.

### Rare Hernias

- Obturator hernia (OH)
  - Through the obturator canal into thigh adductor compartment with neurovascular bundle



Hernia of  
linea alba

Umbilical  
hernia

Incisional hernia  
(postoperative  
scar hernia)

Hernia at linea  
semilunaris  
(spigelian hernia)

*F. Netter  
M.D.*

## Abdominal Wall Hernias

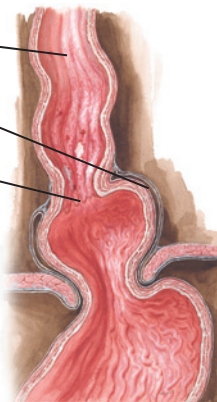
- OH most common in older women
- Difficult to diagnose, demonstrable on CT
- Parastomal hernia
  - Occurs through the same abdominal opening made for the ostomy
  - Might require relocation of ostomy or prosthetic repair of defect
- Spigelian hernia
  - Through the fascia between rectus and semilunar line
  - Narrow, may be interparietal, posterior to the external oblique aponeurosis
  - Reduced through a transverse incision over the hernia
- Lumbar hernia
  - Hernia through posterior abdominal wall in various locations
  - May be large
  - Repair through transabdominal approach
- Sciatic hernia
  - Extremely rare, through greater sciatic foramen
  - Can manifest with bowel obstruction
  - Requires transabdominal approach
- Perineal hernia
  - Through muscles and fascia of perineal (urogenital) diaphragm
  - May be congenital or acquired after perineal surgery
  - Transabdominal reduction

## Hiatal Hernias

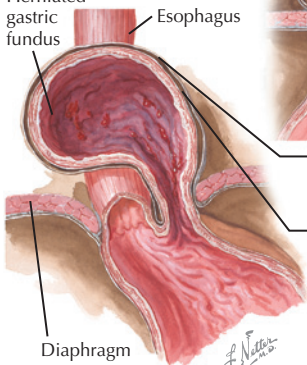
- For more information, in addition to the illustration that follows, turn to [page 196](#).

**Sliding hernia**

Esophagus

Peritoneal  
sacSquamo-  
columnar  
junction**Paraesophageal hernia**Herniated  
gastric  
fundus

Esophagus

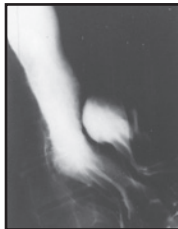Attenuated  
phrenoesophageal  
membrane

Peritoneal sac

Diaphragm

F. Netter  
M.D.

Barium study shows  
paraesophageal  
hiatal hernia.

**Hiatal Hernias**

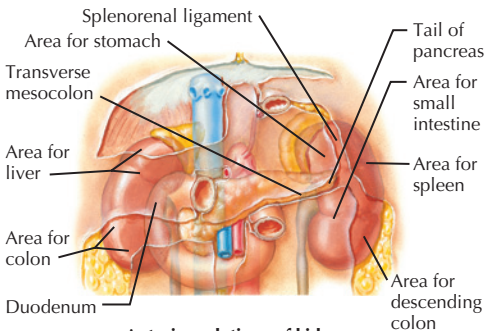
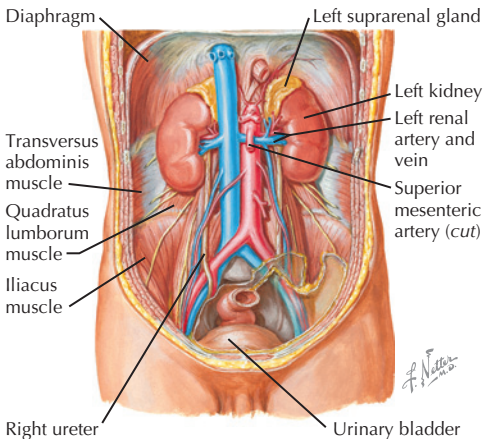
## ANATOMY OF THE KIDNEYS

### Position of the Kidneys

- Retroperitoneal, posterior to upper GI organs
- Lying on lateral borders of upper psoas muscles
- Kidneys and adrenals lie within perirenal (perinephric) fat that is enclosed by fibrous renal fascia (Gerota's).
- Retroperitoneal pararenal fat surrounds renal fascia.
- Parts of right kidney lie posterior to liver, duodenum, and right colic (hepatic) flexure.
- Right-dominant liver forces right kidney to lie lower than the left.
- Parts of left kidney lie posterior to stomach, tail of pancreas, spleen, and left colic (splenic) flexure.
- Upper parts of both kidneys overlie posterior inferior diaphragm.
- Right kidney also typically overlies quadratus lumborum, 12th rib, and transversus abdominis.
- Left kidney overlies quadratus lumborum, 11th and 12th ribs, and transversus abdominis.

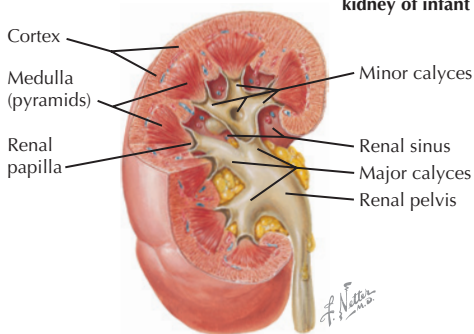
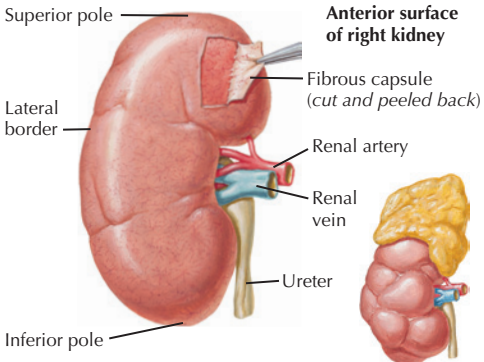
### Internal Renal Structure

- Renal capsule: fibrous, invests cortex, terminates around the rim of minor calyces in renal sinus



**Anterior relations of kidneys**

**Kidney in Situ**



**Right kidney sectioned in several planes, exposing parenchyma and renal pelvis**

**Gross Structure of Kidney**

- Cortex: contains Bowman's capsules and glomeruli (renal corpuscles), proximal and distal convoluted tubules, proximal collecting ducts, arcuate arteries and veins, cortical capillary plexus
- Medulla, pyramids: contain loops of Henle, distal collecting ducts, vasa rectae, medullary capillary plexus
- Renal (cortical) columns (Bertini): lie between pyramids, like cortex, contain renal corpuscles, tubules, and vessels
- Renal papilla: apex of pyramid, contains collecting tubule openings, drains into minor calyx

### Collecting System

- Minor calyces: collect urine from papillary tubules
- Major calyces: formed by union of 8-10 minor calyces
- Renal pelvis: formed by union of 2-4 major calyces, connects in turn to ureter

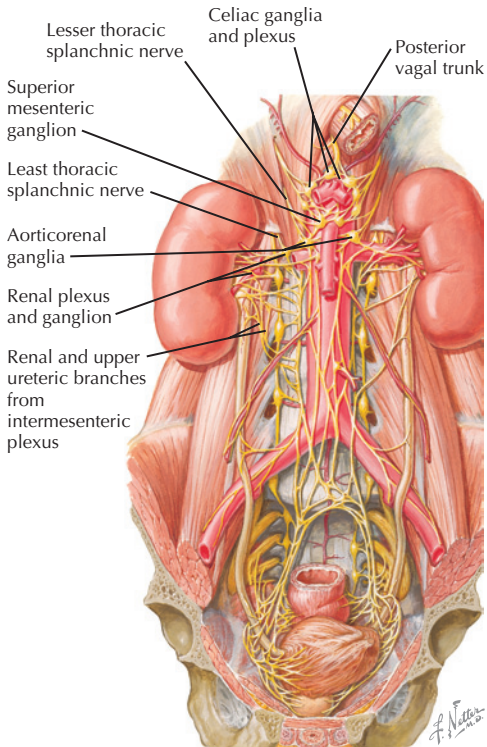
### Ureter

- Fibromuscular tube with mucosa
- Upper: renal pelvis to upper border of sacrum
- Middle: overlies sacrum
- Lower: border of sacrum to bladder
- Blood supply: upper from renal arteries, middle from ovarian or testicular arteries, lower from vesical arteries

### Innervation of Kidneys and Ureters

- Parasympathetic
  - Preganglionic: vagal fibers run through celiac and superior mesenteric plexuses, joining





Nerves of Kidneys, Ureters, and Urinary Bladder

renal nerve plexus for distribution to ganglion cells in renal parenchyma, pelvis, and ureter

- Sympathetic
  - Preganglionic: fibers run through splanchnic nerves (especially least), celiac, and superior mesenteric plexuses to synapse in aorticorenal ganglia.
  - Postganglionic: fibers distributed to smooth muscle of renal vessels and glomeruli
- Sensory
  - Segmental visceral afferent fibers run parallel to sympathetic fibers to dorsal root ganglia and spinal segments T11-L2.

## VESSELS AND LYMPHATICS

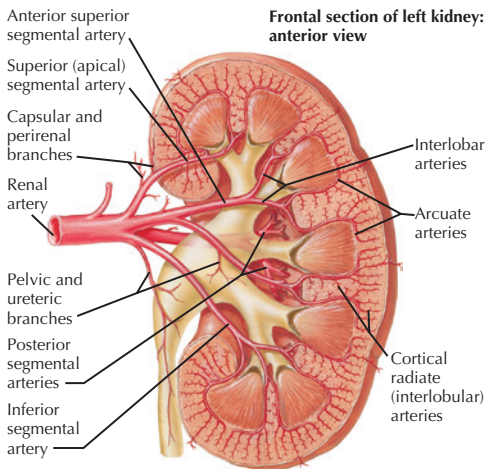
- Renal hilus: vessel entry and exit region

### Arterial Supply

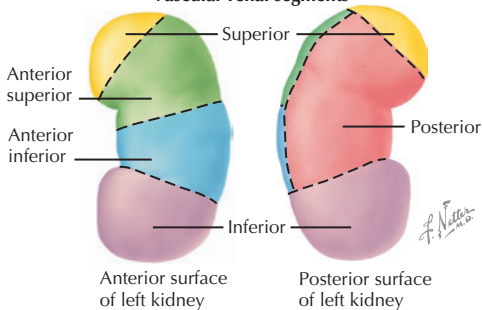
- Renal arteries are usually paired main branches on the right and left sides of abdominal aorta.
- Often variable, in up to 40% of cases
- Variations include accessory renal arteries (in addition to main) and pelvic branches with pelvic or horseshoe kidneys
- Renal artery branches at hilum typically lie posterior to renal veins and anterior to renal pelvis.

### Venous Drainage

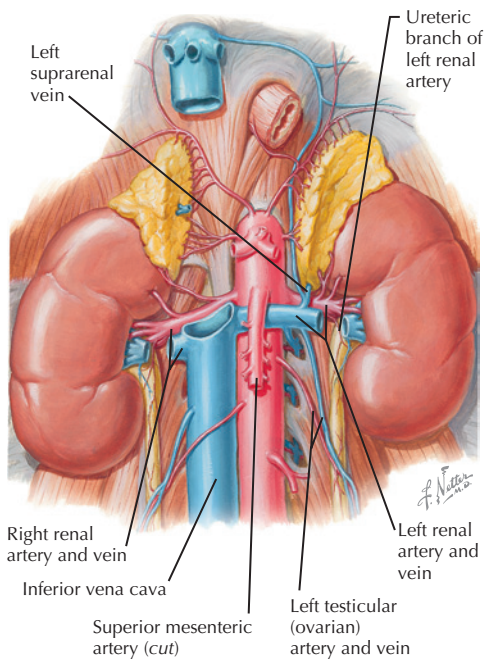
- Renal veins: usually single main branches, left and right, draining directly into the right-sided abdominal vena cava
- Long course of left renal vein passes anterior to aorta and under superior mesenteric artery (nutcracker configuration).



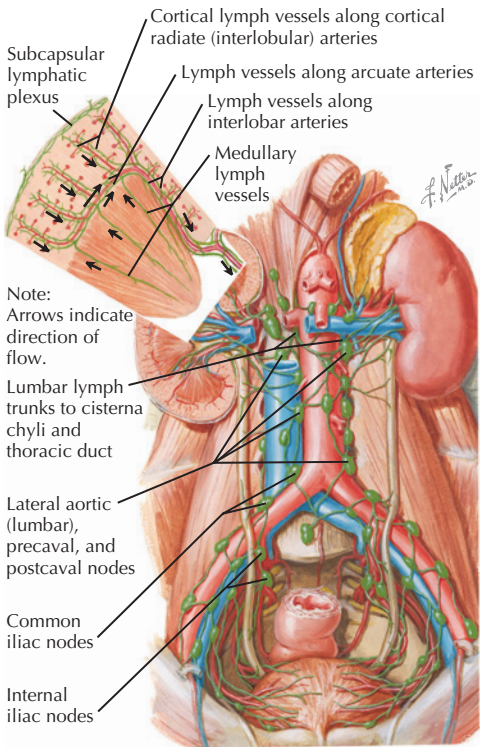
**Vascular renal segments**



**Intrarenal Arteries and Renal Segments**



Renal Artery and Vein in Situ



Lymph Vessels and Nodes of Kidneys

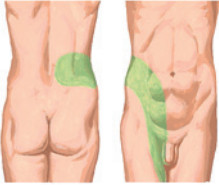
### Lymphatic Drainage

- Parenchymal, subcapsular, and perirenal plexuses drain into caval and aortic (lumbar) nodes.
- Lumbar nodes drain through lumbar lymphatic trunks into cisterna chyli.

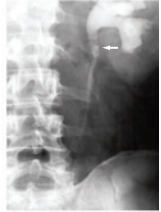## CLINICAL CORRELATES

### Stones

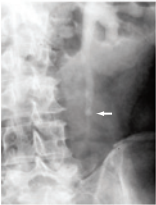- Symptoms: severe colicky pain and restlessness
- Urinalysis might demonstrate blood and stones.
- CT can demonstrate stones and hydronephrosis.
- Calcium oxalate (phosphate)
  - Most common (~75%) and radiopaque
  - Increased occurrence due to increased colonic uptake of oxalate in terminal ileum resection
- Magnesium ammonium phosphate (struvite) stones (~15%) are radiopaque and can occur with infections producing urease (e.g., *Proteus mirabilis*).
- Struvite stones can develop into staghorn calculi that fill renal pelvis.
- Uric acid stones (~7%)
  - Radiolucent
  - Increased incidence in patients with ileostomies, gout, and myeloproliferative diseases
- Cysteine stones (~2%)
  - Radiolucent to radiopaque
  - Associated with congenital disorders of cysteine reabsorption



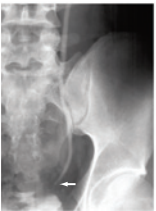Distribution of pain in renal colic



Ureteropelvic obstruction



Midureteral obstruction

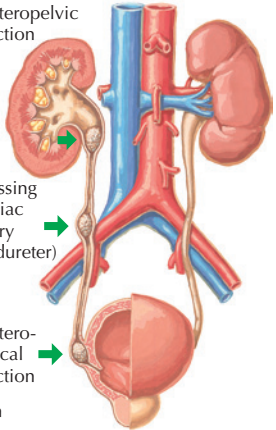


Distal ureteral obstruction

Ureteropelvic junction

Crossing of iliac artery (midureter)

Uretero-vesical junction

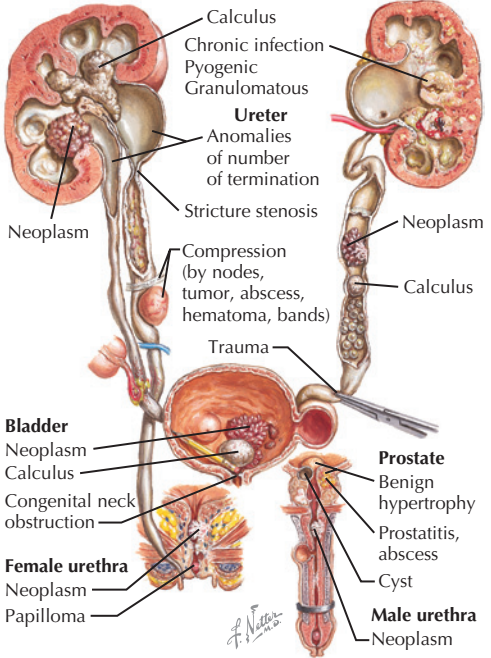


Common sites of obstruction

JOHN A. CRAIG MD

## Renal Stones

**Obstructive uropathy: etiology**



*F. Netter M.D.*

**Obstructive Uropathy**

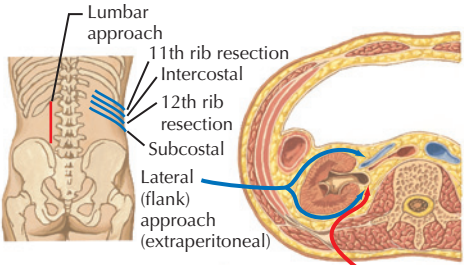


- Surgical indications: intractable infection or pain, progressive obstruction, progressive kidney damage, solitary kidney

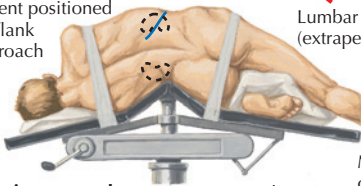
## Renal Cancer

- Renal cell carcinoma (hypernephroma): most common primary tumor
- Symptoms: abdominal pain, mass, hematuria
- About 15% calcified
- About 33% metastasized by time of diagnosis, to lung (most common) or colon
- Greatest risk factor: smoking
- Treatment
  - Radical nephrectomy
  - Selective radiation, chemotherapy, immunotherapy
  - Appropriate resection of metastases
- von Hippel–Lindau syndrome: recurrent renal cell cancer, cysts, pheochromocytomas, CNS tumors
- Nephroblastoma (Wilms' tumor)
  - Rare renal malignant tumor of early childhood: 8/million incidence
  - Manifests commonly as asymptomatic abdominal mass
  - Tumor cells produce renin, leading to hypertension.
  - Associated with hypospadias, cryptorchidism, ocular malformations
- Most common secondary renal tumor: breast metastasis
- Other neoplasms
  - Transitional cell cancer of renal pelvis
  - Angiomyolipomas
  - Oncocytomas

**Lumbar and lateral approaches**

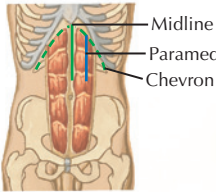


Patient positioned for flank approach

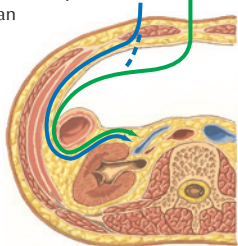


Lumbar approach (extraperitoneal)

**Anterior approaches**



Paramedian (extraperitoneal or transperitoneal)  
Midline or chevron (transperitoneal)



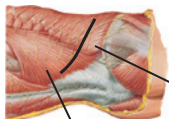
JOHN A. CRAIG MD

Surgical Approaches to the Kidney

## Surgical Approaches to the Kidneys

- Multiple different surgical approaches to kidneys: anterior, lateral or flank, lumbar or posterior, laparoscopic
- Lateral and posterior approaches are extraperitoneal.
- Preferred approach depends on disease, size and extent of lesion, obstruction, trauma, cancer or resection, and failure or transplant.
- Radical nephrectomy (typical treatment for renal cell carcinoma): resection of kidney, perinephric fat, Gerota's fascia
- Partial resection for solitary or for multiple or recurring tumors (e.g., von Hippel–Lindau syndrome)

*See next page*



**A.** Flank incision is made over the 12th rib.

External oblique muscle

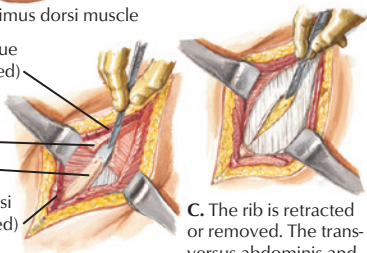
Latissimus dorsi muscle

External oblique muscle (divided)

Internal oblique muscle

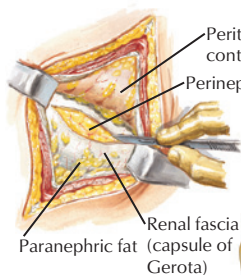
12th rib

Latissimus dorsi muscle (divided)



**B.** The skin, fat, and muscles are incised, exposing the 12th rib.

**C.** The rib is retracted or removed. The transverse abdominis and thoracolumbar fascia are incised.



Peritoneum and contents reflected

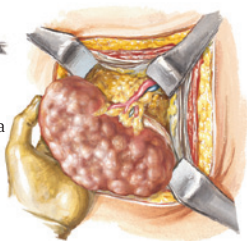
Perinephric fat

Renal fascia (capsule of Gerota)

Paranephric fat

*J. Netter M.D.*  
*E. Palancho CMH*

**D.** The peritoneum is reflected and left undisturbed. The paranephric fat is dissected to reveal the renal fascia, which is incised.



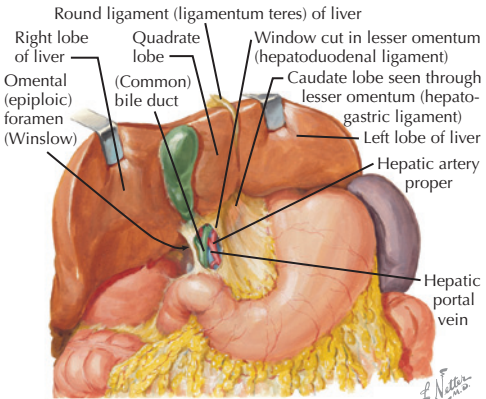
**E.** The renal hilum is exposed and then divided.

Simple and Radical Nephrectomy: Open Simple Nephrectomy (Flank Approach)

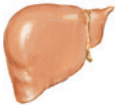## ANATOMY OF THE LIVER

### Basic Gross Anatomy

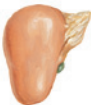- Liver develops in ventral mesogastrium, surrounded by peritoneum, except for bare area bounded by
  - Coronary ligament: peritoneal attachment to the inferior diaphragm
  - Left and right triangular ligaments, where coronary ligament reflects posteriorly
- Falciform ligament: remnant of ventral mesogastrium attaching to the abdominal wall
- Round ligament
  - Remnant of umbilical vein within the falciform ligament
  - Persisting venous connections may be present between liver/portal system and body wall.
- Hepatoduodenal ligament: peritoneal fold surrounding portal triad (hepatic artery proper, portal vein, bile duct), right edge of lesser omentum
- Omental foramen (of Winslow): posterior to hepatoduodenal ligament, opens into lesser (peritoneal) sac
- Lesser omentum (hepatogastric ligament) and posterior aspect of stomach form anterior wall of lesser (peritoneal) sac



**Variations in form of liver**



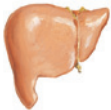Very small left lobe, deep costal impressions



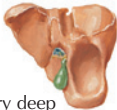Complete atrophy of left lobe (left portal vein compression)



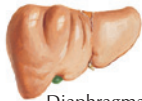
Transverse, "saddlelike" liver, relatively large left lobe



"Tonguelike" process of right lobe

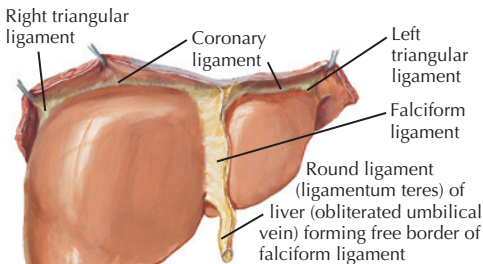


Very deep renal impression and "corset constriction"

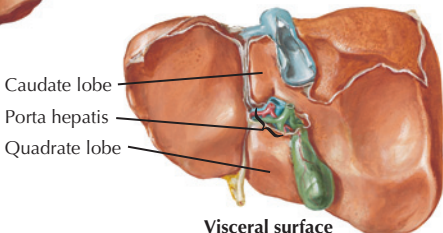


Diaphragmatic grooves

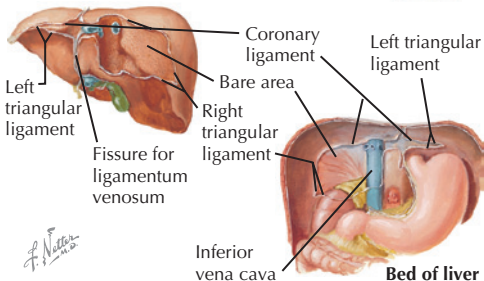
**Liver in Situ**



**Anterior view**



**Visceral surface**



**Bed of liver**

**Surfaces and Bed of Liver**

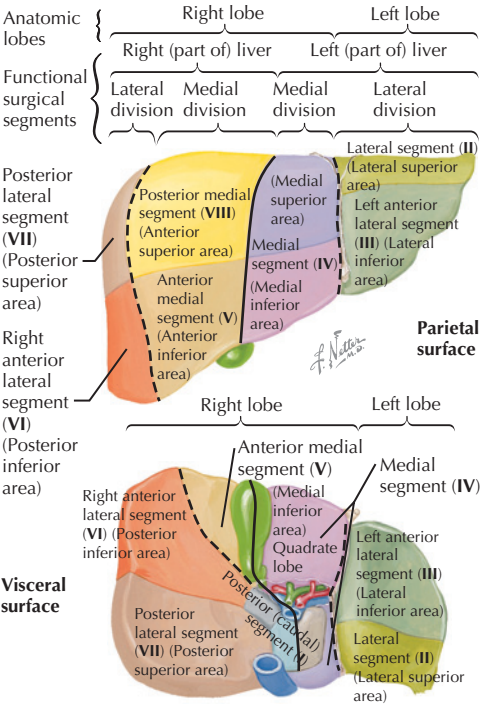
*F. Netter M.D.*

## Divisions

- Right and left hepatic lobes: divided by a plane extending from cystic fossa (anteroinferior) through inferior vena cava (superoposterior)
- Right lobe typically contains 50%-70% of total liver volume.
  - This is different from the historical view, dividing lobes by the falciform ligament.
- Each hemiliver contains its own hepatic artery branch, portal blood supply, venous drainage, and bile duct.
  - Basis for dividing the lobes without total vascular inflow occlusion
- Further division into 8 segments, resectable based on blood vessel and bile duct anatomy
  - Segment I: posterior, right and left caudate lobe
  - Segment II: left lateral division, left portal lobe, lateral segment (lateral superior)
  - Segment III: left lateral division, left portal lobe, left lateral anterior segment (lateral inferior area)
  - Segment IV: medial division, left portal lobe, medial segment (medial inferior area, quadrate lobe)
  - Segment V: right medial division, right portal lobe, left anterior medial segment (anterior inferior area)
  - Segment VI: right lateral division, right portal lobe, lateral segment (posterior inferior)
  - Segment VII: right lateral division, right portal lobe, posterior lateral segment (posterior superior)



Division into segments is based upon ramifications of bile ducts and hepatic vessels. It does not entirely correspond with division into anatomic lobes.



Liver Segments and Lobes

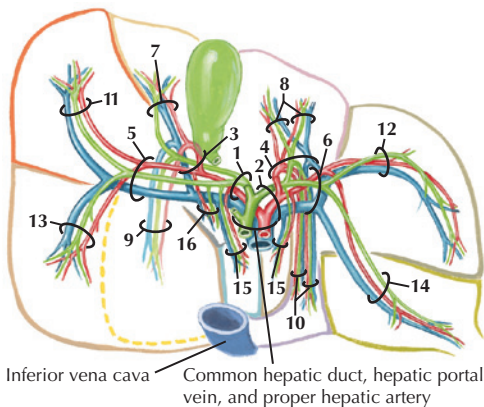
- Segment VIII: right medial division, right portal lobe, posterior medial segment (anterior superior area)

### Portal Triads and Bile Duct System

- Portal triads—hepatic artery, bile duct, and portal vein branches—and lymphatics seen in characteristic relationships from microscopic (lobular) to macroscopic (lobar) levels
- Popular functional concepts of liver parenchyma include classic lobules and liver acini organized around vessels.
- Interlobular *portal vein* branches travel in interlobular septum on periphery of hepatic lobules.
- Interlobular *hepatic artery* branches travel alongside portal veins in septa, providing smaller branches to ducts and parenchyma (hepatocytes) of lobules.
- Interlobular *bile duct* branches receive bile canaliculi draining lobular parenchyma.
- *Central veins* in the middle of lobules drain into hepatic vein tributaries.
- Sinusoids are formed by plates of hepatocytes surrounding lobular central veins.

### Innervation of the Liver

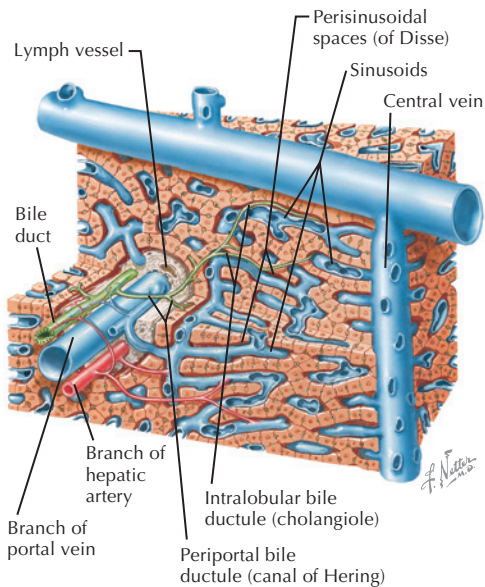
- Visceromotor control of human liver parenchyma and intralobular biliary ductules
  - Incompletely understood
  - Efferents involved in regulation of portal blood flow, bile flow, regeneration of parenchyma, metabolism of lipids, carbohydrates, and plasma proteins
- Hepatic plexus (around the hepatic artery proper) is largest branch of celiac plexus.



### Distribution of vessels and ducts

- 1 Right branch
- 2 Left branch
- 3 Anterior segment
- 4 Medial segment
- 5 Posterior segment
- 6 Lateral segment
- 7 Anterior inferior area
- 8 Medial inferior area
- 9 Anterior superior area
- 10 Medial superior area
- 11 Posterior inferior area
- 12 Lateral inferior area
- 13 Posterior superior area
- 14 Lateral superior area
- 15 Caudate lobe  
(right and left)
- 16 Caudate process

### Liver Vessel and Duct Distribution



Liver Structure Schema

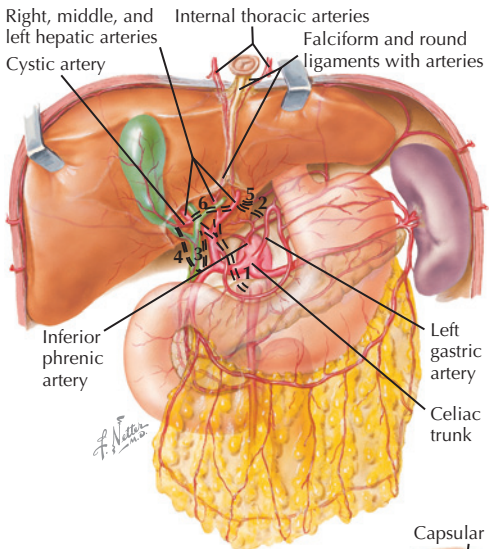
- Parasympathetic: vagus
  - Preganglionic fibers from anterior and posterior vagal trunks distributed via celiac plexus to intrahepatic ganglion cells
  - Postganglionic fibers associated with intralobular parenchyma

- Sympathetic
  - Preganglionic fibers from intermediolateral columns of T7-T10 segments via splanchnic nerves to celiac ganglion
  - Postganglionic fibers from celiac ganglion cells to smooth muscle of interlobular blood vessels and ductules
- Afferent
  - Segmental visceral afferents
    - ▲ Travel back via splanchnic nerves to dorsal root ganglia and thoracic spinal segments T7-T10
    - ▲ Mediate pain and reflexes
  - Vagal afferents
    - ▲ Ganglion cells in nodose (inferior vagal) ganglion
    - ▲ Involved in hepatic regulatory mechanisms
  - Phrenic nerves: mediate some pain
  - Pain diffusely mapped
- Parasympathetic, sympathetic, and afferent fibers distributed with blood vessel branches to intralobular tissues

## VESSELS AND LYMPHATICS

### Arterial Supply

- Branches highly variable
- Celiac artery branches
  - Common hepatic artery
    - ▲ Hepatic artery proper, right and left hepatic arteries
    - ▲ Right gastric artery
    - ▲ Gastroduodenal artery
  - Left gastric artery



### Accessory or replaced arteries

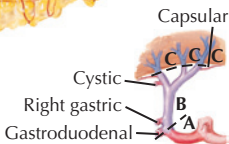
1. Right or common hepatic
2. Left hepatic
3. Right hepatic
4. Cystic

### Anastomoses of corresponding arteries

5. Inferior phrenic/left gastric ↔ left hepatic
6. Right ↔ left hepatic

**Effects of hepatic artery obstruction** {

- A. Zone of relative safety
- B. Zone of questionable effects
- C. Zone of inevitable infarction



### Celiac Artery Variations and Collateral Supply of Liver

- Right hepatic artery arises from superior mesenteric artery in 10%-20% of patients.
- Left hepatic artery arises from left gastric artery in ~10% of patients.
- Rarely, common hepatic artery arises from superior mesenteric artery.

### Portal Venous Supply

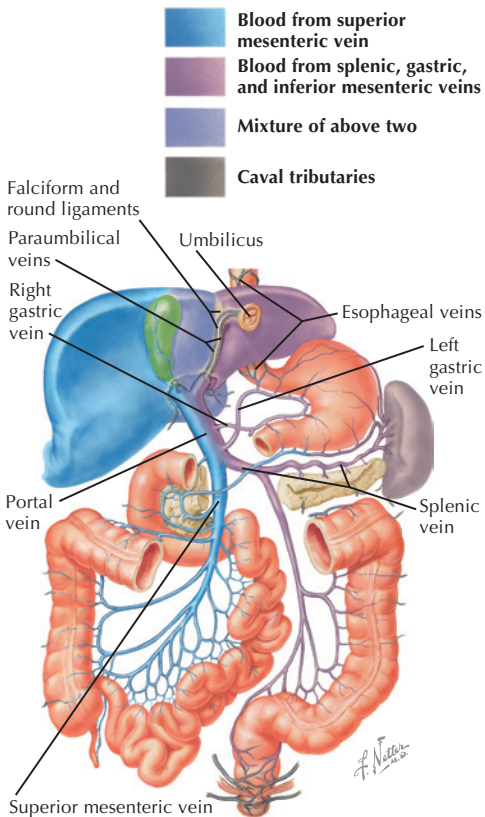
- Contains no valves
- Formed by confluence of superior mesenteric vein (right portal) with splenic and inferior mesenteric veins (left portal)
- Right-left juncture usually occurs within hepatoduodenal ligament.
- Left portal drainage goes toward left (hemi) liver, from distal esophagus, lesser curvature of the stomach, spleen, body and tail of the pancreas, and distal half of colon.
- Right portal drainage goes toward right (hemi) liver, from duodenum, head of pancreas, jejunum, ileum, and first half of colon.
- Right- and left-sided drainage typically mixes in quadrate and caudate lobes.

### Hepatic Venous Drainage

- Central veins of lobules drain into tributaries of hepatic veins.
- Intrahepatic right and left hepatic veins empty directly into inferior vena cava.

### Lymphatic Drainage

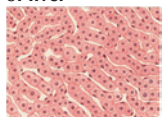
- Posterior aspect of the liver drains toward phrenic nodes on centromedial inferior diaphragm or directly through caval hiatus to mediastinal nodes.



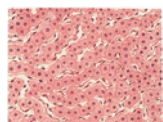
Hepatic Portal Vein Tributaries, Portocaval Anastomoses



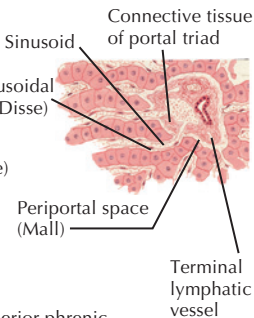
**Low-power sections of liver**



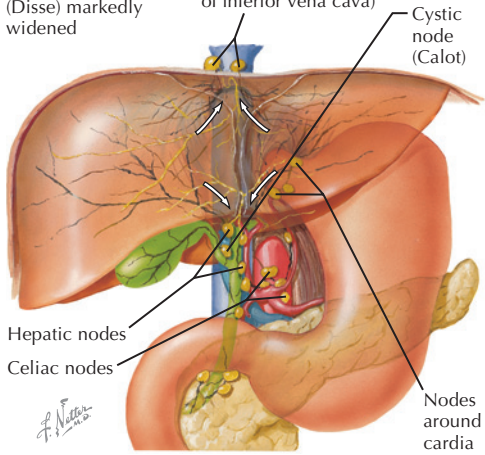
Perisinusoidal spaces (Disse) very narrow or obliterated



Perisinusoidal spaces (Disse) markedly widened



Superior phrenic nodes (at termination of inferior vena cava)



*F. Netter M.D.*

**Lymph Vessels and Nodes of Liver**

- Anterior lymphatic drainage flows toward porta hepatis, emptying to hepatic nodes clustered around hepatic artery.
- Hepatic and mediastinal nodes drain toward cisterna chyli and thoracic duct.

## CLINICAL CORRELATES

### Liver Functions

- Largest compound gland, principal metabolic and detoxification organ
- Hepatocytes synthesize glycogen from glucose and store and break down glycogen as needed.
- Liver synthesizes albumen (transport agent and osmotic agent in serum).
- Liver disease can lead to low serum albumen level and loss of water into peritoneal cavity (ascites).
- Liver secretes glucose, plasma proteins, and lipoproteins.
- Liver secretes bilirubin, immunoglobulin A (IgA), and bile salts.

### Liver Trauma

- Organ most often involved in blunt and penetrating abdominal trauma
- Blunt trauma might not require surgical management.
- Penetrating trauma: surgery is the standard of care

### Benign Tumors

- Cavernous hemangioma
  - Common autopsy finding, may be >1% occurrence

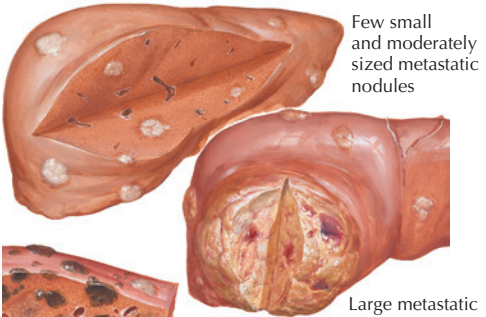
- More common in women >30, but can be found in any age group or sex
- Focal nodular hyperplasia (a.k.a. focal cirrhosis): second most common benign solid tumor
- Hepatic adenoma

## Malignant Tumors

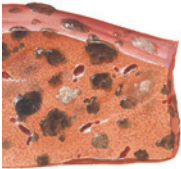- Primary lesions
  - Hepatocellular carcinoma
    - One of the most common malignancies worldwide
    - Associated most strongly with chronic viral hepatitis
    - Usually occurs with cirrhosis
- Metastatic lesions
  - More common than primary tumors in the rest of the world
  - Virtually any primary tumor can metastasize to liver.
  - Only colorectal and some pancreatic islet carcinomas typically make resectable tumors.
  - Carcinoid and leiomyosarcoma tumors can also be resectable.

## Cirrhosis and Liver Failure

- Cirrhosis is most common cause of liver failure.
- Mechanism of cirrhosis: hepatocyte destruction → fibrosis and scarring → venous hypertension → portal venous congestion → lymphatic overload → lymph leakage and ascites
- Prothrombin time is best indicator of synthetic function.
- Hepatic encephalopathy: metabolic deficit leads to buildup of ammonia, methane thiols, mercaptans, and false neurotransmitters



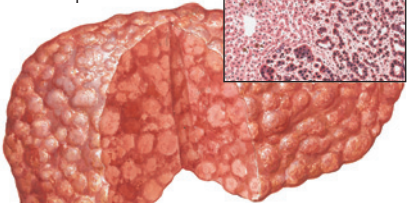
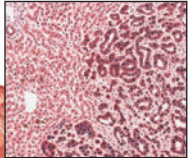
Few small and moderately sized metastatic nodules



Metastases to liver of malignant melanoma

Large metastatic nodule—also smaller nodules

Invading metastatic cancer compressing hepatic cells

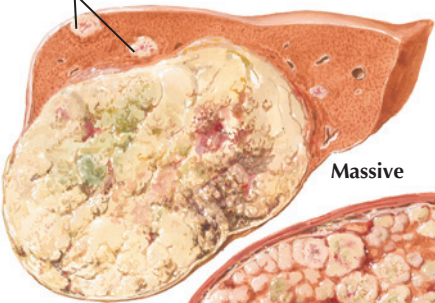


Diffusely invading multiple metastases ("hobnail" effect on palpation)

*F. Netter M.D.*

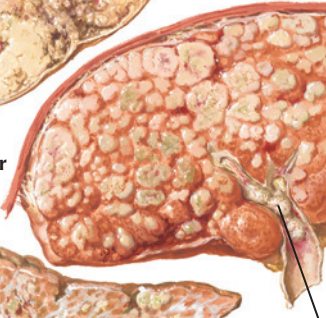
Tumors, Secondary and Metastatic

Daughter nodules



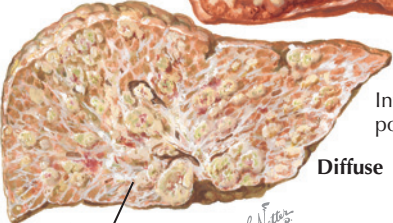
**Massive**

**Nodular**



Invasion of portal vein

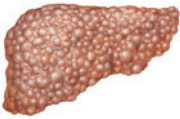
**Diffuse**



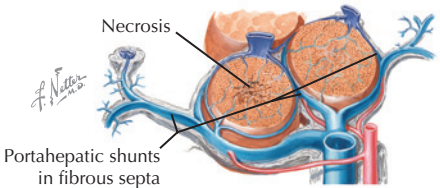
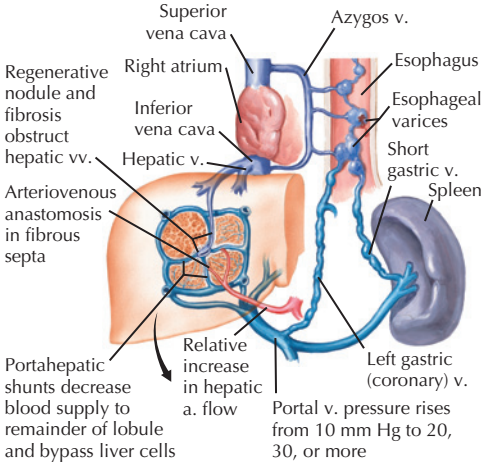
Cirrhosis

*F. Netter M.D.*

**Primary Hepatic Carcinoma**



Regular formation of small nodules and thin septa, characteristic of Laënnec's cirrhosis



Cirrhosis

- Increased aldosterone, secondary to impaired metabolism and low glomerular filtration rate
- Peritoneovenous shunts (LeVeen, Denver) used to drain ascites fluid into venous system

## Abscesses

- Historically challenging to treat
- Pyogenic (bacterial)
  - Predisposing: biliary diseases or infections in areas with portal drainage (appendicitis, diverticulitis, perforating neoplasms)
  - Less common causes: bacteremic seeding, trauma, chronic suppurative infections
  - Ultrasound and CT offer high diagnostic accuracy.
  - Principles of treatment
    - ▲ Abscess drainage
    - ▲ Percutaneous with ultrasound or CT
    - ▲ Approaching effectiveness of open surgical drainage
  - 8%-22% mortality in recent series
  - Complications: rupture into adjacent structure, dissemination, and multiorgan failure
- Amebic: *Entamoeba histolytica*
  - Emigration from or travel through region with endemic amebic disease
  - Ingested cysts break down to form mobile trophozoites.
  - Trophozoites inhabit colon or its wall.
  - Liver invaded via portal drainage, with necrosis and abscess formation
  - Ultrasound may be diagnostic (>90%), with no need for CT.

- Serologic test for *E. histolytica* antibodies confirms diagnosis.

## Hemobilia

- Gastrointestinal hemorrhage secondary to biliary tract bleeding
- Occurs from sites in biliary system, from liver parenchyma through other locations in duct system and gallbladder
- Trauma, infection, or tumor can cause hemorrhage into biliary tree.
- Trauma and iatrogenic injury are common causes in the U.S. (biopsy, stents, ERCP [see [Chapter 10, Biliary Diseases](#)]).
- May be massive or minimal, depending on source, etiology



# 16 Pancreatic Diseases

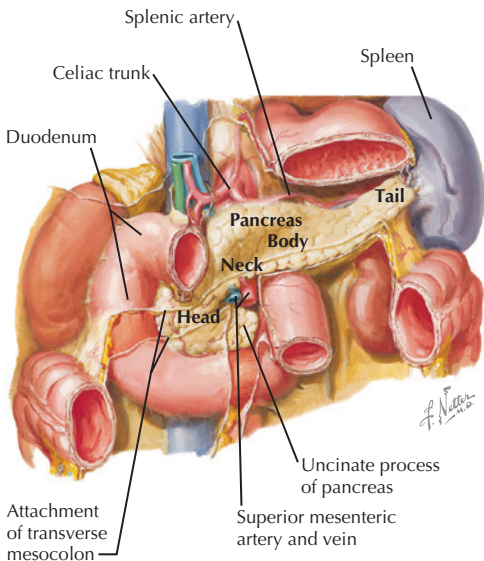
## ANATOMY OF THE PANCREAS

### Parts and Landmarks

- Head (includes uncinate process), neck, body, tail
- Uncinate process lies behind superior mesenteric artery and anterior to aorta.
- Neck overlies superior mesenteric artery and vein and portal vein.
- Development
  - Two endodermal gland buds of caudal foregut merge to form pancreas.
  - Buds rotate with foregut.
  - Dorsal bud forms body and tail.
  - Ventral bud makes head; uncinate process rotates behind superior mesenteric artery.
  - Original mesentery fuses with posterior peritoneum, and pancreas becomes retroperitoneal.

### Location and Locale of the Pancreas

- Retroperitoneal and posterior to stomach: typically nonpalpable on physical examination
- Neck of pancreas overlies L1 and L2 vertebral bodies in the transpyloric plane.
- Head is to the right of and inferior to transpyloric plane.
- Body and tail are to the left and above transpyloric plane.



Pancreas in Situ

## Duct System

### Main Pancreatic Duct

- Begins in tail, runs medially into head
- Turns inferiorly, closely related to bile duct
- Ducts unite to form hepatopancreatic ampulla (of Vater).
- Ampulla empties into descending duodenum at the major duodenal papilla.

- Smooth muscle sphincter of pancreatic duct around terminal portion
- Smooth muscle sphincter lies around terminal bile duct.
- Hepatopancreatic sphincter (of Oddi) around hepatopancreatic ampulla

#### *Accessory Pancreatic Duct (Variable)*

- Can open into duodenum at minor duodenal papilla
- Accessory duct more often joins main duct (~60%).
- If main duct is small, and there is no juncture, accessory duct can carry majority of secretion.

#### **Functional Anatomy**

- Tubuloacinar gland structure with a variety of cell types, including intermingled islets of Langerhans
- Parasympathetic and sympathetic nerves are distributed to islets and acini.
- Cells' secretions are controlled by endocrine and autonomic nervous activities.

#### *Exocrine Functions*

- Mediated by secretin and cholecystinin formed by duodenal and jejunal epithelium
- Acinar cells secrete amylase, lipase, trypsinogen, chymotrypsinogen, carboxypeptidase, and  $\text{Cl}^-$ .
- Ductal cells secrete  $\text{HCO}_3^-$ .
- Some secretomotor input comes from vagal parasympathetic fibers.

#### *Endocrine Functions*

- *Alpha cells* secrete glucagon.
- *Beta cells* (central islets) secrete insulin.

- *Delta cells* secrete somatostatin.
- F or PP cells secrete pancreatic polypeptide.
- Islet cells also produce vasoactive intestinal peptide (VIP), serotonin, neuropeptide Y, and gastrin releasing peptide (GRP).

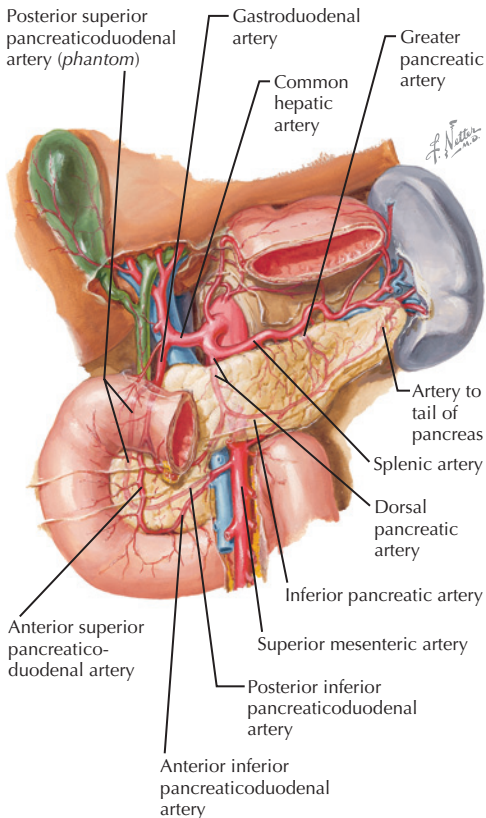
### Innervation

- Both parasympathetic and sympathetic efferent fibers are distributed to islets.
- Parasympathetic: vagus
  - Preganglionic fibers from left and right vagal trunks distributed through celiac plexus
  - Postganglionic: ganglion cells associated with ductal smooth muscle, islets, acini
- Sympathetic fibers
  - Preganglionic from T7-T10 segments, distributed via splanchnic nerves to celiac ganglion
  - Postganglionic fibers distributed through celiac plexus along arterial branches
  - Terminations on vascular smooth muscle, islets, acini

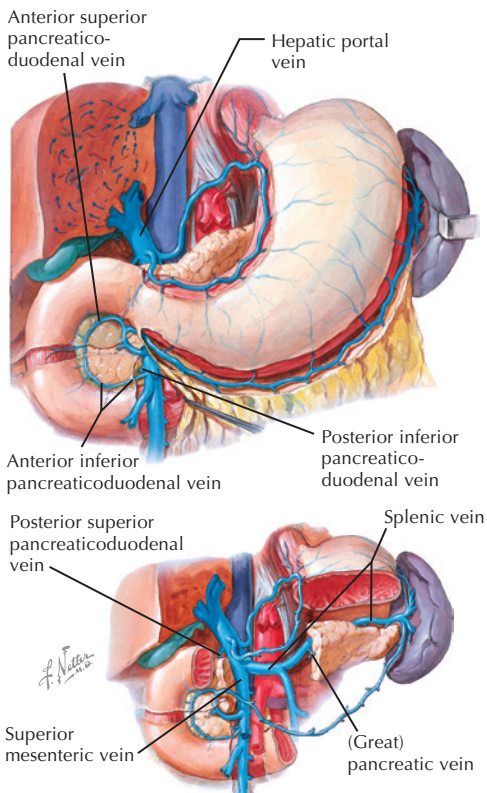
## VESSELS AND LYMPHATICS

### Arterial Supply

- Head supplied by anterior and posterior branches of superior and inferior pancreaticoduodenal arteries, branches (respectively) of the *gastro-duodenal (celiac axis)* and superior mesenteric arteries
- Body supplied by great, inferior, and caudal pancreatic arteries and branches of splenic artery
- Tail supplied by splenic, gastroepiploic, and dorsal pancreatic arteries
- Greatest blood flow to islet cells, then acini



Arteries of Liver, Pancreas, and Spleen



Veins of Stomach, Pancreas, and Spleen

## Venous Drainage

- Into portal system by numerous branches, great pancreatic vein and others, draining first into splenic vein (left portal)
- Superior and inferior pancreaticoduodenal veins from head and neck region drain into superior mesenteric vein (right portal).

## Lymphatic Drainage

- Nodes on surface and borders drain into celiac and superior mesenteric nodes.
- Upstream drainage into cisterna chyli and thoracic duct

## CLINICAL CORRELATES

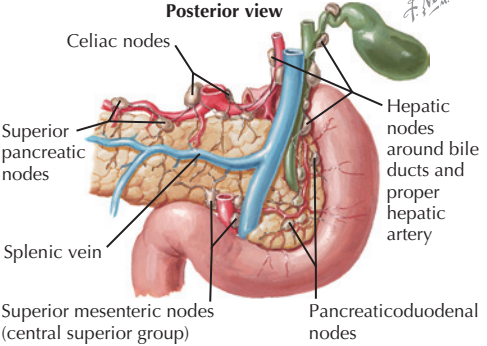
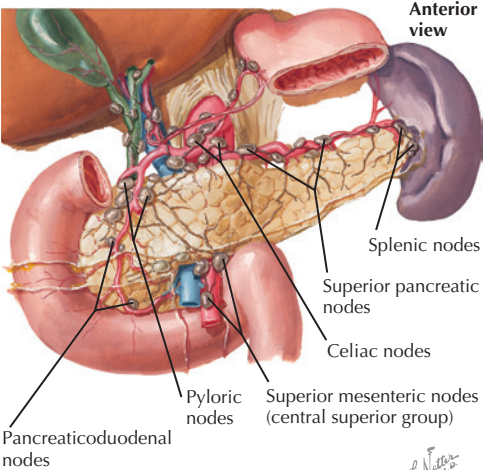
### Pancreatitis

#### Acute

- Stones and alcohol consumption most common causes in U.S.
- Other causes include
  - Endoscopic retrograde cholangiopancreatography (ERCP [[Chapter 10, Biliary Diseases](#)]), trauma
  - Hyperlipidemia, hypercalcemia, medications
  - Viruses and *Ascaris lumbricoides* and *Cephalotaxus sinensis* parasitism
- Symptoms: abdominal pain radiating to back, nausea, vomiting, anorexia
- 10% mortality, 50% for hemorrhagic
- No apparent cause? Cancer a concern

#### Chronic

- Associated with irreversible parenchymal fibrosis



Lymph Vessels and Nodes of Pancreas



- Chronic alcohol consumption most common cause of chronic pancreatitis, idiopathic 2nd
- Exocrine tissue calcified/fibrotic, islets spared
- Advanced disease: lakes, dilations, and stenoses in duct(s)
- Pain most common, with anorexia, weight loss, malabsorption, steatorrhea, recurrent acute pancreatitis
- Diagnosis
  - CT shows calcifications and atrophy.
  - Ultrasound shows dilated ducts, cysts, and atrophy.
  - ECRP is very sensitive for chronic disease.

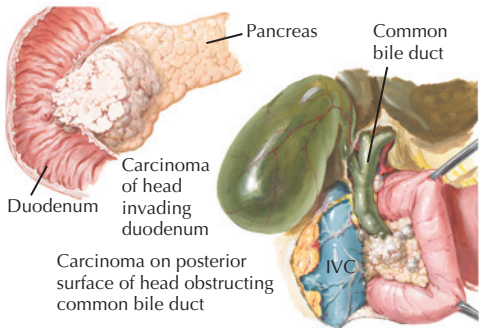
## Pancreatic Cancer

### *Adenocarcinoma*

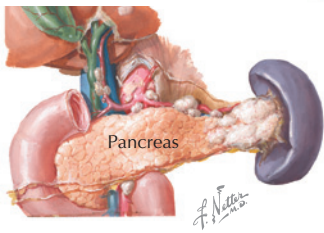
- Predominantly male disease
- Typically found in 6th or 7th decade
- Most common symptoms: weight loss, jaundice, pain
- Most common risk factor: tobacco use
- ~20% survival rate at 5 years with resection
- Lymphatic spread usually occurs first.
- About 70% in head of pancreas
- 90% ductal adenocarcinoma

## Endocrine Neoplasms

- Functional endocrine pancreatic tumors represent 2/3 of endocrine neoplasms; 1/3 are nonfunctional.
- Most common in pancreatic head
- Tumors respond to debulking.
- Liver most common site of metastasis for all types



Carcinoma on posterior surface of head obstructing common bile duct



Carcinoma of tail adherent to spleen, metastases to lymph nodes and liver

**Metastases from pancreas**

Most common sites:

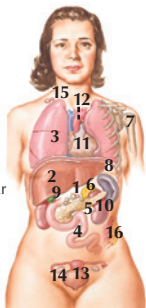
1. Regional nodes
2. Liver
3. Lung and pleura
4. Intestine
5. Peritoneum

Moderately common sites:

6. Adrenal
7. Bone
8. Diaphragm
9. Gallbladder
10. Kidney

Occasional sites:

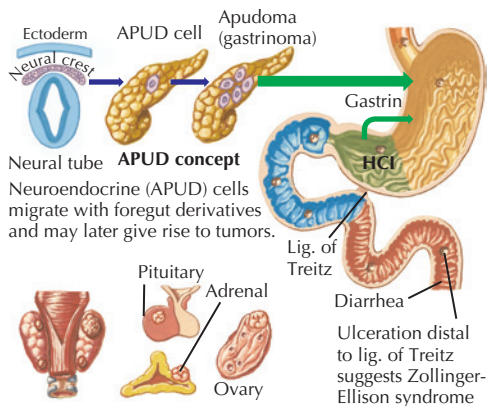
11. Heart
12. Mediastinum
13. Bladder
14. Ovary
15. Supraclavicular nodes
16. Muscle or subcutaneous tissue



**Carcinoma of Pancreas**

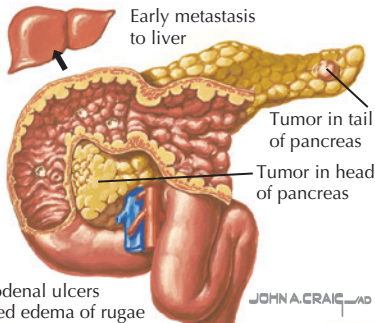
- 5 fluorouracil (5-FU) and streptozocin chemotherapy work well for all.
- Insulinoma
  - Most common islet cell tumor, >85% benign
  - Symptoms (Whipple's triad): fasting hypoglycemia, hypoglycemic symptoms (catechol surge, elevated heart rate, sweating), relieved by glucose
- Gastrinoma (Zollinger-Ellison syndrome: see next page)
- Somatostatinoma
  - Very rare, most are malignant
  - Symptoms: diabetes, gallstones, steatorrhea, hypochlorhydria
  - Most common in head
- Glucagonoma
  - Most are malignant.
  - Symptoms: diabetes, weight loss, stomatitis, dermatitis
- VIPoma (Werner-Morrison syndrome)
  - Most are malignant.
  - Symptoms: diarrhea, hypokalemia, achlorhydria

*See next page*



Multiple endocrine neoplasia may be associated with Zollinger-Ellison syndrome.

Marked gastrin secretion by tumor results in gastric acid hypersecretion independent of antral gastrin secretion.



### Zollinger-Ellison Syndrome

# 17 Small Intestine Diseases

## ANATOMY OF THE SMALL INTESTINE

### Duodenum

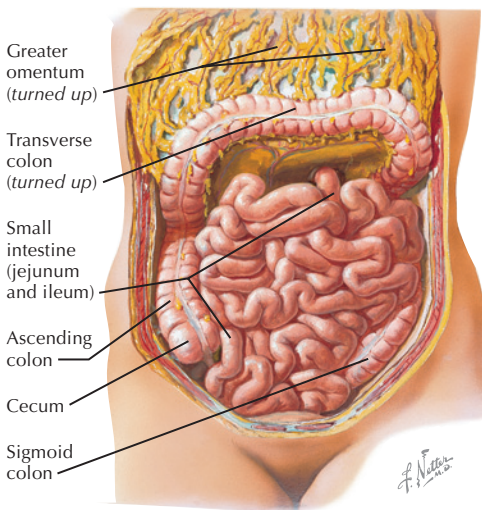
- See [Chapter 12, Gastroduodenal Diseases](#).

### Jejunum

- 40% of small intestine
- Few large vascular arcades (loops)
- Long vasa recta
- Large, tall, and closely packed plicae circulares
- Less fat in mesentery than ileum
- Locus of maximum water (90%) and nutrient absorption, except for B<sub>12</sub>, bile acids, iron, and folate
- 95% of water absorbed

### Ileum

- 60% of small intestine
- Many small vascular arcades (loops)
- Short vasa recta
- Large, low, and sparse plicae circulares, none distal
- More fat in mesentery than jejunum
- Maximum absorption of nonconjugated bile acids, with conjugated bile acids absorbed in terminal ileum
- B<sub>12</sub> and folate maximally absorbed in terminal ileum



Greater Omentum and Abdominal Viscera

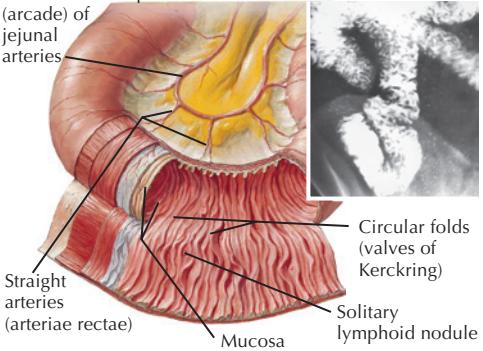
### Microscopic Anatomy

- Mucosa
  - Epithelium: enterocytes (absorptive), goblet cells, Paneth cells, enterochromaffin cells
  - Lamina propria: contains Peyer's patches
    - ▲ Lymphoid aggregations with B cells in germinal centers and T cells in interfollicular zones
    - ▲ Densest patches are in ileum.
  - Muscularis mucosa

## Jejunum

Anastomotic loop  
(arcade) of  
jejunal  
arteries

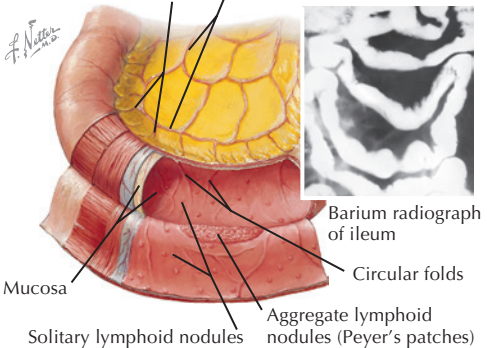
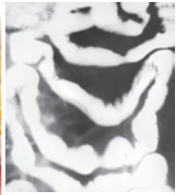Barium radiograph  
of jejunum



## Ileum

Straight arteries  
(arteriae rectae)

Anastomotic loops  
(arcades) of ileal arteries



Jejunum and Ileum: Mucosa and Musculature

- Submucosa: strongest layer, connective tissue, Meissner's plexus (parasympathetic ganglion cells and neuronal network)
- Muscularis
  - Inner circular muscle
  - Outer longitudinal layer
  - Auerbach's plexus: myenteric neurons and parasympathetic ganglion cells
- Serosa: peritoneum
- Mucosal surface area specializations: microvilli, villi, plica circulares (valvulae conniventes)
- Total absorptive surface for water and nutrient transfer: 200-550 cm<sup>2</sup>
- Water and nutrients absorbed across mucosa

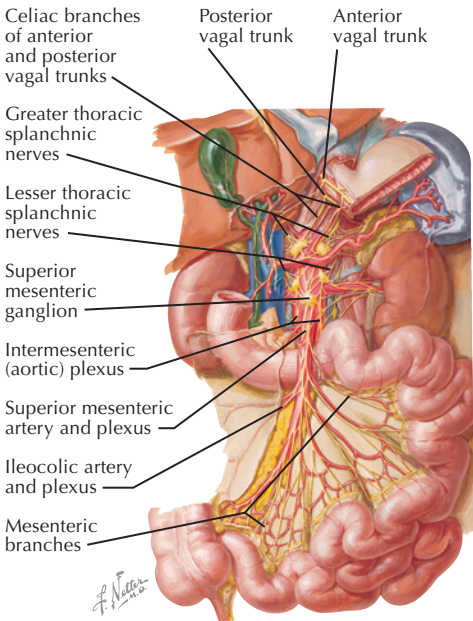
### Endocrine Gut Functions

- Cholecystokinin (CCK): secreted by cells of proximal intestine
- Secretin: secreted by S cells of proximal intestine
- Motilin: secreted by M cells of proximal intestine
- Somatostatin (SMS): secreted by D cells throughout gut
- Peptide YY (PYY): secreted by L cells of distal intestine
- Glucagon-like peptide 2 (GLP-2): secreted by L cells of distal intestine

### Innervation

- Parasympathetic: vagus
  - Preganglionic fibers: posterior branches of right and left vagus distributed through celiac and superior mesenteric plexus





### Nerves of Small Intestine

- Ganglion cells are located in myenteric (Auerbach's) and submucosal (Meissner's) plexuses.
- Sympathetic
  - Preganglionic fibers from T8-T10 lateral column distributed via splanchnic nerves to celiac and superior mesenteric ganglia

- Postganglionic fibers distributed through celiac and superior mesenteric plexuses along arterial branches
- Sensory fibers, general visceral afferent
  - Vagal afferents distributed through celiac and superior mesenteric plexuses
  - Segmental afferents travel back (parallel to sympathetics) through celiac and superior mesenteric plexuses and splanchnic nerves to dorsal root ganglia and thoracic spinal cord segments.

## VESSELS AND LYMPHATICS

### Arterial Supply

#### *Celiac Artery Branches*

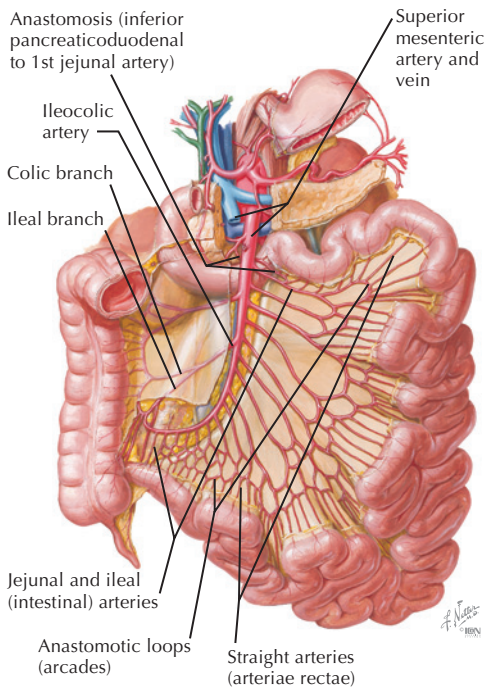
- Common hepatic artery
  - Gastrooduodenal artery
    - ▲ Superior pancreaticoduodenal artery: to duodenum proximal to bile duct
    - ▲ Anastomoses with inferior pancreaticoduodenal

#### *Superior Mesenteric Artery Branches*

- Inferior pancreaticoduodenal artery (duodenum distal to bile duct); anastomoses with superior pancreaticoduodenal
- Jejunal branches
- Ileal branches
- Ileocolic artery (with appendiceal branch)
- Arcades link adjoining jejunal and ileal branches.
- Vasa rectae connect from arcades to bowel walls.

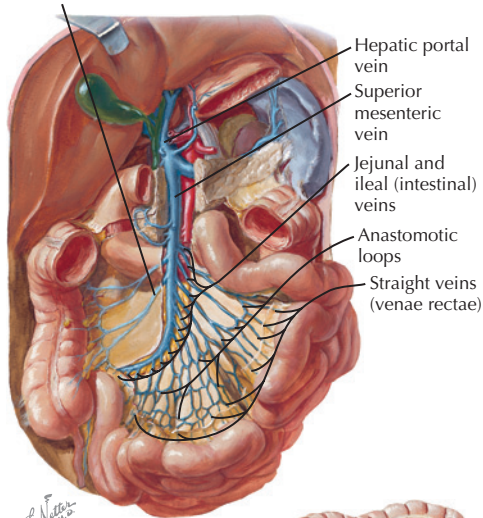
#### *Marginal Artery*

- Connects superior and inferior mesenteric arteries



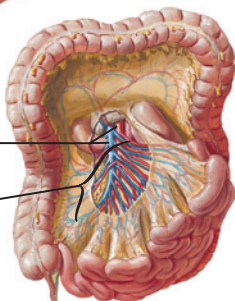
Arteries of Small Intestine

Ileocolic vein



Superior mesenteric artery and vein

Jejunal and ileal (intestinal) vessels



**Relations of superior mesenteric vein and artery in root of mesentery**

Veins of Small Intestine

## Venous Drainage

- Duodenal veins empty into splenic vein, superior mesenteric vein, and portal vein (which lies posterior to the first part).
- Superior mesenteric vein (right portal drainage) receives jejunal, ileal, and ileocolic veins that run alongside of arterial counterparts.

## Lymphatic Drainage

- *Peyer's patches* occur in greater numbers in more distal small bowel (e.g., ileum).
- Peyer's patches and intraluminal vessels drain into mesenteric nodes clustered around branches of superior mesenteric artery.
- Deeper drainage flows superiorly into nodes along aorta and into cisterna chyli.

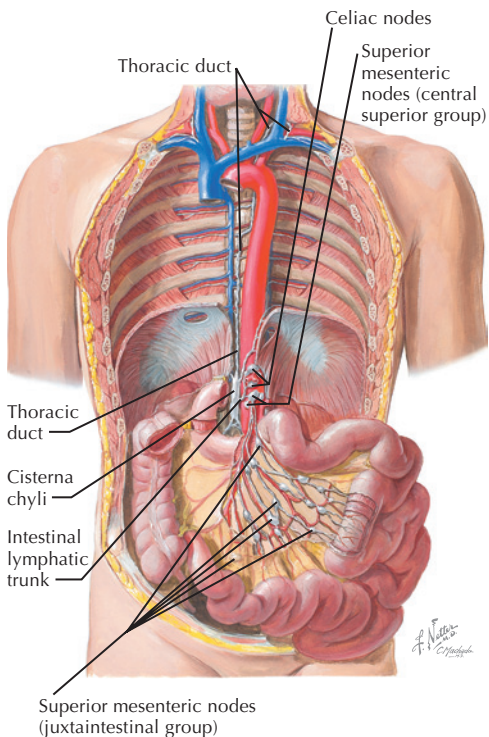
## CLINICAL CORRELATES

### Small Bowel Obstruction

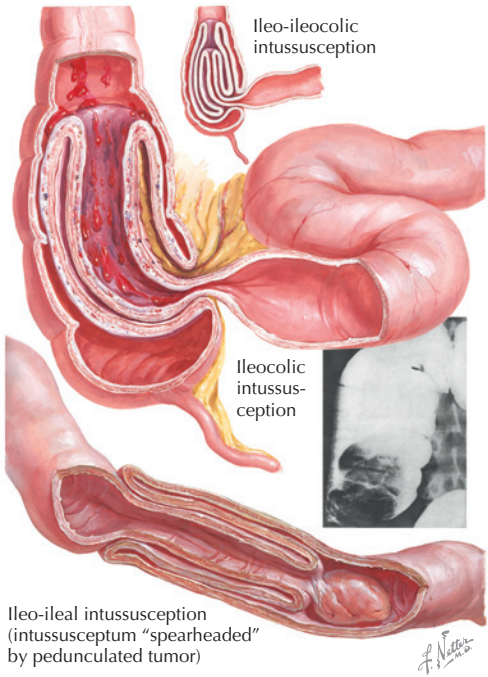
- *Hernias* are most common cause in absence of previous surgery.
- Adhesions are most common cause with previous surgery.
- Other causes include malignancy, inflammatory bowel disease, Meckel's diverticulum, and volvulus.
- Midgut volvulus can occur in pediatric patients with malrotations.

### Intussusception

- Portion of bowel (intussusceptum) invaginates into an adjoining segment of bowel (intussusciens), causing obstruction.
- Can occur in adults owing to tumors; lead point is often a malignant tumor.



Lymph Vessels and Nodes of Small Intestine



Ileo-ileocolic intussusception

Ileocolic intussusception

Ileo-ileal intussusception (intussusceptum "spearheaded" by pedunculated tumor)

### Intussusception

- Ileocolic is the most common kind in infants.
  - Typically occurs between 5 and 10 months
  - Timing (after 3 months) suggests infectious etiology.
  - Terminal mesenteric node enlargement may be an indicator.
  - Enlarged parietal lymphoid aggregates may be lead points that induce invagination.
  - Idiopathic
    - ▲ No other specific pathology is typically associated.
    - ▲ More common in children <2 years
    - ▲ Viral infections and rotavirus vaccine have been implicated.
- Ileoileal
  - More common in children >2 years
  - Lead point may be a Meckel's diverticulum, pancreatic rest, enteric duplication cyst, or hemangioma.
- Ileocolic and ileocecal intussusception can occur after trauma or abdominal surgery.

### Diverticular Disease

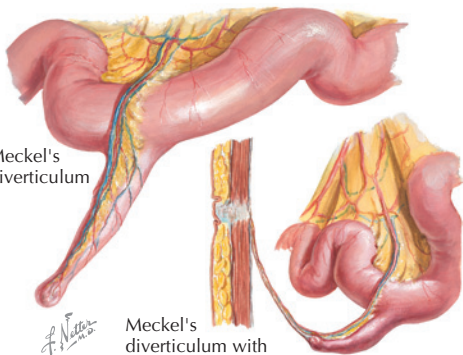
- Most intestinal diverticula are asymptomatic, discovered incidentally during other procedures.
- Acquired jejunoileal diverticula consist of out-pocketing of mucosa and submucosa only.
  - Occurring in <2% of the population
  - Prevalence increases with age.

### Meckel's Ileal Diverticulum

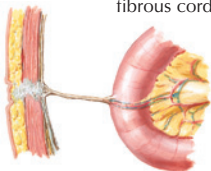
- Most common congenital anomaly of the GI tract: ~2% of population



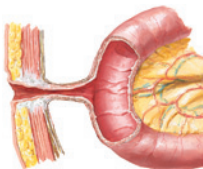Meckel's  
diverticulum



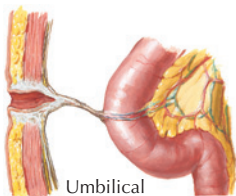
Meckel's  
diverticulum with  
fibrous cord extending to umbilicus



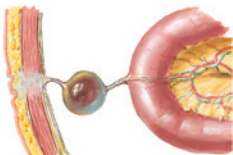
Fibrous cord connecting  
small intestine with umbilicus



Umbilicointestinal fistula



Umbilical  
sinus



Fibrous cord with  
intermediate cyst

## Meckel's Diverticulum

- Remnant of the omphalomesenteric (vitelline) duct in distal ileum
- True diverticulum: includes all layers of the bowel
- About 2 feet from the ileocecal junction
- Typically manifests with painless lower GI bleeding in first 2 years of life
- Accounts for ~5% of painless lower GI bleeding in children <2 years
- Pancreatic tissue most common nonbowel tissue found in Meckel's diverticula
- Can also include gastric tissue: symptomatic with ulcer occurring in opposite gut wall (due to acid secretion)
- Obstruction: most common presentation in adults
- Diverticulectomy: most common treatment for uncomplicated diverticulitis
- Segmental resection indicated for complicated diverticulitis, neck <1/3 ileal diameter, or inflammation of the base
- Resection on incidental discovery controversial

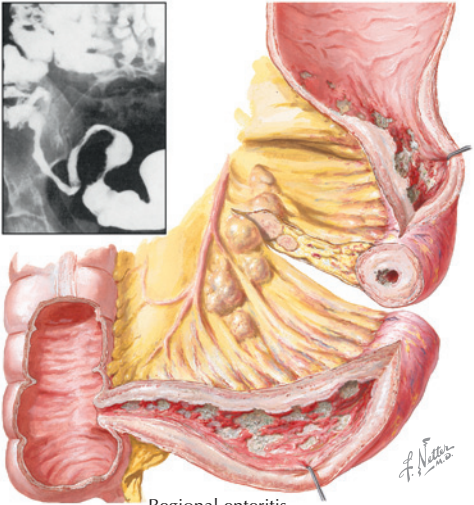
### Cancer of the Small Intestine

- Most common benign neoplasms: adenomas, leiomyomas, and lipomas
- Most common malignant neoplasms: adenocarcinomas, carcinoid tumors, lymphomas, and gastrointestinal stroma tumors, *all rare*
- Only ~2% of GI malignancies occur in small bowel.
- Adenocarcinoma: most common malignant small bowel tumor, most common in duodenum

- Carcinoid
  - Slowly growing tumor of enterochromaffin (argentaffin or Kulchitsky) cells, producing serotonin and bradykinin
  - More commonly found in appendix
  - Small bowel carcinoids are aggressive and typically first seen when metastatic.
  - Carcinoid syndrome, characterized by diarrhea, flushing, hypotension, tachycardia, eventual endocardial fibrosis
  - Symptoms may be minimal with small bowel carcinoid because healthy liver metabolizes excess hormones.
- Gastrointestinal stromal tumors (GIST): most common GI mesenchymal neoplasm (1% of all), often associated with *Kit* gene mutation
- Leiomyosarcoma
  - Usually found in jejunum and ileum
  - Most commonly extraluminal
- Lymphoma
  - Usually found in ileum
  - Increased incidence in Wegener's disease, systemic lupus erythematosus, AIDS, Crohn's disease, celiac sprue
  - Usually B-cell type

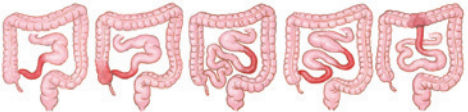### Crohn's Disease

- Idiopathic inflammatory bowel disease, usually involving small and large intestine, but lesions can occur in the GI tract from mouth to anus
- Higher rate of occurrence in Ashkenazi Jews
- Terminal ileum most commonly involved segment
- Asymmetrical distribution of lesions



Regional enteritis confined to terminal ileum

Regional Variations



Terminal ileum

Involving cecum

Upper ileum or jejunum

Skip lesions

At ileocolostomy

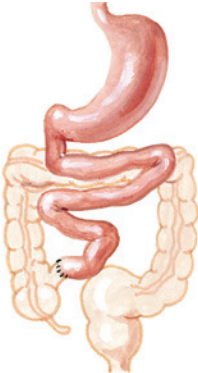Crohn's Disease

- Discrete (aphthous) and longitudinal ulcers common
- Gross bleeding may be absent (25%-30%).
- Rectum frequently spared (~50%)
- Perianal disease ~75%
- Fistulization
- Granulomas 5%-75%
- Discontinuous mucosa involvement
- Mucosal friability uncommon
- Relatively normal surrounding mucosa
- Cobblestoning in severe cases
- Normal vascular pattern
- Surgery *not* curative (unlike ulcerative colitis)

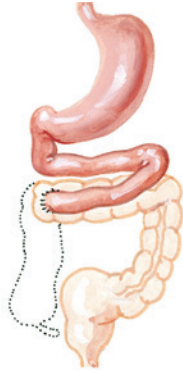### Short-Bowel Syndrome

- Because of absorptive and vascular reserve capacity of small intestine, limited resection of bowel is generally associated with minimal morbidity.
- *Extensive resection* can result in *short-bowel syndrome*, with insufficient absorptive activity, intractable diarrhea, malnutrition, weight loss, and dehydration.
- About 75% of cases result from a single massive resection.
- Adults: most common etiologies of short-bowel syndrome include mesenteric ischemia, malignancy, and Crohn's disease
- Infants and children: atresias, volvulus, and necrotizing enterocolitis are most common causes
- Major public health problem in U.S.: 10,000 to 20,000 affected persons are dependent on total parenteral nutrition (TPN)

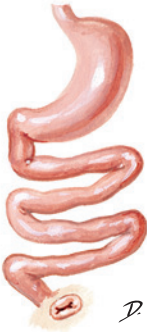*See next page*



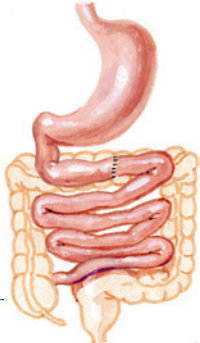
Anastomosis of jejunum with ileocecal valve



Anastomosis of jejunum with large bowel loss of ileocecal valve



Ileostomy

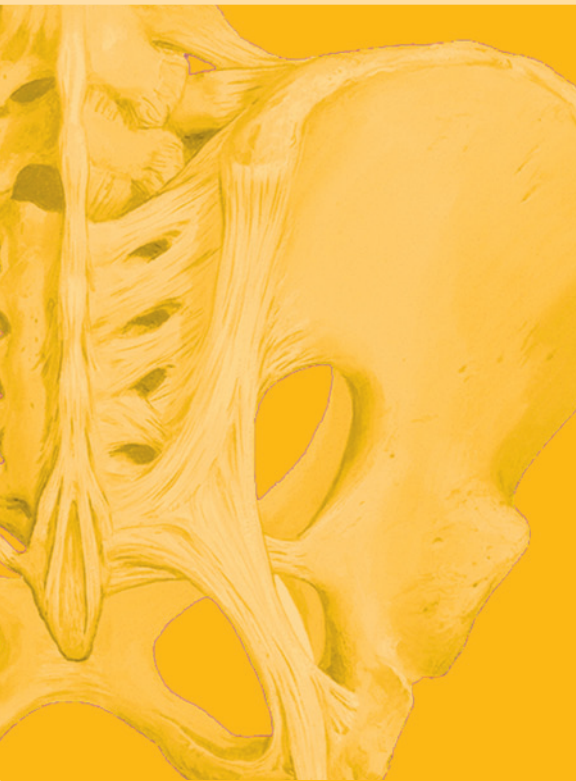

Anastomosis-loss of jejunum

*D. Mascaro*

Short Bowel Syndrome (Types)

# Pelvis and Perineum



Pelvis and Perineum

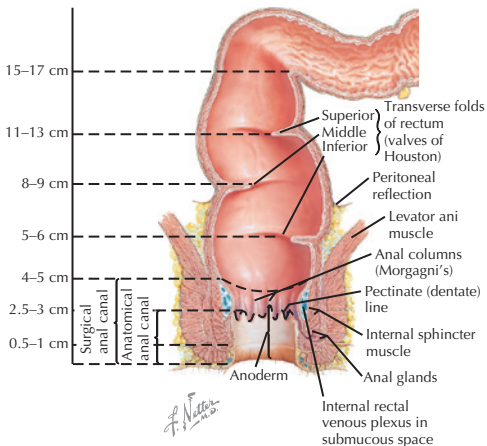
This page intentionally left blank



## ANORECTAL ANATOMY

### Rectum

- Wider diameter than most of colon, except for cecum
- 12-16 cm in length, starting at about the sacral promontory, extending to dentate line of anal canal
- Anterior aspect of upper 4-6 cm is intraperitoneal, with serosal surface.
- Lower (majority of) rectum lies within extraperitoneal pelvis, with no serosa.
- Taeniae coli spread out at rectosigmoid junction to form a continuous, external longitudinal muscle layer.
- Three flexures of rectum usually correspond with 3 transverse rectal folds (superior, middle, and inferior rectal valves).
- Valves overlie thickenings of circular muscle.
- Ampulla: terminal portion of rectum below inferior valve, supported by levator ani and anococcygeal ligament
- Women: thin rectovaginal septum separates anterior inferior rectum from vagina
- Men: prostate and seminal vesicles lie anterior to inferior rectum
- Mucosa: columnar epithelium, down to dentate line



### General Anorectal Anatomy

#### Anal Canal

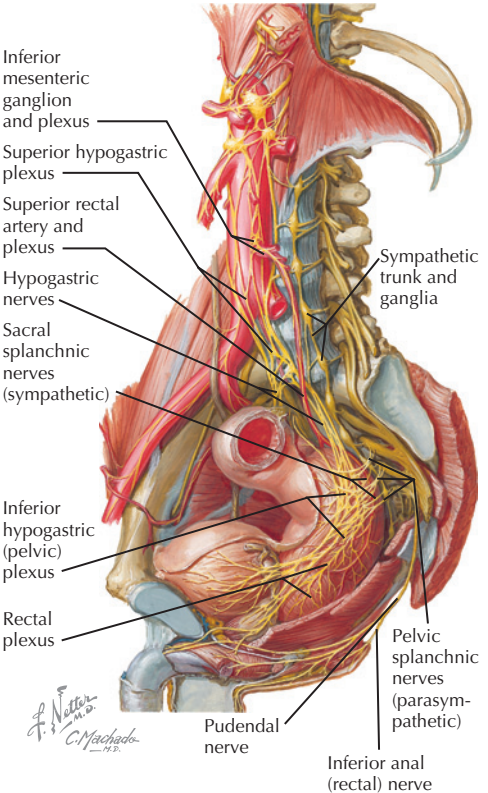
- 3-5 cm in length, from level of levator ani muscles to anal verge
- Canal includes dentate line, anal glands, internal and external sphincter muscles, and hemorrhoidal vessels.
- External anal sphincter muscles: striated muscle, with somatic innervation under voluntary control
- Internal anal sphincter muscle: continuation of inner, circular smooth muscle of hindgut, with autonomic (involuntary) innervation
- Stratified squamous epithelium lines anal canal, beginning at dentate line.

## Microscopic Anatomy

- Mucosa
  - Epithelium: enterocytes (absorptive), goblet cells
  - Lamina propria
  - Muscularis mucosa
- Submucosa
  - Strongest layer (connective tissue)
  - Meissner's plexus (neuronal network)
- Muscularis
  - Auerbach's plexus: myenteric neurons
  - Inner circular muscle
  - Outer longitudinal layer: 3 bands of colic taeniae coli merge into a continuous layer at rectosigmoid junction, down through sphincter level
- Serosa
  - Peritoneum only on anterior superior part of rectum
  - Rest is extraperitoneal, in contact with endopelvic fascia.

## Innervation

- Parasympathetic
  - Preganglionic fibers via pelvic splanchnic nerves from S2-S4 spinal nerves
  - Postganglionic fibers from cells in Meissner's plexus (inner submucosal) and Auerbach's plexus (outer myenteric) of rectal smooth muscle
- Sympathetic
  - Preganglionic fibers distributed via thoracic and lumbar splanchnic nerves through inferior



Rectal/Pelvic Nerves

mesenteric, hypogastric, pelvic, and rectal plexuses

- Postganglionic fibers from cells in inferior mesenteric ganglia to rectal smooth muscle
- Somatomotor to external anal sphincter from S2-S4 spinal nerves via pelvic and rectal plexuses
- Sensory fibers
  - Segmental visceral afferents travel back parallel to sympathetic fibers, through inferior mesenteric plexus and splanchnic nerves.
  - Segmental cutaneous and somatic afferents travel through pelvic plexus to S3 and S4 ganglia.

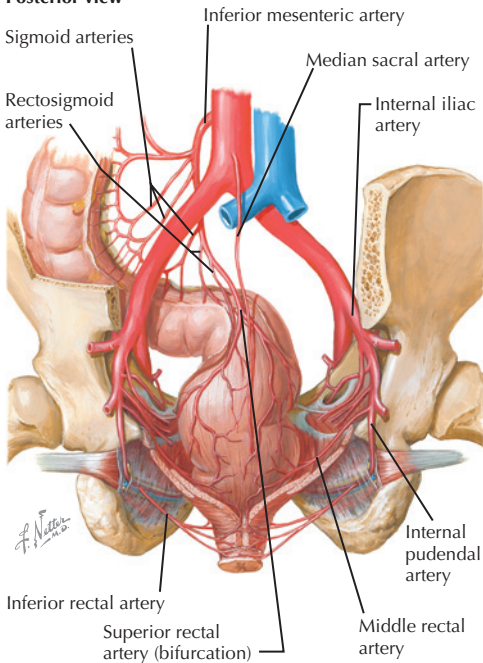
## **VESSELS AND LYMPHATICS**

### **Arterial Supply**

- Inferior mesenteric branches
  - Superior rectal (hemorrhoidal) artery: provides blood to upper rectum
- Internal iliac branches
  - Middle and inferior rectal (hemorrhoidal) arteries provide blood to middle and lower rectum.
  - Inferior vesical artery branches can contribute to rectal anastomoses.

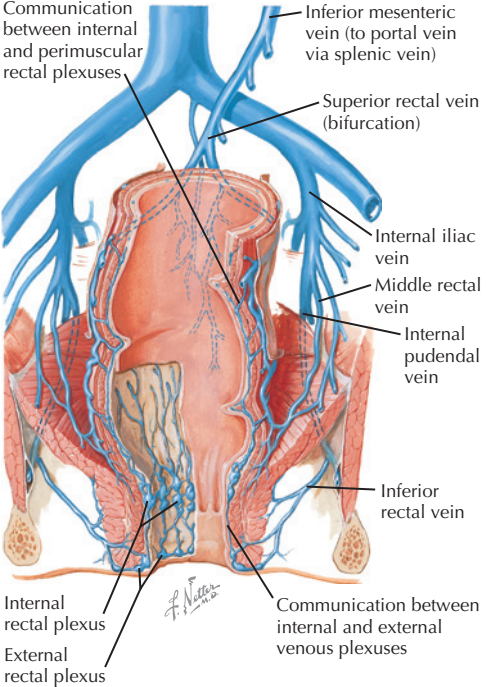
### **Venous Drainage**

- Submucosal venous plexus connects with external rectal venous plexus running in adventitia.
- Rectal venous plexuses have connections to portal and caval venous drainage systems and are basis for formation of hemorrhoids (e.g., with portal hypertension in liver disease).

**Posterior view****Anorectal Arteries**

**Anterior view**

Communication between internal and perimuscular rectal plexuses



**Anorectal Veins**

- Portal venous system tributaries (left side)
  - Inferior mesenteric branches: rectal (hemorrhoidal) venous plexus drainage, down to dentate line
- Internal iliac vein tributaries
  - External rectal (hemorrhoidal) venous plexuses, below dentate line

### Lymphatic Drainage

- Parallels arterial supply
- Upper rectum drains along inferior mesenteric artery branches into periaortic nodes.
- Middle and lower rectum drain along internal iliac branches into pelvic and (eventually) periaortic nodes.

## CLINICAL CORRELATES

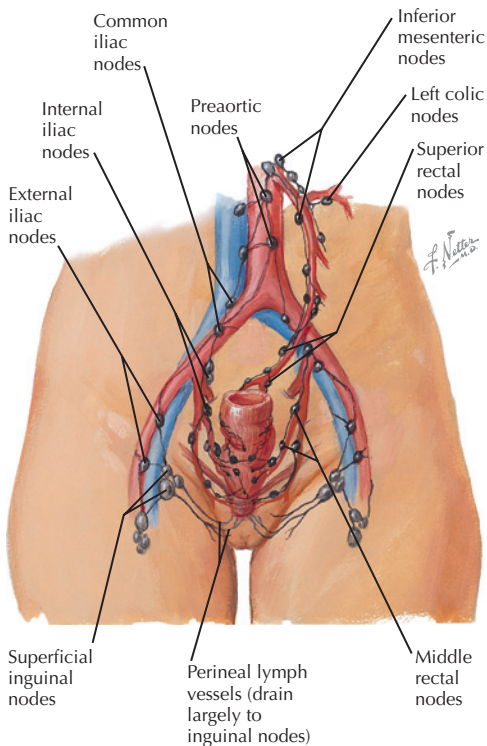
### Hemorrhoids

- Internal hemorrhoids: most common locations are left lateral, right anterior, right posterior
- External hemorrhoids: proper treatment involves excision, not incision and clot expression

### Anorectal Abscess

- Most commonly believed to be of cryptoglandular origin
- Abscess starts in an infected anal gland.
- Begins at dentate line and terminates within intersphincteric space
- Infection can remain within this space or fistulize into ischiorectal, supralelevator, or perineal spaces.
- Most common fistulas extend into ischiorectal space, with inflamed area in gluteal region.





**Anorectal Lymphatics**

- Drainage can leave a fistulous connection between anal canal and skin.
- Crohn's disease patients have a higher rate of abscesses than general population.

### Anal Fissure

- Small tear in the anoderm
- Typically on posterior midline, but may be anterior
- Associated with passage of large or hard stool or diarrhea
- Might heal on its own or require medical or surgical management

### Colonic Ischemia

- Results from disease or mesenteric artery emboli
- Rectum typically is spared owing to internal iliac source of middle and inferior rectal (hemorrhoidal) arteries and anastomoses.

### Rectal Cancer

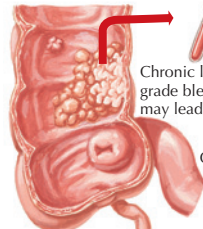
#### *Colorectal Cancer*

- About 130,000 cases diagnosed in Americans per year

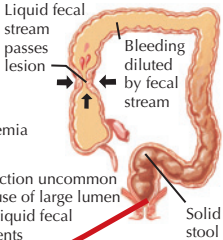
#### *Adenocarcinoma*

- Most common type
- Ulcerative: most common, central depression with raised edges
- Polypoid, large, as described in colon
- Annular: apple core appearance on contrast study, associated with obstruction
- Diffusely infiltrating
  - Thickening of bowel wall
  - Can be flat

**Right (ascending) colon**




Chronic low-grade bleeding may lead to anemia



Obstruction uncommon because of large lumen and liquid fecal contents

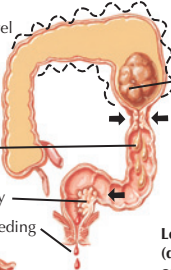
Lesions of right colon often asymptomatic, or "silent," until disease is in advanced stage



Bleeding diluted by feces results in normal-appearing but guaiac-positive stool

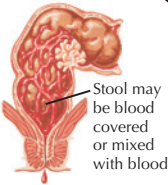
JOHN A. CRAIG, MD

Change in bowel habits may be first symptom of left colon lesions



Cramping pain  
Constipation and obstruction

Paradoxical diarrhea  
Tenesmus and urgency



**Left (descending) colon**

Cancer of left colon and rectum frequently causes bleeding and bowel obstruction due to solid feces

**Clinical Manifestations of Colorectal Cancer**

- Diffusely infiltrating disease difficult to diagnose
- Can spread to external sphincter layer of rectum and anal canal

### *Prognosis*

- Rectal and rectosigmoid cancers have lower cure rates compared with tumors elsewhere in colon.
- Rectal cancers can metastasize to spine owing to direct (valveless) rectal connections to Batson's presacral venous plexus.

### *Treatment*

- Good oncologic resection requires total mesorectal excision for mid-rectal and distal tumors.
- Proximal ligation of inferior mesenteric vessels, distal to the left colic

## ANATOMY OF THE PELVIC SKELETON

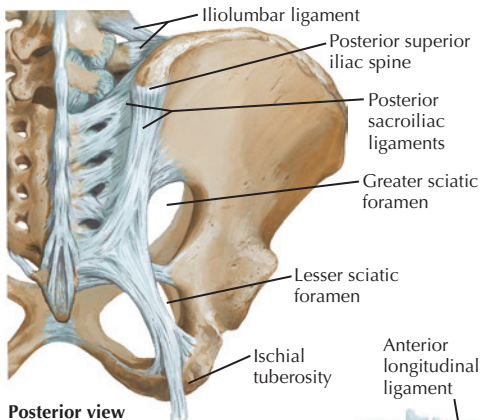
### Coxal Bones (Os Coxae; 2)

#### *Ilium: Parts and Landmarks*

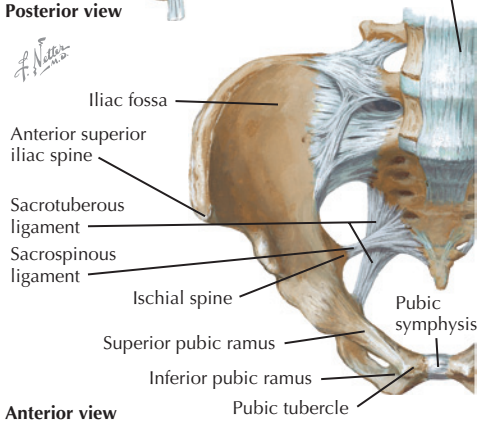
- Crest, ala (wing), fossa (of false pelvis), articular surfaces
- Posterior superior iliac spine (at posterior part of articular surface)
- Iliac tuberosity: posterior sacroiliac ligament insertion
- Anterior superior iliac spine (ASIS): sartorius, inguinal ligament insertions
- Anterior inferior iliac spine (AIIS): rectus femoris, tensor fasciae latae, iliofemoral ligament (hip joint capsule) insertions
- Greater sciatic notch: sciatic nerve, piriformis muscle, pudendal neurovascular bundle exit here
- Ilium often used for cortical and cancellous bone grafts

#### *Ischium: Parts and Landmarks*

- Ischial spine: sacrospinous (SS) ligament insertion
- Body
- Ischial tuberosity: sacrotuberous (ST) ligament, hamstring insertions
- Ischial ramus: fuses with pubic ramus to form medial rim of obturator foramen



*F. Netter M.D.*



**Bony Pelvis and Ligaments**

### *Pubis: Parts and Landmarks*

- Tubercle: medial attachment of inguinal ligament (external oblique aponeurosis)
- Superior public ramus: pecten pubis (pectineal line), along inner superior ridge
- Symphysis: midline fibrous joint of superior pubic rami
- Inferior pubic ramus
- Arch: formed by inferior pubic and ischial rami
  
- Acetabulum formed by portions of all three bones
  - Parts: articular surface, notch, limbus (margin)
  - Should fuse by age ~20 years
- Arcuate line: medial ridge running from ilium (near superior sacroiliac joint) to pecten pubis
- Linea terminalis
  - Bony upper border of the true pelvis, lower border of false pelvis
  - Sacral promontory to iliopectineal line: arcuate line + pectineal line

### **Sacrum**

- Parts and landmarks: ala, sacroiliac articular surfaces, lumbosacral articular (disc) surface, promontory, fused bodies (5), anterior and posterior foramina, coccyx (~4 segments)
- Sacral canal: continuation of vertebral canal with meninges and roots of spinal cord
- Posterior: median and lateral sacral crests, superior articular facet (to L5 inferior facet), sacral hiatus (end of sacral canal, ref. for caudal anesthesia)
- Posterior and anterior sacrococcygeal ligaments

## Pelvic Joints

- Sacroiliac (SI)
  - Synovial joints with minimal movement
  - Posterior pelvis stability, weight-bearing
- Pubic symphysis: anterior pelvis
- Coxal
  - Ilium, ischium, and pubis intersect in acetabular fossa.
  - Typically fused by age 20 years

## Pelvic Ligaments

- Sacroiliac
  - Anterior and posterior (more extensive)
  - Support SI joints
- Sacrotuberous; lower border of lesser sciatic foramen
- Sacrospinous: lower border of greater sciatic foramen, anterior to coccygeus fibers
- Anterior longitudinal
  - Runs on anterior aspect of vertebral bodies onto sacrum
  - Prevents hyperextension of lumbar spine
- Supraspinous and interspinous
  - Run between vertebral spines and onto median sacral crest
  - Prevent hyperflexion of lumbar spine

## NEUROVASCULAR SUPPLY

### Nerves of the Pelvis

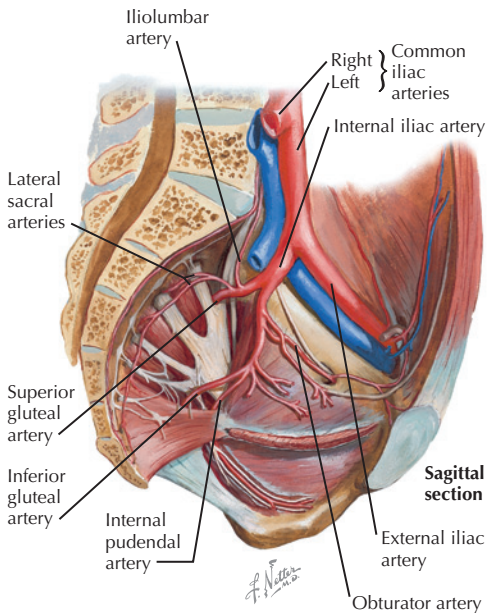
- Hilton's law: nerves supplying a joint also innervate muscles acting across it, as well as skin over distal insertions of those muscles



- Sciatic nerve: anterior rami of L4, L5 (lumbosacral trunk), S1-S4, collect as trunk and pass out of greater sciatic foramen
- Sacral plexus
  - Portions of anterior rami of S1-S4 supply pelvic floor muscles and regional sensation.
  - Sciatic nerve motor and sensory to majority of lower limb
  - Parasympathetic preganglionic fibers from S2-S4 lateral column neurons to viscera (pelvic splanchnics; nervi erigentes)
  - Sympathetic fibers from inferior mesenteric ganglion to pelvic viscera via hypogastric nerves and hypogastric plexus, running anterior to sacral bodies; also, contributions from sacral ganglia
- Pudendal nerve (S2-S4, sacral plexus branch)
  - Motor to perineum and pudenda
  - Sensory to perineum and pudenda
- Obturator nerve
  - Traverses lateral wall of lesser pelvis, exits through obturator foramen
  - L2-L4 supply to thigh adductors

## Arteries of the Pelvis

- Common iliac arteries and their internal and external iliac branches supply bones and viscera within the pelvic cavity.
- Common iliac branches: internal, external, middle sacral
- External iliac branches: inferior epigastric, deep circumflex iliac arteries



### Arteries and Veins of Pelvis

- Internal iliac branches
  - Posterior: iliolumbar, lateral sacral, and superior gluteal arteries
  - Anterior: umbilical, superior vesical, obturator, inferior vesical, prostatic or uterine/

vaginal, internal pudendal, middle rectal, and inferior gluteal arteries

- Internal pudendal artery
  - Passes out through greater sciatic foramen, around ischial spine, into lesser sciatic foramen
  - Trauma can compromise perineal and cavernosal supply.

## Venous Drainage

- Pelvic walls and viscera drain largely into branches of internal and external iliac veins (*caval venous return*).
- Visceral plexuses interconnect.
  - Vesical, uterine/vaginal or prostatic, rectal
  - Drain mainly into internal iliac veins
- Rectal plexus blood also drains into inferior mesenteric vein via superior rectal vein (*portal venous return*).
- Lateral and middle sacral veins drain into internal and common iliac veins, respectively (anterior sacral region).
- Iliolumbar veins drain into common iliac veins (iliac fossa region).
- Deep circumflex iliac and inferior epigastric veins drain into external iliac (anterior greater pelvis region).

## CLINICAL CORRELATES

### Pelvic Fractures

#### *Mechanisms*

- High-energy force
  - Lateral more common, as in motor vehicle accidents

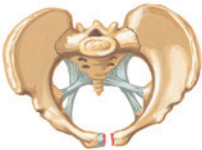- Other injuries may be life-threatening, requiring emergency treatment.
- About 50% mortality with open fracture and GI or genitourinary injuries
- Intact posterior sacroiliac ligament key to stability
- Minor trauma
  - Fall, with osteoporosis
  - Single ramus fracture, stable
- Stable avulsion fracture
  - ASIS: sartorius tendon avulsion
  - AIIIS: rectus femoris tendon avulsion
  - Ischial tuberosity: hamstring tendon avulsion

### *Associated Injuries*

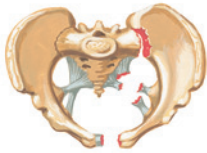- Open wounds
- *Massive bleeding* with internal blood loss (symptoms: flank swelling, ecchymoses)
- Bleeding from pelvic venous plexuses: vesicular, prostatic, vaginal, uterine, rectal
- Urethral, rectal, or vaginal injuries
- Anterior fractures: venous bleeding more likely
- Posterior fractures: arterial bleeding more likely

### *Young and Burgess Classification*

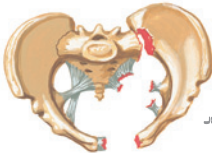- Anterior and posterior compression (APC)
  - I: Sacral compression, rami fractures; stable
  - II: Rami fractures, posterior sacroiliac ligament disruption; stable
  - III: Complete disruption of sacroiliac joint, pubic symphysis; unstable
- Lateral compression (LC)
  - I: Sacral compression with rami fractures



Anteroposterior Compression  
type I (APC-I)

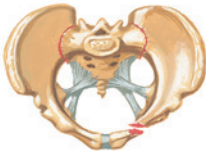

Anteroposterior Compression  
type II (APC-II)

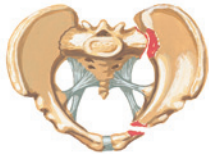


JOHN A. CRAIG MD

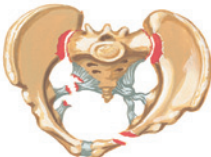Anteroposterior Compression  
type III (APC-III)



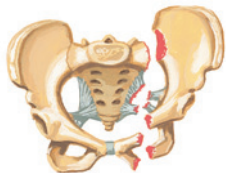Lateral compression  
type I (LC-I)



Lateral compression  
type II (LC-II)



Lateral compression  
type III (LC-III)

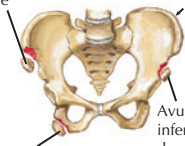


Vertical shear

## Classification of Pelvic Fractures (Young and Burgess)

**Avulsions**

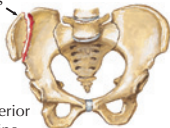
Avulsion of anterior superior iliac spine due to pull of sartorius muscle



Avulsion of ischial tuberosity due to pull of hamstring muscles

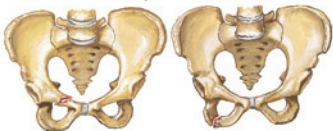**Fracture of iliac wing**

These fractures usually not displaced or minimally displaced and generally require only limitation of activity until pain ceases

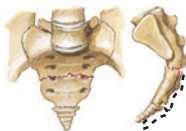


Avulsion of anterior inferior iliac spine due to pull of rectus femoris muscle

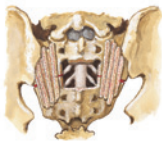*F. Netter M.D.*

**Fracture of one pubic or ischial ramus**

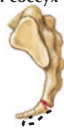Isolated fracture of one pubic or ischial ramus requires only bed rest until pain diminishes, followed by limited activity for 4-5 weeks, provided there is no visceral or vascular injury

**Fractures of sacrum****Fracture of coccyx**

Impacted transverse fracture that is minimally displaced is most common type. Conservative treatment sufficient unless there is nerve injury



Sacral laminectomy and bone grafts from ilium used for sharply angulated fractures with nerve injury



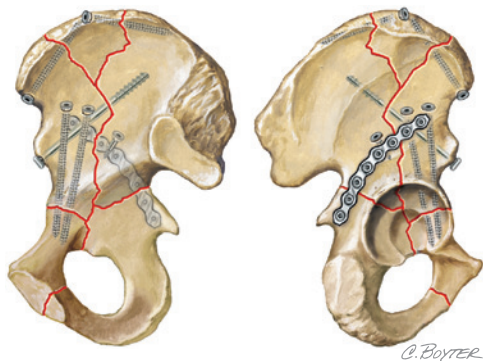
Fracture usually requires no treatment other than care in sitting; inflatable ring helpful. Pain may persist for a long time

**Fractures of Pelvis without Disruptions of Pelvic Ring**

- II: Ramus fracture, posterior SI ligament disrupted; stable
- III: II + contralateral APC-III; unstable
- Vertical shear
  - Anterior and posterior pelvic displacement injury
  - Vertically unstable

### Acetabular Fractures

- Typically from extreme force transmitted by femoral head (e.g., motor vehicle accident)
- May be associated with life-threatening injuries: stabilize airway, breathing, heart, and other trauma



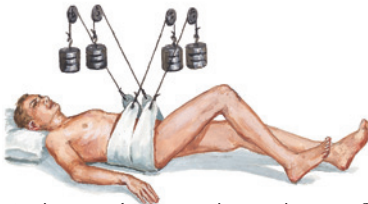
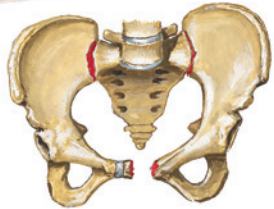
Representative fixation for both-column fracture with associated iliac wing fractures

### Acetabular Fracture Fixation

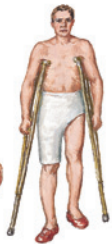

Forceful frontal impact causes anteroposterior compression of pelvis

Fracture of pubic bone or rupture of pubic symphysis with wide anterior separation of pelvis and disruption of pelvic ring. One or both sacroiliac joints often subluxated



Application of crossover slings with enough weight to rotate halves of pelvis medially and anteriorly, thus bringing them together. Reduction maintained for 3-4 weeks



Spica cast, which permits walking, then worn for 4-6 weeks

**Anterior Posterior Compression Fracture**



### *Judet-Letournel Classification*

- 5 elementary patterns of acetabular fractures: anterior wall, posterior wall, anterior column, posterior column, transverse
- Associated fractures may include more than one type.

This page intentionally left blank

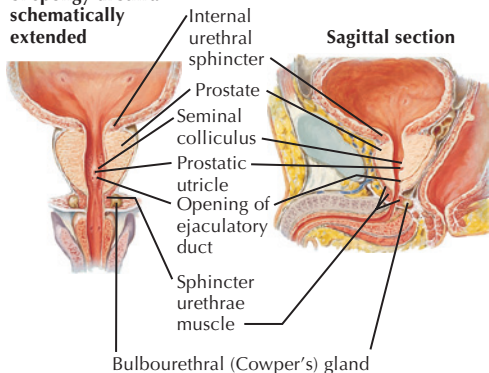
## BASIC ANATOMY

### Prostate Proper

- Largest accessory gland of the male genital tract
- Partly glandular, partly fibromuscular
- Glandular growth and maturation controlled by testosterone, which is converted to dihydrotestosterone (DHT) by 5-alpha reductase
- Peri-urethral transition zone of the parenchyma: <10% of the stroma
- Peripheral zone of the gland: ~70% of the normal gland
- Smooth musculature of the prostate: part of the involuntary sphincter of the bladder
- Normal: walnut sized, ~20 g
- 5 “traditional” lobes
  - Anterior (isthmus): largely muscular, sphincteric (see later)
  - Middle: lies between urethra and ejaculatory ducts
  - Posterior (inferoposterior): posterior to urethra and ejaculatory ducts, palpable (see later)
  - Left and right lateral: form the majority of the prostate
- *Middle lobe*: most common site of benign prostatic hyperplasia (BPH), process arising in the periurethral transitional zone

**Frontal section,  
anterior view of  
bulbous portion  
of spongy urethra  
schematically  
extended**

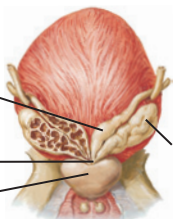
**Sagittal section**



Ampulla  
of ductus  
deferens

Beginning  
of ejaculatory  
duct

Prostate



*F. Netter  
M.D.  
C. Machado  
— 1912*

Seminal  
vesicle

**Posterior view**

**Pelvic Cavity, Bladder, and Prostate**

- *Anatomical parts*: base, apex, four surfaces
  - Base: vesicular surface, related to the base of the bladder
  - Apex: inferior point, related to superior fascia of the urogenital diaphragm
  - Anterior surface: retropubic, with largely transverse musculature, forms a rhabdosphincter (hemisphincter)
  - Posterior surface: triangular, rests on ampulla of the rectum, palpable
  - Inferolateral surfaces: resting on levator ani muscles and fascia
- *Supported anteriorly by puboprostatic ligaments*, central portions of the pubococcygeus, part of the levator ani muscles (anterior pelvic diaphragm)
- *Supported inferiorly by the urogenital diaphragm* (transversus perinei muscle and fascia), through which the urethra passes
- Bulbourethral (Cowper's) glands
  - Lie inferior and adjacent to the prostatic apex, within the urogenital diaphragm
  - Provide mucus secretion for penile urethra

### Prostatic Capsule(s)

- *Prostatic (true) capsule*: thin, dense, fibrous connective tissue enclosing parenchyma and surrounded by false capsule
- *False capsule*: prostatic *sheath*, derived from inferior, endopelvic fascia
  - Sheath is continuous inferiorly with superior fascia of urogenital diaphragm.
  - Posterior sheath is part of the rectovesical septum.

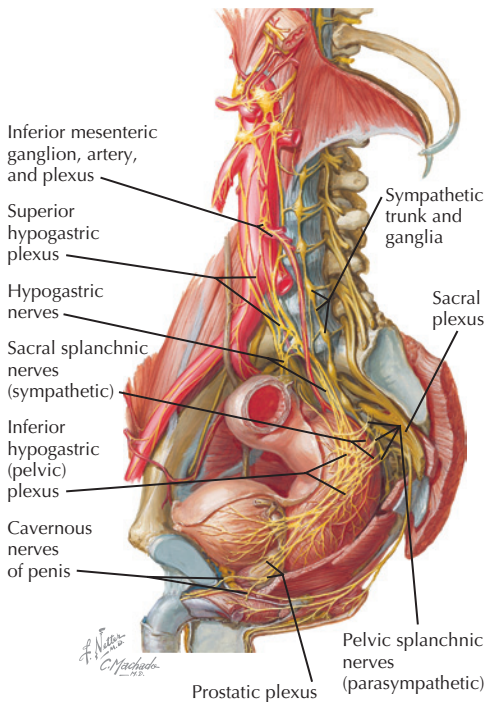
- Prostatic venous plexus lies between prostatic capsule and surrounding sheath.

### Prostatic Ducts and Urethra

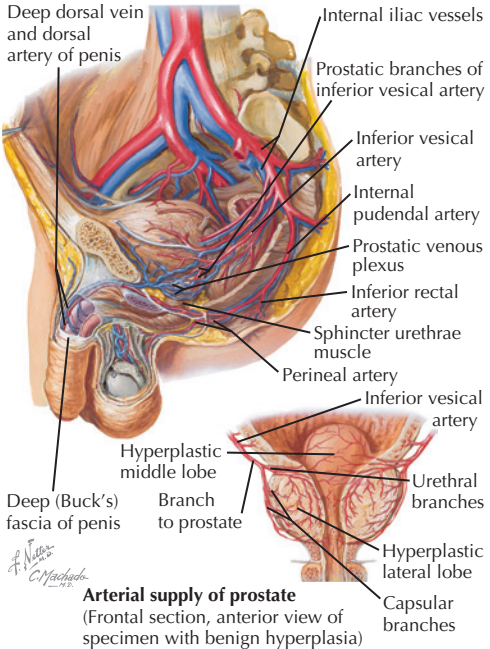
- Multiple small prostatic ductules penetrate wall of prostatic urethra.
- *Seminal colliculus* (verumontanum) in posterior urethral wall marks location of paired *ejaculatory ducts* draining ductus deferens and seminal vesicles.
- Prostatic utriculus: small midline invagination in dome of colliculus, marks remnant of embryonic male paramesonephric (müllerian) ducts (“male uterus”)

### Prostatic Innervation

- Bilateral nerves of the prostate come from sacral (inferior hypogastric) nerve plexus lying between sacrum and rectum.
- Fibers to and from the prostate travel in posterolateral *neurovascular bundles* with *nervi erigentes* (responsible for erection-related functions) and prostatic arteries.
- *Pelvic parasympathetic efferents* travel in pelvic splanchnic fibers (S2-S4, *nervi erigentes*) through pelvic plexus.
- *Sympathetic postganglionic fibers* come from inferior mesenteric ganglion via hypogastric and inferior hypogastric plexuses.
- *Sensory fibers* from gland and capsule travel with *nervi erigentes* through pelvic plexus to sacral (S2-S4) spinal ganglia.



Nerves of Pelvic Viscera



Arteries and Veins of Pelvis, Male

**VESSELS AND LYMPHATICS**

**Arterial Supply**

- Prostatic arteries derive variably from internal iliac circulation bilaterally, including branches



of inferior vesical, inferior rectal, and internal pudendal arteries.

- Approach prostate posteriorly, adjacent to nervi erigentes (neurovascular bundles) and prostatic nerve plexus in floor of pelvis

## Venous Drainage

- Prostatic venous plexus lies around sides and anterior aspect of gland, between prostatic capsule and its surrounding prostatic sheath (fascia).
- Plexus drains into internal iliac veins via prostatic or inferior vesical branches.
- Plexus also drains posteriorly into vertebral venous plexuses (route for metastases).

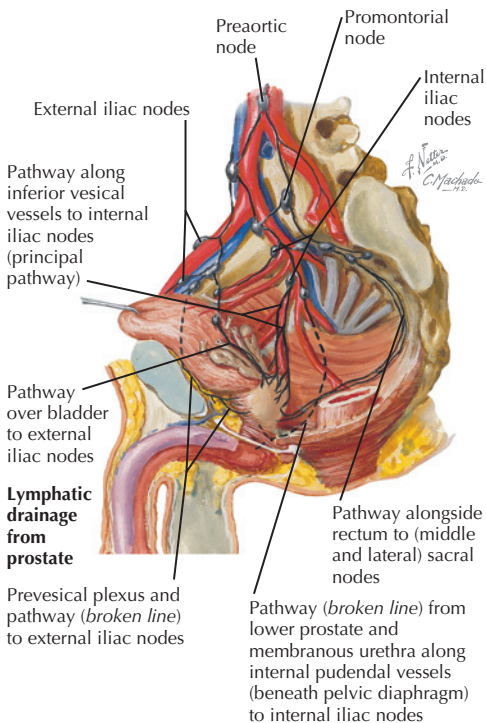
## Lymphatics

- Lymphatics of prostate drain into internal iliac and obturator (pelvic) nodes.
- Pelvic lymph nodes drain up into aortic chain of nodes.

## CLINICAL CORRELATES

### Prostate Specific Antigen (PSA)

- Normal patient, PSA  $<4.0$  ng/mL
- PSA increases seen in prostatitis, BPH, prostatic carcinoma, chronic catheterization (nonspecific)
- Prostate cancer may be detected when PSA surpasses  $4.0$  ng/mL: need for regular testing increases in at-risk men.



Lymphatics of Prostate

- Should return to undetectable level after prostatectomy, unless significant metastases exist

## Benign Prostatic Hyperplasia (BPH)

### *Diagnosis*

- Typically begins in transitional zone surrounding urethra
- Presenting symptoms (typical) are difficulty with urination: hesitancy, decrease in force, intermittency, increased frequency, nocturia, urinary retention
- Gradual onset, possible history of urinary tract infections (UTIs)
- Digital rectal exam (DRE) might demonstrate palpable enlargement.
- PSA level should be measured, although it is not specific.

### *Treatment*

- Treatment decisions are based on level of difficulty experienced by the patient (goal-directed therapy).
- Medical treatment is first-line therapy: alpha blockers, 5-alpha reductase inhibitors (e.g., finasteride).
- Transurethral prostatectomy (TURP)
  - Gold standard
  - Indicated for recurrent UTIs, stones, gross hematuria, renal insufficiency, medical treatment failure
- Open prostatectomy
  - Typically through a lower midline abdominal incision
  - May be indicated for a patient with a particularly large prostate

### *Aspects of TURP*

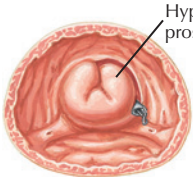
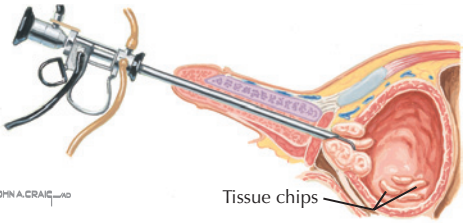
- Post-TURP syndrome
  - Hyponatremia secondary to irrigation
  - Can precipitate seizures and cerebral edema

### **Carcinoma of the Prostate**

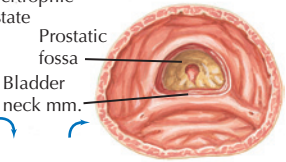
- Most common male solid organ cancer in the U.S., currently the second most common cause of cancer mortality, with adenocarcinoma the most common type
- It manifests in different ways.
  - Indolent course: asymptomatic, sometimes only discovered postmortem or on indicated testing
  - Aggressive course: extracapsular spread with metastases and threat of early death
- The majority of men with low-grade prostate cancer have no symptoms.
- Most common site of primary carcinoma: posterior lobe
- Most common site of distal metastasis: bone, with osteoblastic lesions showing increased density on CT and radiograph
- Increases in serum alkaline phosphatase seen with extracapsular carcinoma and metastases

### *Staging and Treatment*

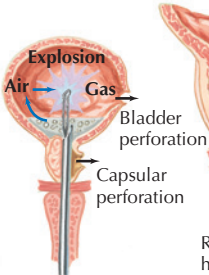
- Tumor/node/metastasis (TNM) system used
- Gleason scoring system: additional scoring (1-5) from well-differentiated (least aggressive) to poorly differentiated (most aggressive)
- Transrectal ultrasonography (TRUS) can provide an accurate image of the gland and guide needle biopsies.
- CT can provide evidence of prostatic pathoanatomy, lymphadenopathy, and metastases.



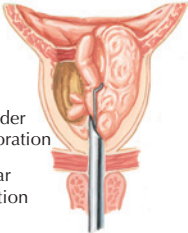
Intravesical view of hypertrophy



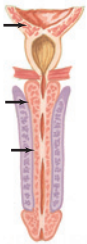Postoperative view



Surgical complications

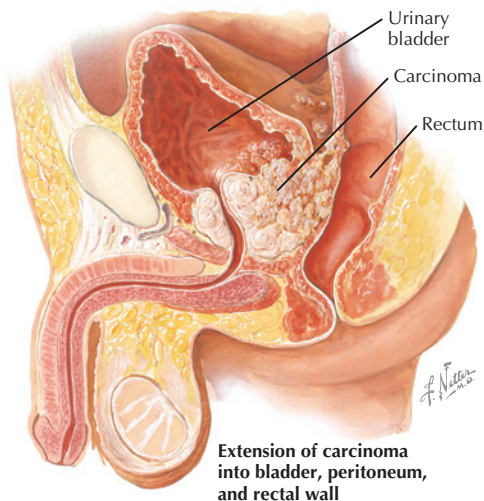


Removal of hypertrophied inner zone by resection



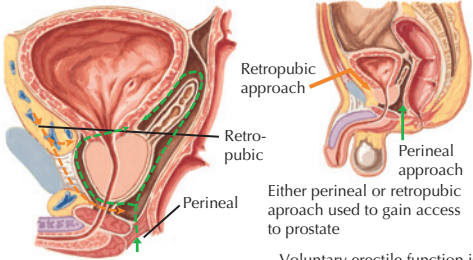
Postoperative urethral stricture

Transurethral Prostatectomy



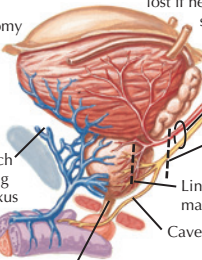
### Prostatic Carcinoma

- *Optimal treatment* for localized prostate cancer remains controversial.
- Intracapsular tumors, no metastases (on T1 and T2 MRI): irradiation, radical prostatectomy with pelvic lymph node excision, or no treatment depending on age, specifics
- Extracapsular tumors with metastases
  - Hormonal treatment with luteinizing hormone-releasing hormone blocker or testosterone blockers, potential orchiectomy



Either perineal or retropubic approach used to gain access to prostate

Radical prostatectomy removes entire prostate, seminal vesicles, and periprostatic tissue



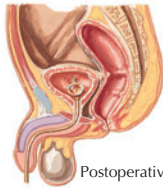
Voluntary erectile function is lost if neurovascular bundle sectioned proximal to branching of corporal nerves

Retropubic approach can initiate bleeding from pudendal plexus

Neurovascular bundle  
Section results in loss of erection  
Line of section to maintain erection  
Cavernous nerve

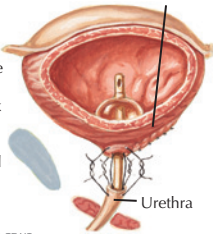
Urinary incontinence can result from damage to intrinsic urethral sphincter

Bladder neck reconstruction



Postoperative appearance

After prostate is removed, bladder neck is reconstructed and anastomosed to urethra



Urethra

JOHN A. CRAIG MD

## Radical Prostatectomy

- Irradiation for pain of bony metastases, chemotherapy for hormone-resistant disease
- “Chemical castration”: luteinizing hormone-releasing hormone (LHRH) antagonists suppress testosterone production in androgen-dependent tumors
- LHRH antagonists are also called GnRH antagonists (gonadotropin-releasing hormone blockers).
- Alternatives or complements to prostatectomy: x-ray or particle beam therapy, brachytherapy (implanted radiation sources), and cryotherapy

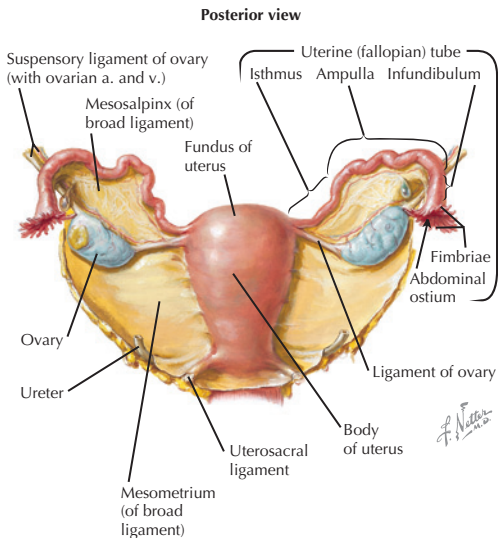
### Surgical Approaches in Prostatectomy

- Retropubic approach to radical (complete) prostatectomy: preferred for giving access to pelvic lymph nodes; venous bleeding risk
- Perineal approach to radical prostatectomy: requires second incision or laparoscopy for lymphadenectomy



**ANATOMY OF THE UTERUS,  
ADNEXA, AND VAGINA****Uterus**

- Derived from fusion of paired embryonic paramesonephric (müllerian) ducts: basis for divided, asymmetrical, or bifid (didelphic) uteruses
- Endometrium: highly vascular and glandular uterine lining; thickness or state varies with menstrual cycle
- Myometrium: dense, fibrous connective tissue and smooth muscle, derived from embryonic splanchnic mesoderm
- Mesometrium: peritoneal covering of the uterus, continuous with peritoneum of broad, transverse (cardinal), uterosacral, and suspensory (infundibulopelvic) ligaments
- Fundus: dome superior to uterine tube orifices
- Body: superior 2/3
- Cervix: inferior 1/3; inferior aspect opens into vagina
- Isthmus: surface narrowing marking transition from body to cervix
- Uterine ostia: internal orifices of uterine tubes
- Uterine cavity: typically conical, apex down when not gravid
- Internal os: superior opening of cervical canal
- External os: inferior opening of cervical canal



## Uterus and Adnexa

### Position of the Uterus and Pouches

- Typical, nongravid position: body anteflexed, lies against bladder
- Cervix between rectum and inferior bladder
- Nongravid uterus is thus anteverted relative to the vaginal canal and anteflexed on its own axis.

- Rectouterine pouch (of Douglas): posterior, pre-rectal peritoneal recess
- Vesicouterine pouch: anterior peritoneal recess between bladder and uterine fundus; also uterovesical

### Uterine (Fallopian) Tubes (Ducts)

- Fimbriae: fringe around infundibular orifice
- Infundibulum: initial, funnel-like section proximal to fimbriae
- Ampulla: middle, wide portion proximal to infundibulum
- Isthmus: narrower portion approaching uterine wall
- Uterine portion: tube within uterine wall

### Ovaries

- Normally almond-shaped and -sized
- Lie laterally and posterior to the broad ligament, attached near its upper borders via a peritoneal mesovarium
- Attached to body of uterus via ovarian ligaments running within broad ligament
- Contain follicles embedded in germinal epithelium and stroma
  - Primary, secondary, and mature (Graafian) ovarian follicles
  - Corpus luteum (postovulatory follicle of current cycle)
  - Corpus albicans (scar of degenerated corpus luteum)
- Granulosa cells surround an oocyte in its follicle.
- Theca interna and externa cells enclose the mass of granulosa cells and ovum.

- Interna layer differentiates into theca lutein cells of corpus luteum, which secrete estradiol.
- Vascularized stroma surrounds follicles.
- Thin surface epithelium (tunica albuginea) of fusiform cells in connective tissue
- Originally smooth surface epithelium becomes progressively scarred by ovulation.

## Vagina

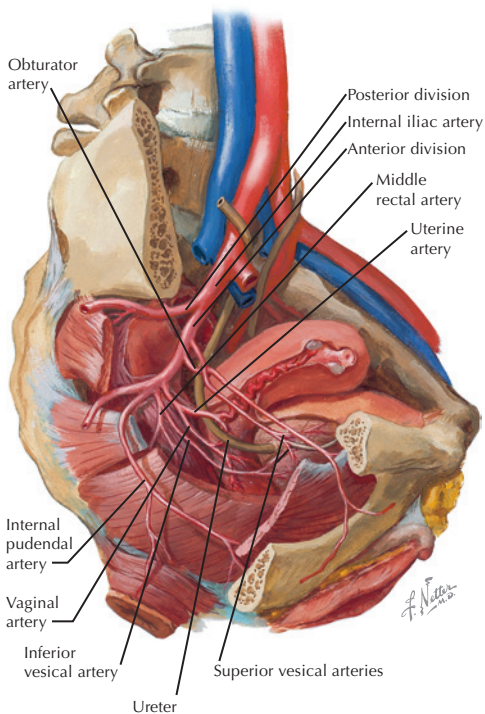
- Fibromuscular tube extending from cervix to vestibule between labia minora
- Vestibule includes vaginal and urethral orifices and greater vestibular gland openings.
- Fornices: (anterior, posterior, lateral) recesses in the superior vagina, surrounding the cervix
- Lower portion typically collapsed, with H-shaped cross-section, anterior and posterior walls in contact
- Urethra runs just superficial to middle of inferior anterior vaginal wall.

## VESSELS

### Arterial Supply

- Uterus and adnexa supplied *bilaterally* (on left and right sides) by three major anastomotic arteries, superior to inferior
  - Ovarian arteries: paired, from abdominal aorta, branches originate inferomedial to renal arteries, descend to pelvis in peritonealized suspensory (infundibulopelvic) ligaments of ovaries along with nerves and veins
  - Uterine arteries (from internal iliacs): paired, travel medially from pelvic wall, within cardinal ligaments, at about the level of the cervix

## Right paramedian section: lateral view



Pelvic Arteries in the Female (right side)

- Vaginal (from internal iliacs): travel medially from pelvic walls, at level of inferior vesical or internal pudendal artery branches
- Uterine arteries cross over ureters, close to cervix: risk of ureter damage or ligation in surgery; “water” (urine) “under the bridge” (uterine artery)
- Vagina supplied by named vaginal and internal pudendal branches of internal iliacs

### Venous Drainage

- Uterus and adnexa drained by major veins that travel parallel to corresponding arteries
- Uterine, ovarian, and vaginal veins interconnect in an extensive bilateral uterine plexus running within proximal broad ligaments.

### *Ovarian Veins*

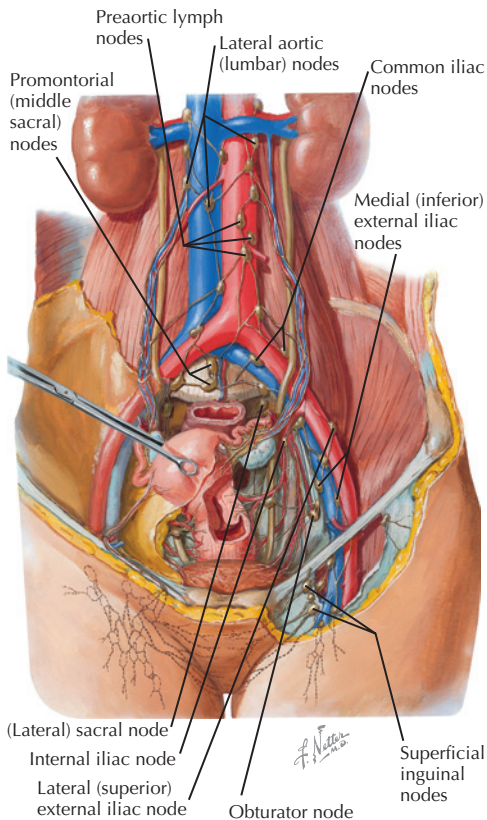
- Right ovary drains to right inferior vena cava and left ovary to left renal vein.
- Veins ascend in pelvis and abdomen, traveling with nerves and arteries within suspensory ligaments.

### *Uterine Veins*

- Drain on right and left into internal iliac veins
- Travel laterally to pelvic wall, within cardinal ligaments, at about the level of the cervix

### *Vaginal Veins*

- Drain on right and left into internal iliac veins
- Travel laterally to pelvic wall, at level of inferior vesical or internal pudendal vein tributaries



Lymph Vessels and Nodes of Pelvis and Genitalia

### Lymphatic Drainage

- Uterine lymphatics drain in multiple directions.
- Ovarian, uterine fundus, and body lymphatics drain upward along ovarian vessels to nodes around lumbar aorta and vena cava.
- Vessels from around the uterine tube junctions drain along the round ligament into superficial inguinal nodes.
- Body and some of the cervix also drain to external iliac nodes along vessels within the broad ligament.
- Cervical lymphatic vessels also drain to external and internal iliac and sacral nodes.

## CLINICAL CORRELATES

### Pelvis and Acute Abdomen

- Diseases of uterus and adnexa can manifest as acute abdomen, with pain localized inferiorly.

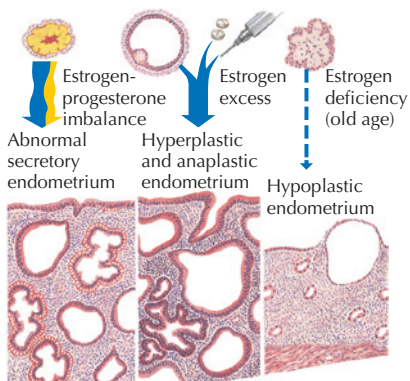
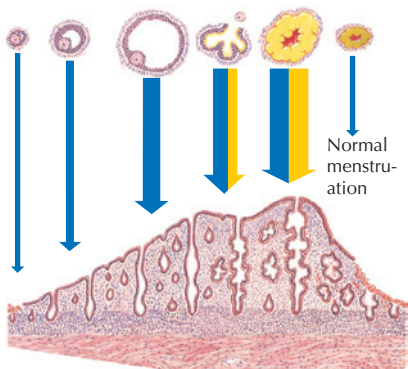
### Uterine Fibromas

- Leiomyomas: firm, benign tumors of myometrial smooth muscle, a.k.a. fibroids
- Most common benign tumor in women
- Prevalence: 30% of all women; 40%-50% of women >50 years
- Risk factors: early menarche, nulliparity; 4-10× increase in African-American women
- Growth stimulated by estrogen, contraceptives, epidermal growth factor

### Ovarian Cysts

- Typically arise from ovarian components: follicular cysts, luteal cysts, ovarian capsule

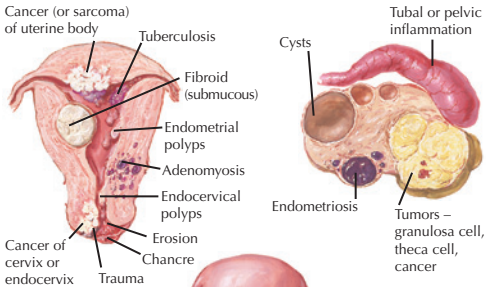




A

## Dysfunctional Uterine Bleeding

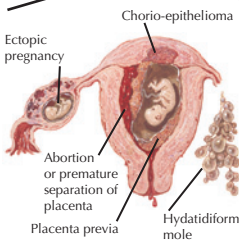
*Continued*



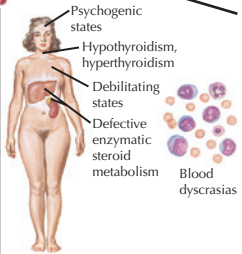
*F. Netter M.D.*

Local uterine disorders

Local ovarian or adnexal disorders



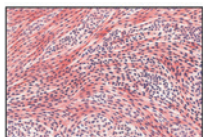
Pregnancy disorders



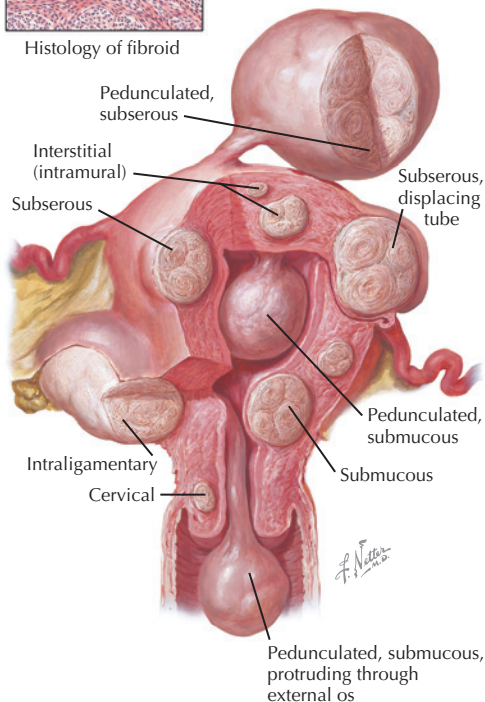
Systemic conditions

**B**

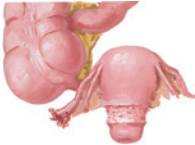Dysfunctional Uterine Bleeding—cont'd



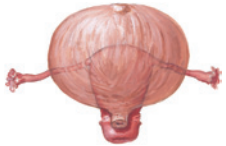Histology of fibroid



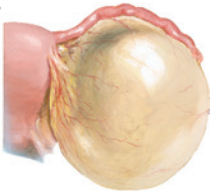
Uterine Fibroids (Leiomyomas)



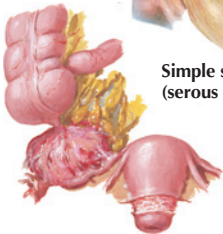
**Low-lying cecum**



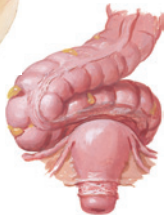**Distended bladder**



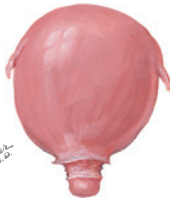**Simple serous cyst (serous cystoma)**



**Appendiceal abscess**



**Redundant sigmoid colon**

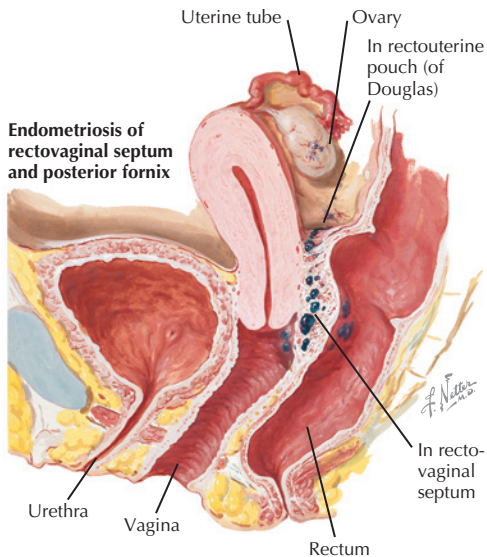


**Pregnancy, hydramnios, hydatid mole, hematometra, pyometra**

*F. Netter M.D.*

**Differential Diagnosis of Ovarian Cysts**

- Ovarian cysts usually small, asymptomatic, benign (>90%)
- Diagnosis may be difficult, with many conditions manifesting as lower abdominopelvic masses.



Endometriosis

### Endometriosis

- Benign foci of endometrial tissue progressively developing in pelvis—ovary, rectouterine pouch,

uterine ligaments, tubes—or elsewhere in peritoneum

- Prevalence of endometriosis: ~5%-10% of women; ~30%-50% of infertile patients
- Causes are multifactorial: genetic, menstrual backflow with spread of cells through tubes, vascular or lymphatic dissemination, or metaplasia of peritoneal epithelium.
- Risk factors: cervical or vaginal outflow obstruction, structural abnormalities

## Cancer

### *Uterine Endometrial Carcinoma*

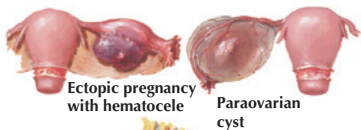
- Most common female reproductive tract malignancy
- Risk factors: obesity and increased estrogen synthesis, estrogen replacement therapy without progestin, breast or colon cancer, early menarche or late menopause, diabetes, chronic anovulation

### *Cervical Carcinoma*

- Squamous carcinomas: ~85%-90% of cases
- Adenocarcinomas: ~10%-15% of cases
- About 12,000 cases and ~4000 deaths in 2005 in U.S.
- Risk factors: early sexual activity, multiple partners, human papillomavirus infection, smoking, African-American ethnicity
- Peak age range: 40-60 years

### *Ovarian Tumors and Cancer*

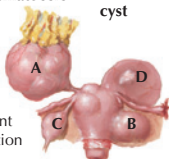
- Origins of tumor tissues
  - Surface epithelium/stroma: 65%-70%; 85%-90% of all malignancies



**Ectopic pregnancy with hemocele**

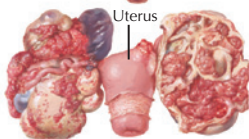
**Paraovarian cyst**

- A. Pedunculated or parasitic
- B. Intraligamentous
- C. Of round ligament
- D. Cystic degeneration

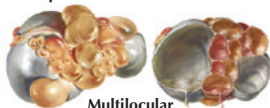

*F. Netter M.D.*

**Papillary serous cystadenocarcinoma**

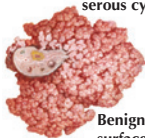

**Epithelial stromal ovarian tumors**

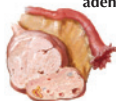

**Multilocular serous cystadenoma**

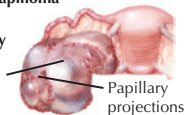
**Serous adenofibroma**



**Benign surface papilloma**



**Clear cell carcinoma of ovary**  
Pelvic mass (up to 30 cm)  
Partially cystic, 40% bilateral



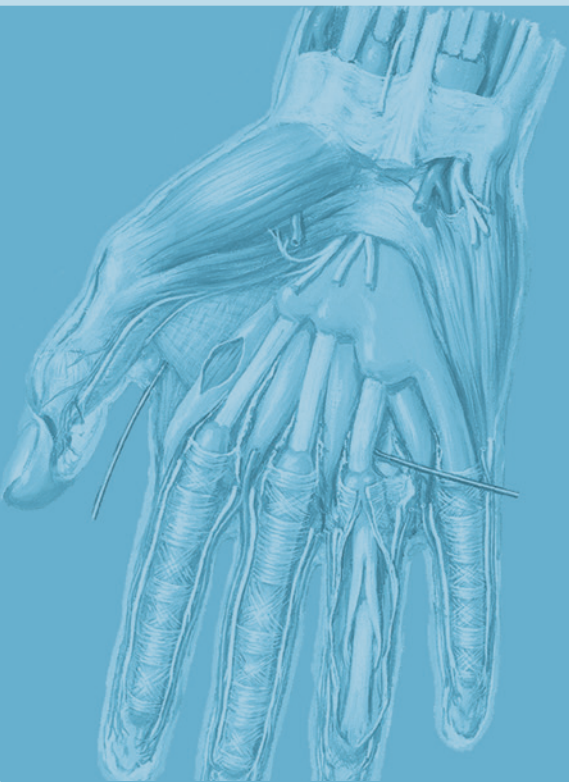
**Papillary projections**

**Ovarian Tumors**

- Germ cell: ~30% of tumors; ~5% of ovarian cancers (most germ cell tumors are benign teratomas); tumors more common in girls and women <30 y.o., accounting for up to 70% of ovarian cancers
- Sex-cord stroma: 5%-10% of ovarian cancers
- Risk factors: age, high-fat diet, family history, early menarche and late menopause, white ethnicity, high socioeconomic status
- Age of occurrence or discovery
  - Benign tumors, 20-29 years
  - Malignant tumors, 50% occur in women >50 years



# Upper Limb



This page intentionally left blank

## ANATOMY OF THE PECTORAL GIRDLE

### Clavicle

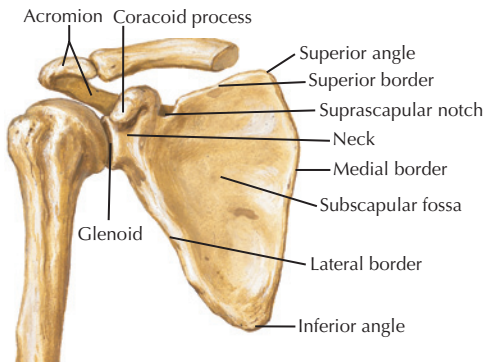
- Parts and landmarks: sternal end/facet, impression for costoclavicular ligament, shaft (body), conoid tubercle, trapezoid line, subclavian groove, acromial end/facet

### Scapula

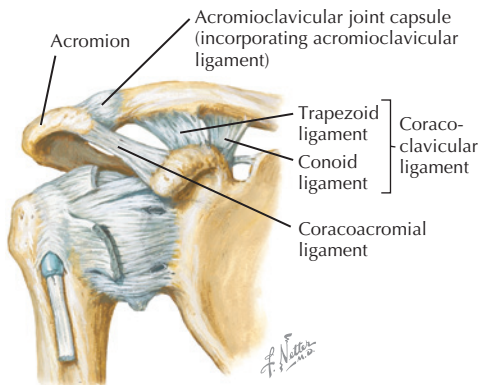
- Parts: glenoid fossa (cavity) supraglenoid tubercle, infraglenoid tubercle, neck, coracoid process, suprascapular notch, superior border, superior angle, medial border, inferior angle, lateral border, subscapular fossa, spine, acromion, supraspinous fossa, infraspinous fossa

### Pectoral Girdle and Shoulder Joints

- Sternoclavicular joint
  - Synovial, with articular disc (dual axes of movement)
  - Extremely strong: only joint attaching upper-limb girdle to the axial skeleton
- Acromioclavicular (AC) joint
  - Synovial, gliding/plane
  - Supported by acromioclavicular ligament
  - Acts as a pivot point to increase range of arm motion (raise arm over head)

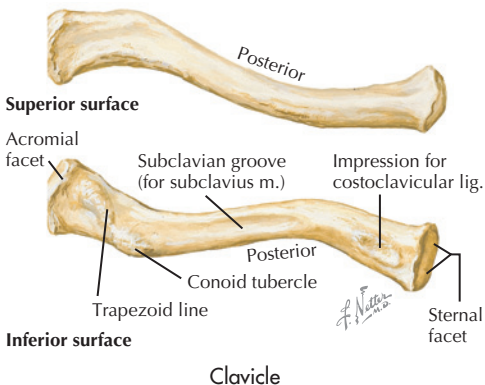


Shoulder joint, anterior view



Shoulder Bones and Ligaments

## Right clavicle



- Glenohumeral joint (also covered in [Chapter 23, Humerus Fractures](#))
  - Synovial, ball and socket with labrum
  - Basis for upper limb positioning and transmission of forces to pectoral girdle
  - Involved in glenoid fractures (intraarticular)
  - Biceps (long) tendon inserts on supraglenoid tubercle
  - Triceps (long) tendon inserts on infraglenoid tubercle

## Ligaments

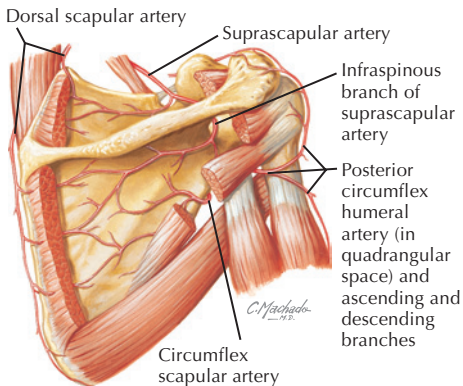
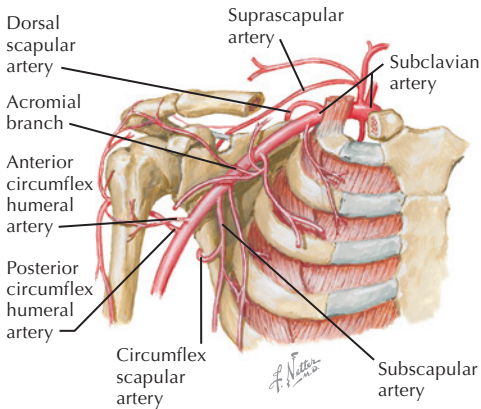
- Coracoclavicular ligament
  - Very strong, two-part
  - Shares forces between clavicle and scapula

- Trapezoid: nearly horizontal, attaches to conoid tubercle and superior surface of coracoid
- Conoid: nearly vertical inverted triangle, attaches to coracoid root
- Parts may be separated by bursa.
- Base for supporting scapula and upper limb on the clavicular “strut”
- Acromioclavicular ligament: strengthens AC joint superiorly
- Coracoacromial ligament: limits superior displacement of humeral head
- Costoclavicular ligament
  - Strong
  - Attaches near head of clavicle to 1st costal cartilage
  - Reinforces sternoclavicular joint, prevents displacement of clavicle

## NEUROVASCULAR SUPPLY

### Arterial Supply

- Subclavian artery provides numerous branches, forming anastomoses around the scapula, glenohumeral joint, and proximal humerus.
  - Dorsal scapular artery
    - ▲ Runs from base of neck along vertebral border of scapula
    - ▲ Anastomoses with medial suprascapular branches
  - Suprascapular artery
    - ▲ From mid-subclavian to scapula above transverse scapular ligament, above suprascapular notch
    - ▲ Has supraspinous and infraspinous branches to respective fossae



Subclavian and Axillary Artery Anastomoses

- Axillary artery
  - ▲ Thoracoacromial artery
  - ▲ Posterior humeral circumflex artery (in quadrangular space)
  - ▲ Subscapular artery, circumflex scapular branch; anastomoses with dorsal scapular and suprascapular branches

### Venous Drainage

- Veins of pectoral and scapular regions run parallel to the subclavian and axillary arteries and their major branches: valved, arterial counterpulsation effect pumps blood.
- Superficial tributaries
  - Cephalic vein: travels superficial to biceps to empty into axillary vein
  - Basilic vein: from superficial forearm and distal arm, empties into axillary vein
- Deep tributaries
  - Axillary vein
    - ▲ Brachial vein
- Axillary vein continues into subclavian vein.
- Axillary vein lies superficial to axillary sheath and parts of brachial plexus.
- Dorsal scapular veins drain into scapular circumflex, subscapular (axillary) tributaries, and dorsal scapular suprascapular (subclavian) tributaries.

### Nerves

#### *Brachial Plexus*

- Vital nerves for upper limb pass deep to clavicle.



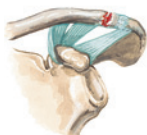- Roots
  - C5-T1 anterior rami, arise in the neck at the levels of their vertebral foramina
  - Supraclavicular level
- Trunks
  - Superior (C5, C6), middle (C7), inferior (C8-T1) arise from union of roots
  - Supraclavicular level
  - Nerve to subclavius: off superior trunk
  - Suprascapular nerve: to supraspinatus and infraspinatus; off superior trunk
- Divisions
  - Anterior and posterior portions of each trunk
  - Clavicular level: at risk in medial fractures
- Cords: infraclavicular level
  - Lateral: anterior divisions of superior and middle trunks
  - Medial: anterior divisions of inferior trunk
  - Posterior: posterior divisions only of all 3 trunks
- Terminal nerve branches: infraclavicular level
- See [Chapter 23, Humerus Fractures](#), for more information

## CLINICAL CORRELATES

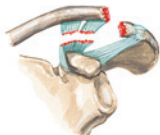### Scapula Fractures

- Uncommon, <1% of all fractures
- Typically associated with other injuries
- Historically treated with closed reduction, with poor results with displacement
- Types: acromial, coracoid
- Glenoid fractures (Ideberg types)
  - Type I: anterior avulsion
  - Type II: transverse/oblique through glenoid, inferior exit

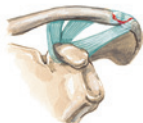
## Fractures of lateral third of clavicle



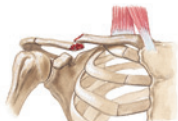**Type I.** Fracture with no disruption of ligaments and therefore no displacement.



**Type II.** Fracture with tear of coracoclavicular ligament and upward displacement of medial fragment. Requires open repair.



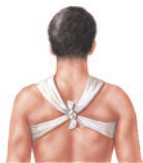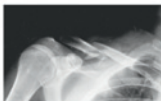**Type III.** Fracture through acromioclavicular joint; no displacement. Often missed and may later cause painful osteoarthritis requiring resection arthroplasty.



**Fracture of middle third of clavicle** (most common). Medial fragment displaced upward by pull of sternocleidomastoid muscle; lateral fragment displaced downward by weight of shoulder. Fractures occur most often in children.

*F. Netter M.D.*

Anteroposterior radiograph. Fracture of middle third of clavicle



Fracture of middle third of clavicle best treated with snug figure-of-8 bandage or clavicle harness for 3 weeks or until pain subsides. Bandage or harness must be tightened occasionally because it loosens with wear.

**Healed fracture of clavicle.** Even with proper treatment, small lump may remain.

## Clavicular Fractures

- Type III: oblique through glenoid, superior exit
- Type IV: transverse fracture through scapular body
- Type V: types II + IV

## Clavicle Fractures

- Typically result from a direct fall onto the shoulder
- Most commonly involve the middle third
- Typically stable and tend to heal well with low risk of non-union
- High-energy injuries and open fractures more commonly associated with non-union and neurovascular injury (e.g., to subclavian artery or brachial plexus)

This page intentionally left blank

# 23

## Humerus Fractures

### ANATOMY OF THE HUMERUS

#### Humerus

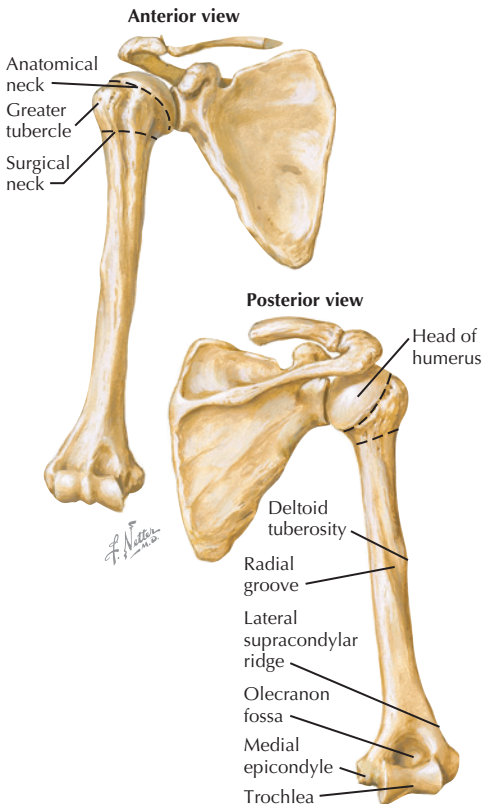
- Parts and landmarks: head, greater tubercle (tuberosity), lesser tubercle, intertubercular sulcus (bicipital groove), anatomical neck, surgical neck, deltoid tuberosity, radial groove, medial supracondylar ridge and epicondyle, lateral supracondylar ridge and epicondyle, trochlea, capitulum

#### Glenohumeral Joint

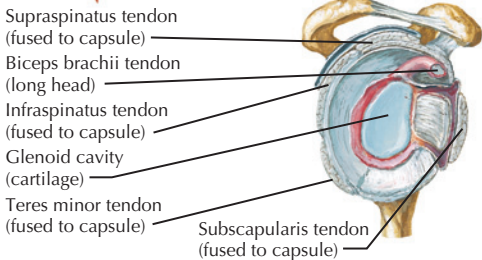
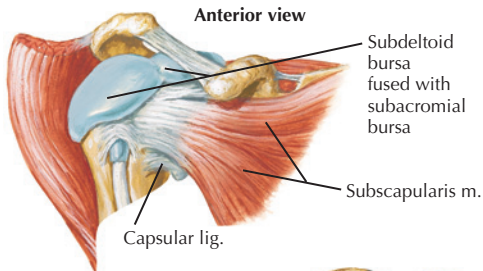
- Shallow, synovial ball-and-socket joint
- Supported by musculotendinous rotator cuff, composed of subscapularis, supraspinatus, infraspinatus, and teres minor fibers and tendons
- Fibrocartilaginous glenoid labrum effectively deepens glenoid fossa.
- Complex subdeltoid and subacromial bursae can communicate (pathologically) with joint cavity.
- Long tendon of biceps (long head) passes in a synovial tunnel through the superior joint capsule to a supraglenoid tubercle insertion.

#### Elbow Joint

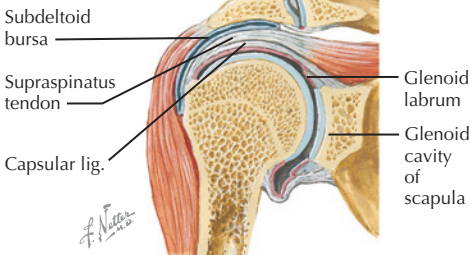
- Distal humerus can be viewed as having diverging medial and lateral columns, with functionally independent joints.
  - Trochlea
    - ▲ Termination of medial column
    - ▲ Articulates with ulna: flexion and extension



Humerus and Pectoral Girdle



**Coronal section through joint**



**Shoulder Joint and Ligaments**

- Capitulum
  - ▲ Termination of lateral column
  - ▲ Articulates with radius: rotation
- See also “[Elbow Joint](#)” in [Chapter 24, Forearm Fractures](#)

## Compartments of the Arm

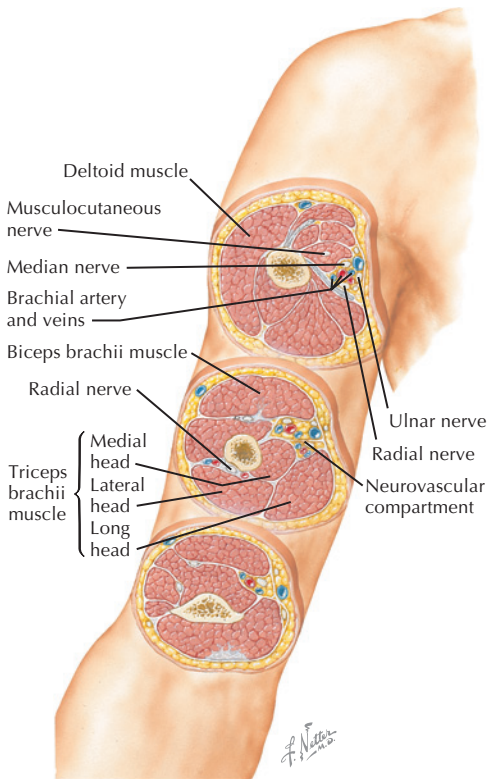
- Upper arm
  - Lateral (deltoid, abductor): axillary nerve
  - Anterior (biceps, flexor): musculocutaneous nerve
  - Posterior (triceps, extensor): radial nerve
- Lower arm: anterior (biceps) and posterior (triceps)
- External investing brachial fascia is relatively tough.
- Brachial plexus and its nerves lie medially, between superior anterior and posterior compartments.

## VESSELS AND NERVES

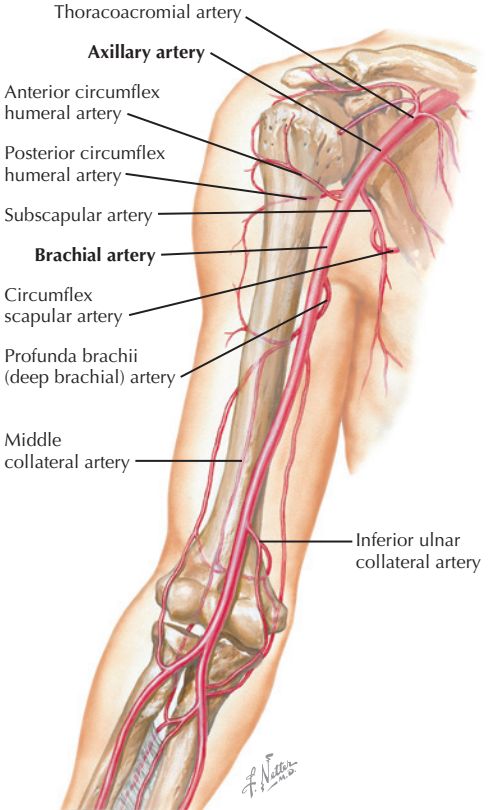
### Arterial Supply

- Subclavian artery provides numerous branches, forming anastomoses around scapula, glenohumeral joint, and proximal humerus.
  - Dorsal scapular artery runs from base of neck along vertebral border of scapula.
  - Suprascapular artery
    - ▲ From mid-subclavian to scapula above transverse scapular ligament, above suprascapular notch
    - ▲ Has supraspinous and infraspinous branches to respective fossae





Arm: Serial Cross Sections



Arm: Brachial Artery and Anastomoses

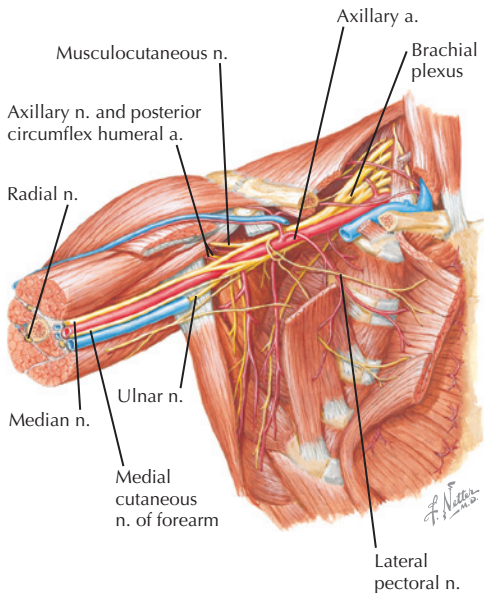
- Axillary artery (continuation into axilla)
  - ▲ Anterior humeral circumflex
  - ▲ Posterior humeral circumflex
  - ▲ Subscapular artery, circumflex scapular branches: anastomotic with dorsal scapular and suprascapular branches of subclavian
  - ▲ Brachial artery: continuation of main vessel into the distal arm and cubital region; branches: deep brachial (profunda brachii), radial artery, ulnar artery, collaterals

## Veins of the Arm

- Deep veins run parallel to axillary and brachial arteries and their major branches, often twin veins beside arterial branches.
- Valved: arterial counterpulsation effect pumps blood heartward
- Deep and superficial drainages connect.
- Superficial tributaries
  - Cephalic vein: from lateral forearm, travels superficial to biceps to empty into axillary vein
  - Basilic vein: from superficial forearm and distal arm; empties into axillary vein
- Deep tributaries: axillary vein, brachial vein
- Axillary vein continues into subclavian vein.
- Axillary vein lies superficial to axillary sheath and parts of brachial plexus.

## Nerves of the Arm

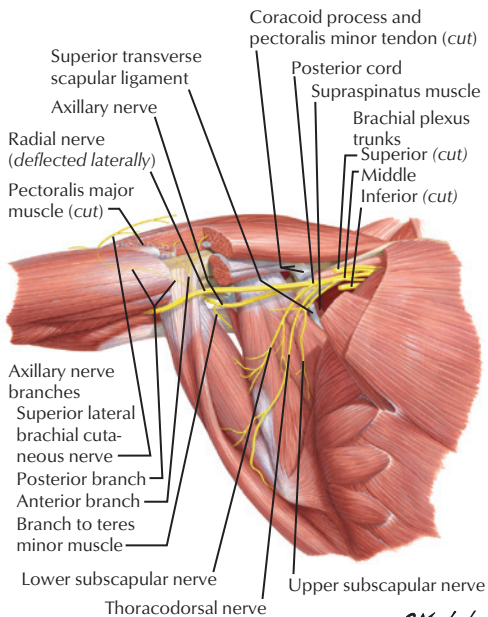
- Hilton's law: nerves supplying a joint also innervate muscles acting across it, as well as skin over distal insertions of those muscles



### Arm: Brachial Plexus and Vascular Relationships

#### *Brachial Plexus*

- Roots
  - Anterior rami of C5, C6, C7, C8, T1
  - Supraclavicular, in neck
- Trunks
  - Superior (C5+C6), middle (C7), inferior (C7+T1)
  - Supraclavicular, in neck



C. Machado  
— M.D.

## Brachial Plexus: Muscular Relationships

- Divisions
  - Anterior (flexor) and posterior (extensor) from each trunk
  - Clavicular level
- Cords: named by position around the axillary artery (2nd part)
  - Lateral: anterior divisions of superior and middle trunks
  - Medial: anterior divisions of inferior trunk
  - Posterior: posterior divisions only of all 3 trunks
- Cords and terminal nerve branches of brachial plexus lie anteromedial to glenohumeral joint in axilla.
- Musculocutaneous nerve: leaves lateral cord immediately to enter coracobrachialis, then travel distally deep to biceps
- Lateral and medial pectoral nerves: from lateral and medial cords, respectively
- Radial nerve (posterior cord): tightly applied to posterior and lateral humerus in radial groove, deep to medial head of triceps
- Dislocation or proximal fractures can damage cords, axillary, or radial nerves.

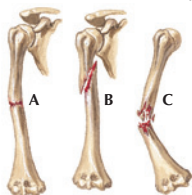
## CLINICAL CORRELATES

### Compartment Syndrome

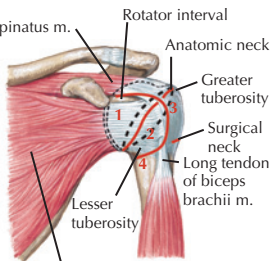
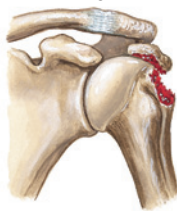- Displaced supracondylar humeral fracture: most common cause of upper limb compartment syndrome

### Humerus Fractures

- Classified by location, 3 general types



- A. Transverse fracture of midshaft  
 B. Oblique (spiral) fracture  
 C. Comminuted fracture with marked angulation

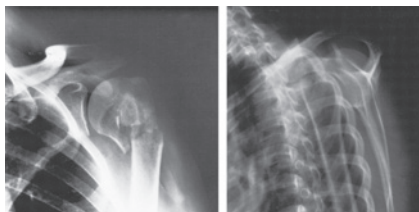


Subscapularis m.








Neer four-part classification of fractures of proximal humerus.  
 1. Articular fragment (humeral head).  
 2. Lesser tuberosity. 3. Greater tuberosity. 4. Shaft. If no fragments displaced, fracture considered stable (most common) and treated with minimal external immobilization and early range-of-motion exercise.

*F. J. Netter M.D.*

Displaced fracture of greater tuberosity surgically repaired using wires through small drill holes and suturing cuff tears. Small fragment may be excised and supraspinatus tendon reattached



## Fractures of the Humerus

| 2 Part   | 3 Part   | 4 Part  |
|--|--|---|
| Anatomical neck<br>     |  |   |
| Surgical neck<br>       |  |   |
| Greater tuberosity<br> | Greater tuberosity<br> | Greater and lesser tuberosity<br><br><br>JOHN A. CRAIG MD |
| Lesser tuberosity<br> | Lesser tuberosity<br> |   |

Neer Classification of Proximal Humerus Fractures



### *Proximal Humerus Fractures*

- Common injuries
  - In elderly persons with osteoporosis, following a fall
  - In younger persons, with high-energy impact
- May be associated with dislocations of humeral head
- Can involve humeral head, greater tuberosity, lesser tuberosity, and shaft
- Fracture patterns can be classified (Neer) by number of parts displaced  $>1$  cm or angulated  $>45^\circ$
- Proximal fractures and dislocations risk injury to axillary nerve, passing through quadrangular space at surgical neck of humerus.
- Two-part fractures, involving anatomical neck above tuberosities, split head and risk avascular necrosis from disrupted supply.

### *Humeral Shaft Fractures*

- Typically result from direct trauma, falls, penetrating wounds, vehicular accidents
- Neurovascular assessment necessary: radial nerve injury can result from primary injury or manipulation
- *Compartment syndromes* can easily occur.

### *Distal Humerus Fractures*

- Supracondylar
  - Extraarticular, through metaphysis
  - Rare in adults
  - Mechanism extension ( $>80\%$ ) or flexion
  - Imaging should be studied for intercondylar extension.

- Transcondylar
  - Primarily occur in elderly persons with osteopenia, with or without intercondylar extension
  - Most common distal humerus fracture in adults
  - May be displaced owing to muscle pulls
- Condylar; very rare in adults, more commonly lateral (involving capitulum)
- Supracondylar fracture treatment
  - Open reduction with internal fixation preferred
  - Closed reduction in children

# 24

## Forearm Fractures

### ANATOMY OF THE FOREARM

#### Ulna

- Parts and landmarks: olecranon, trochlear notch, coronoid process, shaft, anterior border, styloid process
- Cylindrical long bone; olecranon palpable subcutaneously at elbow joint; (medial) styloid process distal
- Bears major forces transmitted across elbow joint

#### Radius

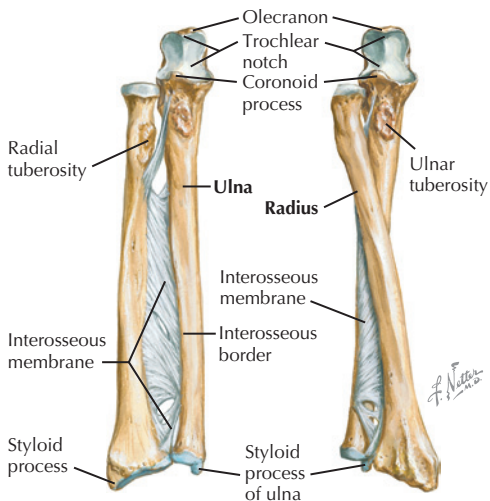
- Parts and landmarks: head, neck, radial tuberosity, shaft, styloid process, carpal articular fossa, scaphoid fossa, lunate fossa, ulnar notch
- Cylindrical long bone with head in elbow joint; (lateral) styloid process distal
- Radiocarpal joint has articular disc that articulates with carpals and ulnar styloid process.
- Bears major forces transmitted across wrist joint

#### Elbow Joint

- Compound joint involving humeral-radial, humeral-ulnar, and proximal radioulnar joints
  - Medial: trochlea of humerus with trochlear notch of the ulna
  - Median: proximal radioulnar joint
  - Lateral: capitulum of humerus with head of radius

**Right radius and ulna in supination: anterior view**

**Right radius and ulna in pronation: anterior view**



### Forearm Bones

- Ulnar (medial) collateral ligament: from medial epicondyle of humerus to (1) coronoid process and (2) medial olecranon
- Annular ligament passes around radial neck, stabilizing it via insertions into the ulna.
- Lateral (radial) collateral ligament passes from lateral epicondyle (humerus) to annular ligament.

- Large fibrous joint capsule underlies collateral ligaments.

## Compartments of the Forearm

- External investing antebrachial fascia is relatively tough and nonexpansile, with fascial septa between compartments.
- Proximal forearm
  - Anterior (flexors, pronators)
    - ▲ Median nerve, to all flexors *except* flexor carpi ulnaris and 2 medial heads of flexor digitorum superficialis (ulnar nerve supplied)
    - ▲ Anterior interosseus nerve (deep branch median) innervates distal pronator quadratus and flexor pollicis longus.
  - Interosseus membrane separates deep anterior and posterior compartments.
  - Posterior (extensor): radial nerve > deep radial and posterior interosseus nerves
- Lower forearm: flexor digitorum superficialis and profundus tendons, flexor pollicis longus, pronator quadratus
- Spaces around flexor digitorum tendons and sheaths communicate with hand spaces: pathway for forearm-hand compartment syndrome.
- Dorsal antebrachial spaces communicate with dorsal hand and digit spaces.

## VESSELS AND NERVES

### Arterial Supply of the Forearm

- Brachial artery
  - Typically divides into main radial and ulnar artery branches in cubital fossa

Radial a. and superficial branch of radial n.

Radius

Ulnar a. and median n.

Superficial flexor muscles

Deep flexor muscles

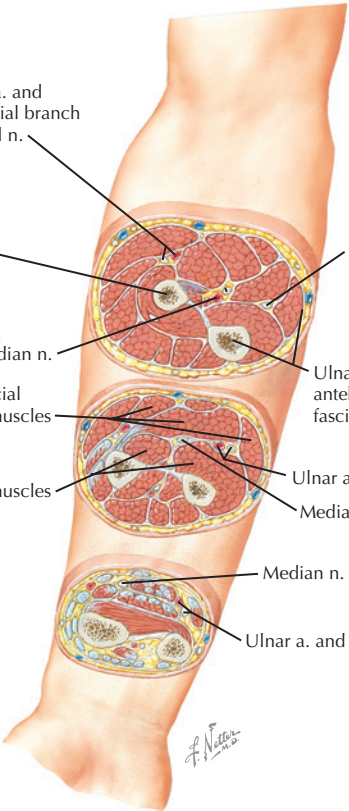
Ulnar n.

Ulna and antebrachial fascia

Ulnar a. and n.  
Median n.

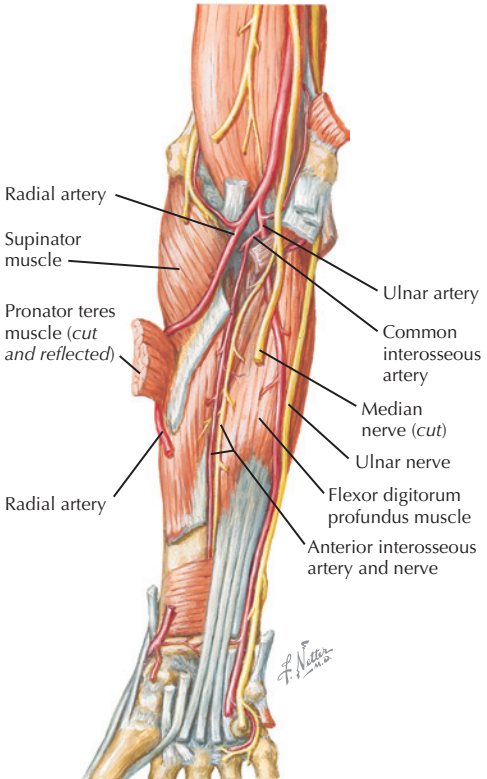
Median n.

Ulnar a. and n.



Forearm: Serial Cross Sections

## Deep neurovascular plane of the forearm



Forearm: Arteries and Nerves (Anterior View)

- Ulnar typically gives rise to common interosseus artery, with its anterior and posterior interosseus branches.
- Anastomoses between upper (collateral) and lower (recurrent) branches preserve blood flow across elbow joint, with both anterior and posterior connections from medial and lateral vessels.
- Lateral anastomoses
  - Anterior: radial collateral branch (profunda brachii) with radial recurrent branch (radial)
  - Posterior: middle collateral branch (profunda brachii) with recurrent interosseous branch (typically posterior interosseous)
- Medial anastomoses
  - Anterior: inferior ulnar collateral (brachial) with anterior ulnar recurrent (ulnar)
  - Posterior: superior ulnar collateral (brachial) with posterior ulnar recurrent (ulnar)
- Distally, main radial and ulnar arteries pass through deep anterior forearm laterally and medially (respectively) to enter wrist and palm.

### Veins of the Forearm

- Highly interconnected superficial and deep vein networks drain hand and forearm
- Superficial venous network
  - Originates in dorsal venous arch of hand
  - Cephalic vein: distal, at lateral wrist, runs the length of upper limb to pectoral triangle
  - Basilic vein: distal, at medial wrist, runs most of the length of upper limb to arm
  - Highly individual patterns of interconnections between cephalic and basilic tributaries



- Deep veins accompany corresponding arteries: valved, arterial counterpulsation effect pumps blood.
  - Brachial vein
    - ▲ Accompanies brachial artery
    - ▲ Merges with basilic vein to form axillary vein
    - ▲ Tributaries: ulnar and radial veins accompanying artery branches

## Nerves of the Forearm

- Hilton's law: nerves supplying a joint also innervate muscles acting across it, as well as skin over distal insertions of those muscles

### *Median Nerve (C6-T1)*

- Enters the forearm anteromedially at elbow and passes through pronator teres
- Deep portion, anterior interosseus nerve, travels in neurovascular bundle along interosseus membrane to pronator quadratus.
- Main portion travels along lateral border of flexor digitorum profundus, passing under flexor retinaculum, entering palm via carpal tunnel.
- Neurovascular plane of anterior forearm lies between flexor digitorum superficialis and profundus.

### *Ulnar Nerve (C7-T1)*

- Passes posterior to medial epicondyle of humerus, within the cubital tunnel, to penetrate flexor carpi ulnaris near its origin
- Passes distally in forearm in the neurovascular plane, along medial aspect of flexor digitorum profundus

- Enters the palmar space by passing lateral to the flexor carpi ulnaris tendon and pisiform bone

### *Radial Nerve (C5-T1)*

- Passes anterior to lateral epicondyle of humerus after traversing radial groove of humerus
- Posterior cutaneous nerve of forearm arises proximal to condyle.
- Superficial radial nerve (sensory) travels on surface of supinator, deep to brachioradialis and tendon, and supplies area on dorsum and eminence of thumb and lateral back of hand.
- Main nerve enters posterior compartment of forearm by penetrating supinator.
- Deep radial nerve exits supinator and travels distally as posterior interosseous division.
  - Proximal and distal deep branches to distal extensor compartment muscles

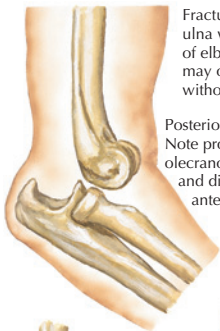
## **CLINICAL CORRELATES**

### **Antebrachial Compartment Syndrome**

- Distal radius, ulna, or carpal fractures and related tissue and vascular trauma can lead to increased compartment pressure(s), swelling, pain, or paresthesias.
- Anterior (volar) forearm is relatively prone to developing posttraumatic compartment syndrome.
- Causes: fractures of supracondylar humerus, ulna, radius, wrist

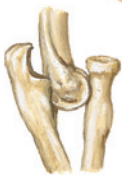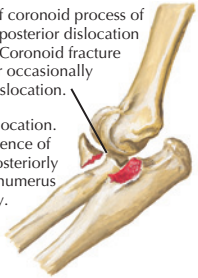
### **Elbow Dislocations**

- Often associated with proximal ulna fractures involving coronoid process or olecranon

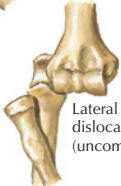

Fracture of coronoid process of ulna with posterior dislocation of elbow. Coronoid fracture may occur occasionally without dislocation.

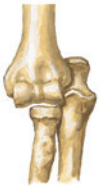Posterior dislocation. Note prominence of olecranon posteriorly and distal humerus anteriorly.



Divergent dislocation, anterior-posterior type (rare). Medial-lateral type may also occur (extremely rare).

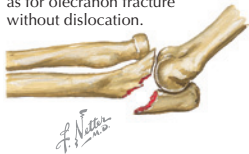


Lateral dislocation (uncommon)

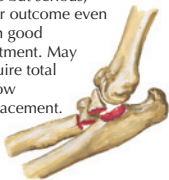

Medial dislocation (very rare)

Anterior dislocation of radius and ulna with fracture of olecranon. Reduced and fixed as for olecranon fracture without dislocation.

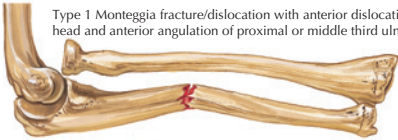


Posterior dislocation with fracture of both coronoid process and radial head. Rare but serious; poor outcome even with good treatment. May require total elbow replacement.

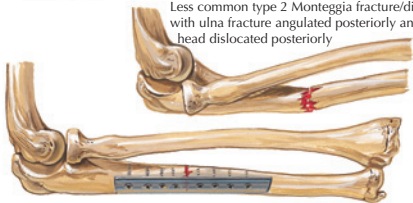


## Elbow Dislocation


Type 1 Monteggia fracture/dislocation with anterior dislocation of radial head and anterior angulation of proximal or middle third ulna fracture



Less common type 2 Monteggia fracture/dislocation with ulna fracture angulated posteriorly and radial head dislocated posteriorly



Fracture of ulna treated with open reduction and internal fixation using compression plate and screws. After reduction of ulna, radial head spontaneously reduced



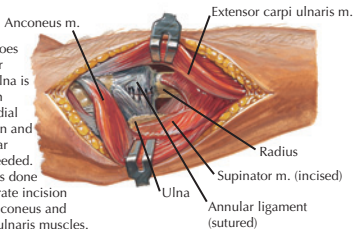
Preoperative radiograph shows Type I Monteggia fracture/dislocation

*F. Natter*  
with  
C.A. Luce

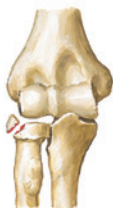

Postoperative radiograph shows compression plate in place

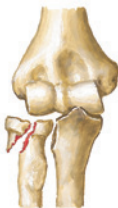If radial head does not reduce after angulation of ulna is corrected, open reduction of radial head dislocation and repair of annular ligament are needed. Typically, this is done through a separate incision between the anconeus and extensor carpi ulnaris muscles.



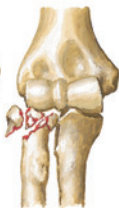## Fractures of the Ulnar Shaft



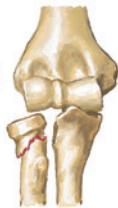Small chip fracture of radial head



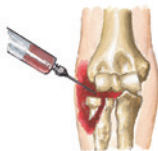
Large fracture of radial head with displacement



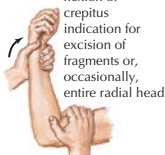Comminuted fracture of radial head



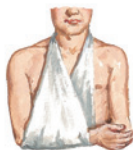Fracture of radial neck, tilted and impacted



Hematoma aspirated, and 20-30 mL of xylocaine injected to permit painless testing of joint mobility

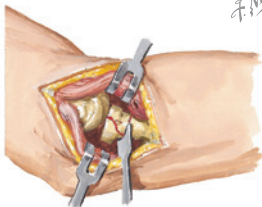


Elbow passively flexed. Blocked flexion or crepitus indication for excision of fragments or, occasionally, entire radial head



Small fractures without limitation of flexion heal well after aspiration with only sling support.

*F. Natter*  
M.D.

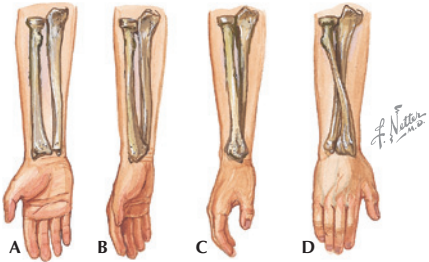


Excision of fragment or entire radial head via posterolateral incision. Radial head may be replaced with Swanson silicone implant in selected patients.

Comminuted fracture of radial head with dislocation of distal radioulnar joint, proximal migration of radius, and tear of interosseous membrane (Essex-Lopresti fracture)

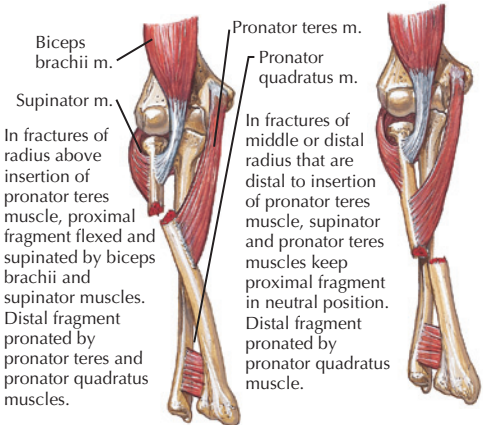


## Fractures of Radial Head and Neck



Tuberosity of radius useful indicator of degree of pronation or supination of radius

- A.** In full supination, tuberosity directed toward ulna
- B.** In about 40° supination, tuberosity primarily posterior
- C.** In neutral position, tuberosity directly posterior
- D.** In full pronation, tuberosity directed laterally



Biomechanics of Forearm Fracture

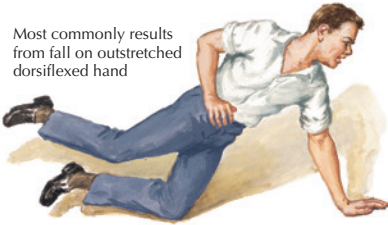
- Radial head may be involved with coronoid in posterior displacements and fractures: open reduction and fixation is preferred treatment in adults.

## Ulna and Radius Fractures

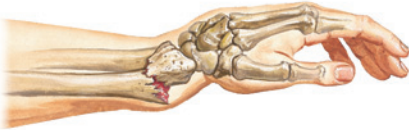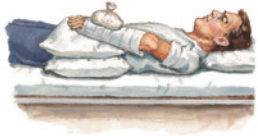- Proximal
  - Olecranon: direct trauma or fall onto outstretched hand with triceps contraction
  - Radial head: direct trauma or fall with impaction of radial head into capitulum
  - Assess neurovascular deficits with history and physical exam.
- Mid-forearm
  - Diaphyseal fractures of ulna and radius often occur together, with forearm deformity
  - Monteggia: mid-ulnar fracture with angulation and radial dislocation
  - Galeazzi: radial diaphysis fracture with disruption of distal radioulnar joint
  - Open reduction and fixation preferred treatment in adults, with Monteggia and Galeazzi “fractures of necessity”
- Distal
  - Radius: *Colles fracture*, proximal to styloid process, with dorsal deviation of distal fragment(s) and wrist

*See next page*

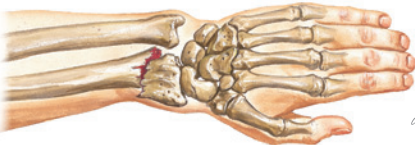
Most commonly results from fall on outstretched dorsiflexed hand



Immediate prehospital care: limb splinted, wrist elevated above level of heart on pillows or folded garment, ice pack applied



Lateral view of Colles fracture demonstrates characteristic dinner fork deformity with dorsal and proximal displacement of distal fragment. Note dorsal instead of normal volar slope of articular surface of distal radius.



Dorsal view shows radial deviation of hand with ulnar prominence of styloid process of ulna and decrease of reverse of normal radial slope of articular surface of distal radius.

### Colles Distal Radial Fracture



## ANATOMY OF THE WRIST AND HAND

### Carpal Bones: Lateral to Medial

- Proximal
  - Scaphoid, lunate, triquetrum, pisiform
- Distal
  - Trapezium, trapezoid, capitate, hamate

### Metacarpals

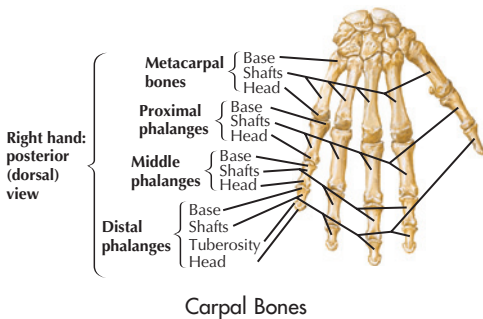
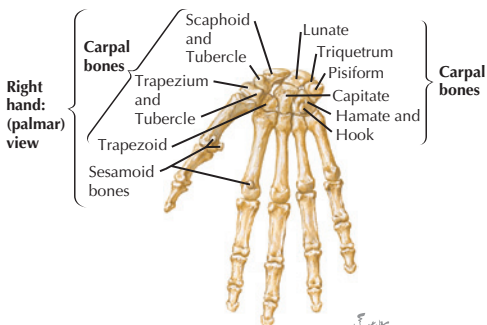
- Numbered I/1 (thumb) to V/5 (digiti minimi)
- Parts: base, shaft, head
- Shafts triangular in cross section
- V/5 most commonly fractured metacarpal

### Phalanges

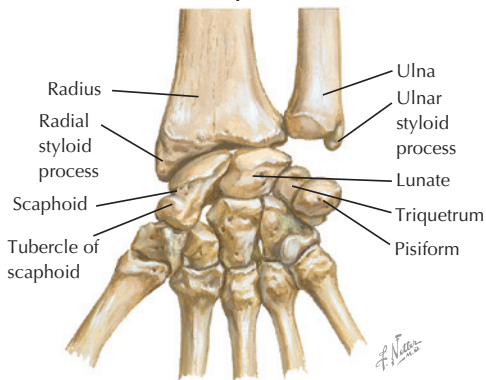
- Proximal, middle, distal (3) in each finger
- Proximal, distal (2) in thumb
- Parts: base, shaft, tuberosity (in distal phalanges), head
- Distal phalanx 3 common fracture

### Joints of Wrist and Hand

- Radiocarpal (RC) joint
  - Synovial joint between distal radius and articular disc (concave) and scaphoid, lunate, and triquetrum (convex)
  - Allows movement around 2 axes: flexion/extension, adduction/abduction (ulnar and radial deviation, respectively)



### Anterior (palmar) view



### Bones of Wrist and Hand

- Carpal joints
  - Synovial joints between carpals
  - Share common joint cavity
  - Limited movement contributes to positioning of hand, grasp
- Carpometacarpal (CM) joints
  - Synovial, between distal row of carpal bones and 5 metacarpal bases
  - Saddle joint between trapezium and thumb metatarsal more mobile than others: flex/extend, abduct/adduct, rotate, circumduct
  - CM joints II-V
    - ▲ Synovial arthrodial/gliding
    - ▲ Range of movement increases medially: metacarpal 5 greatest.

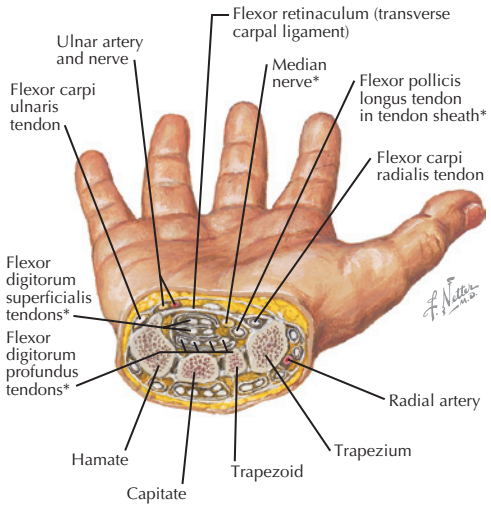
- Joint capsules reinforced by palmar and dorsal ligaments and medial and lateral collateral ligaments
- Metacarpophalangeal (MCP) joints
  - Synovial condylar
  - Between metacarpal heads and proximal phalanges
  - Joint capsules reinforced by palmar ligaments and medial and lateral collateral ligaments
- Interphalangeal joints
  - Synovial hinge
  - Supported by palmar and medial, lateral collateral ligaments

### Ligaments of Wrist and Hand

- Supporting wrist (RC) joint: palmar radiocarpal, palmar ulnocarpal, dorsal radiocarpal ligaments
- Flexor retinaculum (transverse carpal ligament) runs proximally between scaphoid (tubercle) and triquetrum and distally between trapezium (tubercle) and hamate (hook) and forms carpal tunnel.
- Multiple small ligaments run between adjoining carpal bones on their palmar and dorsal surfaces, reinforcing carpal joints.
- Deep transverse metacarpal ligaments: palmar bands interconnecting MCP palmar ligaments

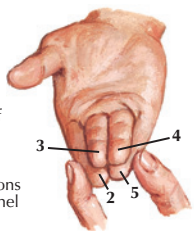
### Wrist and Hand Compartments

- Carpal tunnel
  - Space between flexor retinaculum and carpal bones
  - Contains flexors digitorum superficialis and profundus tendons, sheaths, and *median nerve*

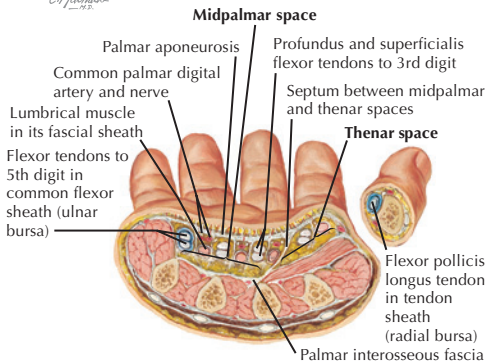
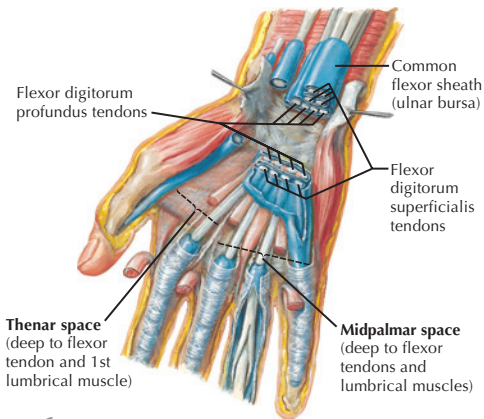


\*Contents of carpal tunnel

Simple method of demonstrating arrangement of flexor digitorum superficialis tendons within carpal tunnel



Transverse Section of Wrist Demonstrating Carpal Tunnel



Bursae, Spaces, and Tendon Sheaths of Hand

- Forearm spaces around flexor digitorum tendons communicate with hand spaces and are pathways for forearm–hand compartment syndrome.
- Mid-palmar space: between flexor digitorum tendons and metacarpals/interosseous muscles
- Thenar space: between flexor pollicis tendon and adductor pollicis
- Hypothenar compartment: defined by hypothenar muscle fascia (abductor, flexor brevis, opponens digiti minimi)
- Interosseous compartment: defined by interosseous muscle fascia and metacarpals
- Ulnar bursa: common flexor tendon sheath runs from distal forearm through palm and into fifth digital tendon sheath (or more digits)
- Radial bursa: tendon sheath around flexor pollicis longus travels into thumb
- Dorsal antebrachial spaces communicate with dorsal hand and digit spaces, between extensor tendons and dorsal interossei.

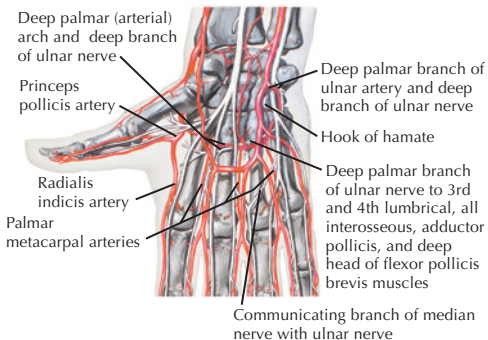
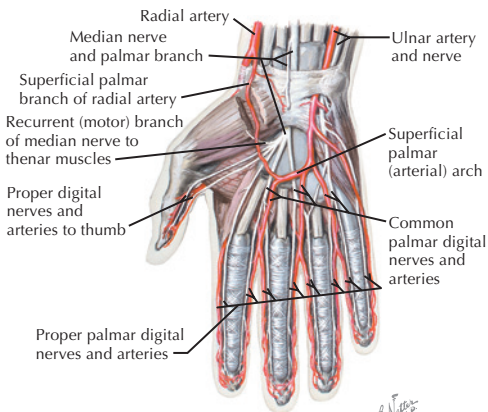
## **VESSELS AND NERVES**

### **Arterial Supply**

- Distal ulnar (medial) and radial (lateral) arteries contribute to anastomotic vascular arches in the palmar spaces.
- Anastomoses between arches and other distal antebrachial branches of ulnar and radial arteries

### *Superficial Palmar Arch*

- Terminal branch of ulnar artery and superficial branch of radial artery



## Wrist and Hand: Vessels and Nerves



- Branches
  - Common palmar digital arteries (3)
  - Bifurcate and form proper palmar digital arteries II-V
  - Proper palmar digital artery V, medial side

### *Deep Palmar Arch*

- Terminal branch of radial artery and deep branch of ulnar artery
- Branches
  - Princeps pollicis
    - ▲ Radialis indicis
    - ▲ Proper digital artery of thumb
  - Palmar metacarpal arteries (3)

### **Venous Drainage**

- Networks of superficial and deep veins interconnect.
- Deep veins run with major arterial branches of palmar arches and ulnar and radial arteries.
- Superficial veins drain into venous network on dorsum of hand.
- Cephalic vein originates from lateral side of dorsal venous network and passes into lateral forearm via anatomical snuffbox.
- Basilic vein originates from medial side of the dorsal venous network and passes into dorsomedial forearm.

### **Nerves**

#### *Median Nerve*

- Enters palmar space via carpal tunnel
- Intermingled with deep and superficial flexor digitorum tendons

- Recurrent branch
  - Arises in carpal tunnel
  - Supplies thenar muscles
- Common palmar digital nerves
  - Innervate lumbricals 1 and 2
  - Branch into proper palmar digital nerves that run along sides of digits 1-3 and lateral aspect of digit 4

### *Ulnar Nerve*

- Enters palmar space by passing lateral to pisiform bone (Guyon's canal) and around hook of hamate
- Deep branch accompanies deep branch of ulnar artery, penetrates and supplies hypothenar muscles, and arches across palm to supply interossei, 2 medial lumbricals, adductor pollicis, and articular branches to wrist.
- Superficial branch
  - Gives rise to common palmar digital nerve: innervates lumbricals 3 and 4
  - Branches into proper palmar digital nerves that run along sides of digit 5 and medial aspect of digit 4

### *Radial Nerve*

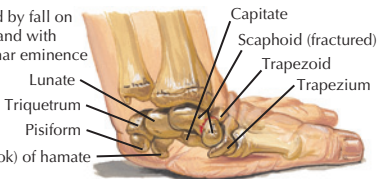
- Superficial branch only part to run distally onto hand
- Enters via anatomical snuffbox
- Sensory to lateral thenar eminence and dorsum of hand to middle of digits 1-3

## **CLINICAL CORRELATES**

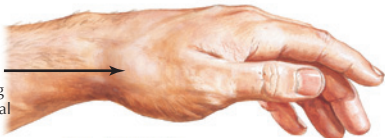### **Compartment Syndrome**

- Distal radius, ulnar, or carpal fractures and related tissue and vascular trauma can lead to

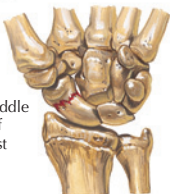Usually caused by fall on outstretched hand with impact on thenar eminence



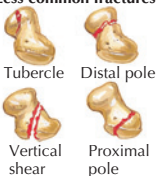
Clinical findings: pain, tenderness, and swelling in anatomical snuffbox



Fracture of middle third (waist) of scaphoid (most common)

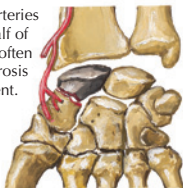


**Less common fractures**



*F. J. Netter M.D.*

Because nutrient arteries only enter distal half of scaphoid, fracture often results in osteonecrosis of proximal fragment.



**Fracture of the Scaphoid**

increased compartment pressure(s), swelling, pain, and paresthesias.

- Carpal tunnel syndrome
  - Median nerve compressed with superficial and deep flexor tendons
  - Flexor retinaculum release procedure may be indicated.
- Posttraumatic or reperfusional trauma can cause swollen hand from pressure in subcompartments (e.g., interossei, adductor pollicis).

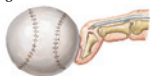### Scaphoid Fractures

- Most common carpal fracture
- Typically caused by a fall on an outstretched hand, with weight on thenar eminence
- Fracture of the waist (mid 1/3) most common
- Pain and swelling in anatomical snuffbox is often seen.
- Adequate healing depends on blood supply from palmar carpal branch of radial artery.

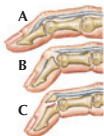
### Metacarpal and Phalangeal Fractures

- Phalangeal and metacarpal fractures are common.
- Border digits are most commonly involved.
- Mechanisms include bending and torsion (common in sports).
- Crushing injuries often are associated with complex soft tissue injuries.
- 30%-50% open, more than half of these work related

## Mallet finger

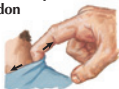

Usually caused by direct blow on extended distal phalanx, as in baseball, volleyball

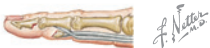

Degrees of mallet finger injury. **A.** Extensor tendon stretched but not completely severed; mild finger drop and weak extensor ability retained. **B.** Tendon torn from its insertion. **C.** Bone fragment avulsed with tendon. In **B** and **C** there is 40-45° flexion deformity and loss of active extension.

## Avulsion of flexor digitorum profundus tendon



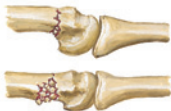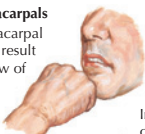
Caused by violent traction on flexed distal phalanx, as in catching on jersey of running football player



Flexor digitorum profundus tendon may be torn directly from distal phalanx or may avulse small or large bone fragment. Tendon usually retracts to about level of proximal interphalangeal joint, where it is stopped at its passage through flexor digitorum superficialis tendon; occasionally, it retracts into palm.

## Fracture of metacarpals

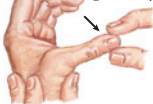Fractures of metacarpal neck commonly result from end-on blow of fist. Often called street-fighter or boxer fractures.



In fractures of metacarpal neck, volar cortex often comminuted, resulting in marked instability after reduction, which often necessitates pinning

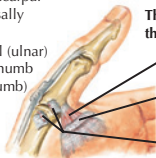
Transverse fractures of metacarpal shaft usually angulated dorsally by pull of interosseous mm.

Stress test for ruptured medial (ulnar) collateral lig. of thumb (gamekeeper thumb)



## Thumb injury other than fracture

Adductor pollicis m. and Aponeurosis (cut)



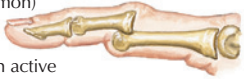Ruptured medial collateral lig. of metacarpophalangeal joint of thumb

Torn medial collateral lig.

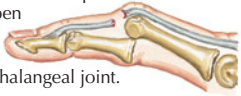## Finger Injuries

**Dorsal dislocation** (most common)

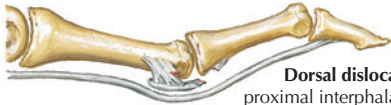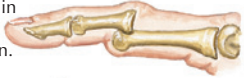Usually reducible by closed means, immobilized with palmar splint for 3 weeks, then active range-of-motion exercises begun

**Palmar dislocation** (uncommon)

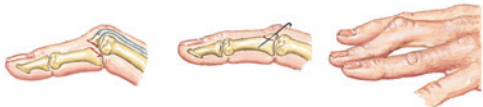Causes boutonnière deformity. Central slip of extensor tendon often torn, requiring open fixation, followed by dorsal splinting to allow passive and active exercises of distal interphalangeal joint.

**Rotational dislocation** (rare)

Note middle and distal phalanges seen in true lateral radiograph, proximal phalanx in oblique view. After reduction, treated as for dorsal dislocation.

**Dorsal dislocation** of proximal interphalangeal

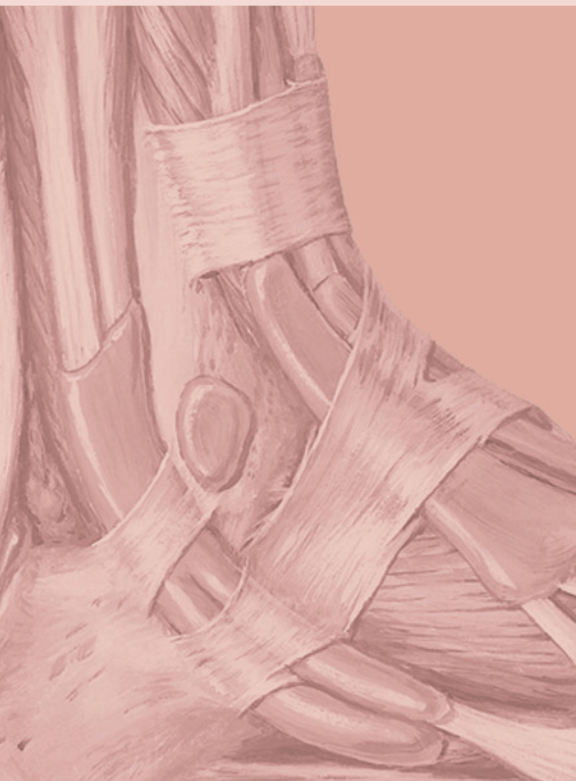
joint with disruption of volar plate and collateral ligament may result in swan-neck deformity and compensatory flexion deformity of distal interphalangeal joint.



**Volar dislocation** of middle phalanx with avulsion of central slip of extensor tendon, with or without bone fragment. Failure to recognize and properly treat this condition results in boutonnière deformity and severely restricted function.

## Proximal Interphalangeal Joint Dislocations

# Lower Limb



This page intentionally left blank



## ANATOMY OF THE HIP AND THIGH

### Femur

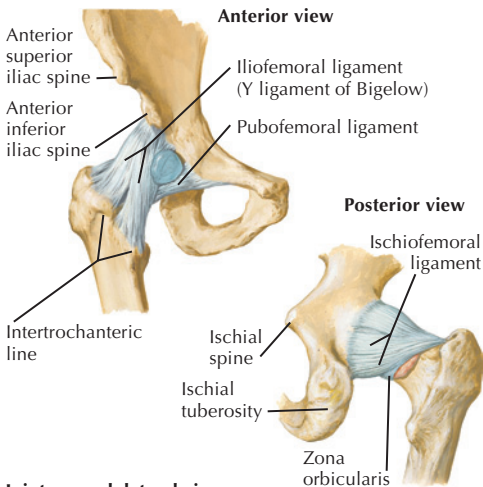
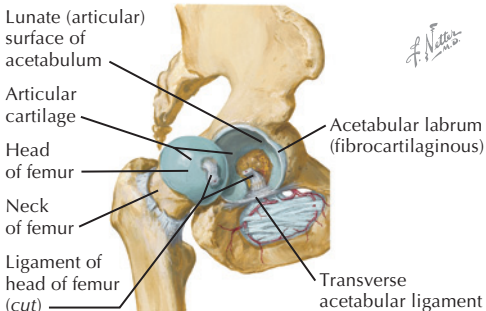
- Parts and landmarks: head; fovea (for round ligament); neck; greater trochanter; lesser trochanter; intertrochanteric line, crest, and fossa; pectineal line; gluteal tuberosity; linea aspera; shaft (body); popliteal surface; adductor tubercle; medial epicondyle; lateral epicondyle; medial condyle; lateral condyle; intercondylar fossa; patellar surface

### Coxal (Hip) Bones

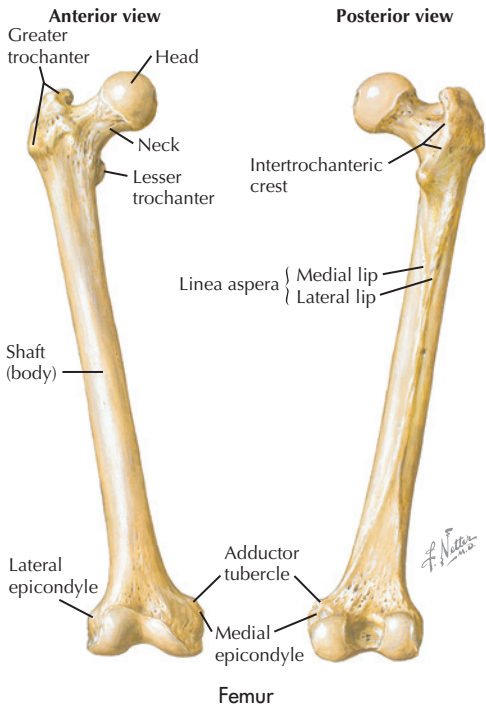
- Ilium, ischium, and pubis are fused in adults. (See [Chapter 19, Pelvic Fractures](#), for more bone information.)
- Coxal bone epiphyseal plates intersect in the center of the acetabulum.
- Acetabulum
  - Peripheral lunate surface lined with hyaline cartilage
  - Fat within central acetabular fossa surfaced with synovial membrane

### Hip Joint

- Synovial ball-and-socket, deepened by circumferential, fibrocartilaginous acetabular labrum

**Joint opened: lateral view**

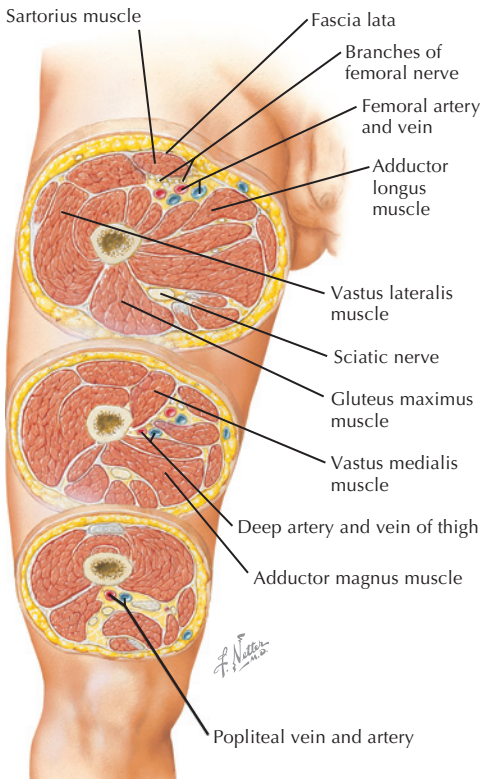
Hip Joint and Ligaments



- Synovial membrane
  - Runs from edges of acetabular hyaline cartilage
  - Along inside of fibrous capsule
  - Extends to distal neck and periphery of articular cartilage of head
- Round ligament (ligamentum teres) of head of femur
  - Intraarticular, covered by synovium
  - Runs from fovea to transverse acetabular ligament
- Transverse acetabular ligament: spans acetabular notch, extending rim for a complete socket
- (Collateral) ligaments: spiraling thickenings of fibrous joint capsule, passing from acetabular rim to intertrochanteric line or trochanters
  - Iliofemoral (Bigelow): anterior-superior, Y-shaped, very strong, prevents hyperextension by screwing femoral head tightly into acetabulum
  - Pubofemoral: anterior-inferior, prevents hyperabduction
  - Ischiofemoral: posterior, weakest of three
- Retinacula
  - Retinacular fibers surround neck proximal to head, binding down nutrient arteries to head.
  - Anatomical basis for head ischemia with neck fracture

### Compartments of the Thigh

- Circumferential deep fascia of lower limbs
  - Like strong elastic stockings
  - Limits expansion of muscles during contraction, important in upright gait



Thigh: Serial Cross Sections

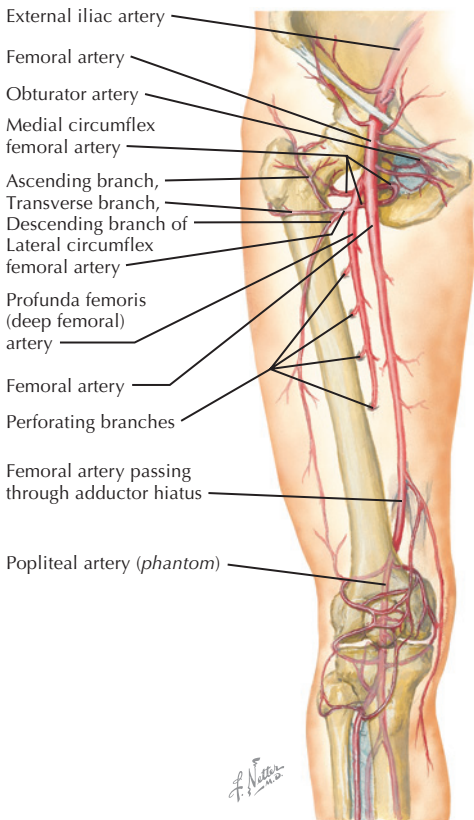
- Fascia lata: investing deep fascia of thigh
  - Attaches proximally to inguinal ligament, pubic rim, Scarpa's fascia, iliac crest, sacrum, coccyx, sacrotuberous ligament, ischial tuberosity
  - Attaches to exposed bone at knee and to crural fascia
  - Strengthened laterally by vertical-running fibers of iliotibial tract, a conjoint aponeurosis of gluteus maximus and tensor fascia lata
- Intermuscular septa separate groups of muscles in thigh.
  - Septa attach to linea aspera and fascia lata.
  - Lateral intermuscular septum strongest
- Gluteal compartment
  - Primarily hip joint abductor and rotator muscles: gluteus maximus, medius, and minimus; piriformis, superior and inferior gemellus, quadratus femoris
  - Vessels: superior and inferior gluteal (internal iliac branches) arteries and veins
  - Nerves: superior and inferior gluteal nerves and branches from sciatic roots, nerve to quadratus femoris
- Anterior compartment
  - Hip flexor and knee extensor muscles: sartorius, rectus femoris; vastus lateralis, medialis, and intermedius (quadriceps femoris)
  - Vessels: femoral and deep femoral arteries and veins
  - Nerves: femoral nerve; posterior divisions of lumbar plexus
- Posterior compartment
  - Hip extensor and knee flexor muscles: semitendinosus, semimembranosus, biceps femoris

- Vessels: perforating branches of deep femoral and popliteal arteries and veins
- Nerves: sciatic nerve, tibial and fibular divisions
- Medial compartment
  - Hip adductor muscles: adductor longus, brevis, minimus, and magnus
  - Vessels: branches of obturator arteries and veins
  - Nerves: obturator nerve, accessory obturator (when present), anterior division of lumbar plexus

## VESSELS AND NERVES

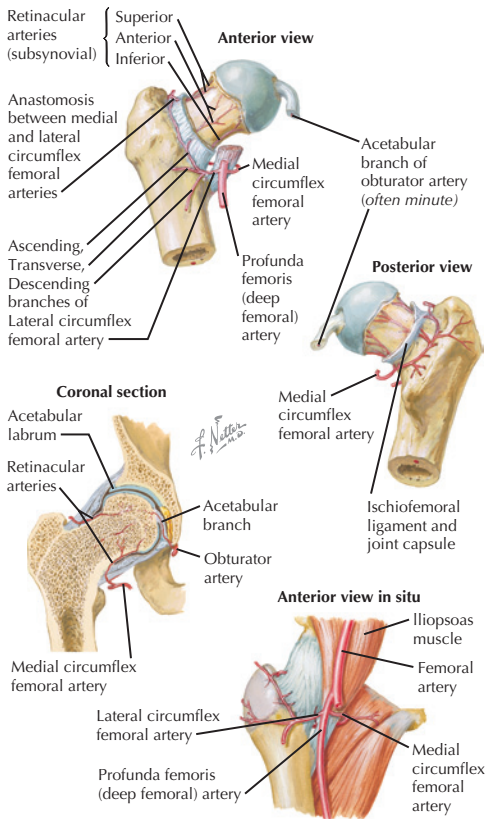
### Arterial Supply to the Thigh and Hip Joint

- Femoral artery (continuation of external iliac supply)
  - Primary source of blood for lower extremity
  - Gives off deep femoral (profunda femoris) proximally to supply deep compartments
  - Travels anteriorly initially under sartorius (in subsartorial canal; Hunter's)
  - Continues as popliteal artery after passing through hiatus of adductor magnus posteriorly into popliteal fossa
- Femoral artery branches
  - Superficial epigastric artery
  - Superficial external pudendal artery
  - Deep external pudendal artery
  - Deep femoral (profunda femoris) artery
    - ▲ Lateral femoral circumflex artery
    - ▲ Medial femoral circumflex artery
    - ▲ Perforating branches
  - Descending genicular artery



Arteries of Thigh



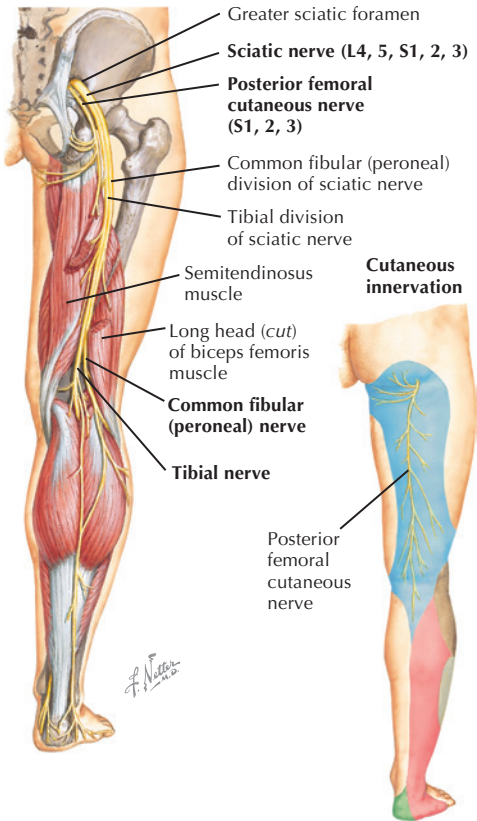


Arteries of Femoral Head

- Popliteal artery (continues as posterior tibial artery of leg)
- Obturator artery (from internal iliac)
  - Artery to head of femur
- *Hip joint* is supplied by anastomotic branches of medial and lateral femoral circumflex and artery to head of femur (from obturator artery).
- Artery to head of femur runs along ligament of head; artery might contribute little blood to joint after adulthood.
- Immediate blood supply to hip joint provided by retinacular arteries, branches of circumflex vessels
- Retinacular arteries from medial circumflex usually provide more blood and pass beneath unattached posterior border of joint capsule.
- Lateral circumflex retinacular arteries must pass through thick iliofemoral ligament and are fewer and smaller than medial branches.
- Circumflex arteries can variably arise directly from femoral artery proper.

### Veins of the Hip and Thigh

- Run parallel to femoral artery and its major branches: valved; arterial counterpulsation effect pumps blood heartward
- Femoral vein tributaries (external iliac drainage)
  - Greater and lesser saphenous: superficial drainage of thigh and leg
  - Lateral circumflex: from hip joint
  - Medial circumflex: from hip joint
  - Deep femoral (profunda femoris)
  - Distal femoral vein proper, drains popliteal vein (leg)



Sciatic Nerve

## Nerves of the Hip and Thigh

- Hilton's law: nerves supplying a joint also innervate muscles acting across it, as well as skin over distal insertions of those muscles
- Sciatic nerve (L4-S1)
  - Dominant nerve supply for lower extremity
  - Runs posterior, medially in deep thigh, separated from femur by adductor magnus
  - To posterior (extensor) compartment of thigh (hamstrings) and compartments in leg and foot
  - Tibial (anterior) and fibular (peroneal; posterior) divisions
- Obturator nerve (L2-L4)
  - To hip adductors
- Femoral nerve (L2-L4)
  - To hip flexors/knee extensors
- Gluteal nerves (L4-S1)
  - To hip extensors, abductors, and rotators

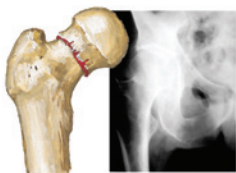## CLINICAL CORRELATES

### Compartment Syndromes

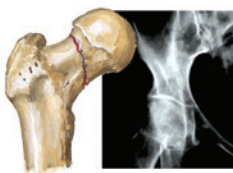- Relatively rare because large volume is required to cause pathological increase in tissue pressure
- Compartment fascia blends with deep fascia of muscles and can allow extravasation of blood.
- Predisposing factors: vascular injury, severe blunt trauma to thigh, systemic hypotension, external compression of thigh, coagulopathy, deep vein thrombosis

### Hip Fractures

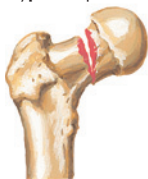- Risk highest in older white women
- Risk factors include osteoporosis, inactivity, smoking, dementia, and psychotropic medications.



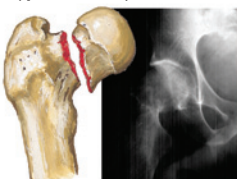**Type I.** Impacted fracture



**Type II.** Nondisplaced fracture

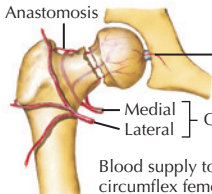


**Type III.** Partially displaced



**Type IV.** Displaced fracture. Vertical fracture line generally suggests poorer prognosis.

Anastomosis



Artery of round ligament of femoral head

Medial  
Lateral } Circumflex femoral aa.

Blood supply to femoral head chiefly from medial circumflex femoral artery. Branches traverse femoral neck and may be torn by fracture, resulting in osteonecrosis of femoral head. Artery of round ligament usually insignificant.

*F. Netter M.D.*

## Intracapsular Femoral Neck Fracture

- Most fractures result from falls onto greater trochanter or from twisting injury of lower extremity.
- 12%-36% 1-year mortality rate in elderly
- Broad classification into 2 types: femoral neck (intracapsular) and intertrochanteric fractures

### Intracapsular Fractures

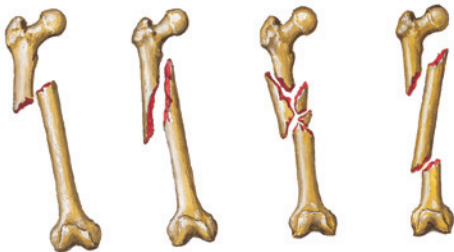
- May be compression-type or tension-type
- Tension-type typically occur on superior neck, more commonly in athletes or military trainees.
- Compression-type fractures typically occur along inferior neck, more commonly in elderly persons with osteoporosis.
- Pathological bone lesions and metastases can also cause fractures.
- High risk of avascular necrosis of femoral head in intracapsular fractures, owing to damage to retinacular arteries running on the neck

### Shaft and Distal Femur Fractures

#### *Diaphyseal Fractures*

- Typically occur with twisting injury in osteoporosis or with metastatic lesions
- Usually treated surgically in adults
- Classified by location
- Subtrochanteric fractures
  - Begin below lesser trochanter but can extend proximally into piriform fossa or intertrochanteric region
  - Region contains cancellous bone with reduced vascularity; risk of delayed healing, failure of fixation

### Shaft fractures



**High transverse or slightly oblique fracture**

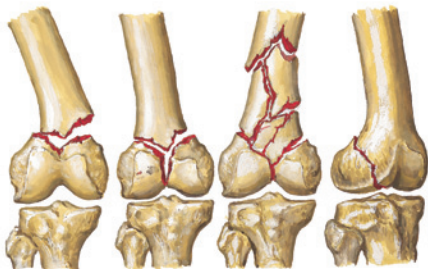
**Spiral fracture**

**Comminuted fracture**

**Segmental fracture**

*F. Netter M.D.*

### Distal fractures



**Transverse supracondylar fracture**

**Intercondylar (T or Y) fracture**

**Comminuted fracture extending into shaft**

**Fracture of single condyle**  
(may occur in frontal or oblique plane)

### Fractures of Shaft and Distal Femur

- Shaft fractures
  - Spiral oblique or transverse
  - Treatment guided by pattern, amount of comminution, associated injuries
  - Falls, vehicle accidents, and gunshot wounds can cause vascular damage, compartment syndromes, knee injuries, and axial fractures.
  - Occasionally accompanied by femoral neck fracture
- Distal fractures
  - Occur within 9 cm of articular surface
  - Gastrocnemius can flex and posteriorly displace distal fragment.
  - Extraarticular or intraarticular
  - Intraarticular may be unicondylar or bicondylar



# 27 Knee and Leg Fractures

## ANATOMY OF KNEE AND LEG

### Patella

- Largest sesamoid bone, attached between quadriceps and patellar tendons
- Patellar tendon attaches to tibial tuberosity.
- Inferior (deep) surface is hyaline cartilage that articulates with femoral condyles as part of complex knee joint.

### Tibia

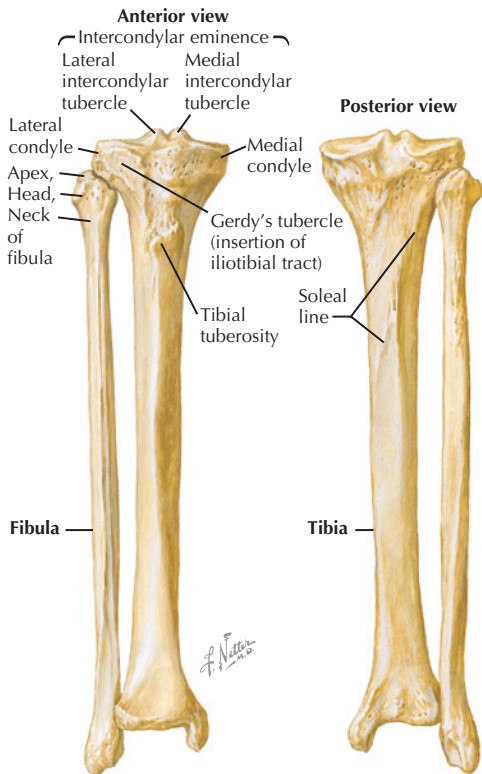
- Parts and landmarks: intercondylar eminence (plateau), lateral and medial intercondylar tubercles, lateral and medial condyles, Gerdy's tubercle (iliotibial tract insertion), tibial tuberosity, anterior border; lateral, medial, and posterior surfaces; interosseus border, soleal line, fibular notch, medial malleolus, inferior articular surface (for talus)

### Fibula

- Parts and landmarks: apex, head, neck, interosseus border, medial crest, posterior border, lateral malleolus, malleolar fossa

### Knee Joint(s)

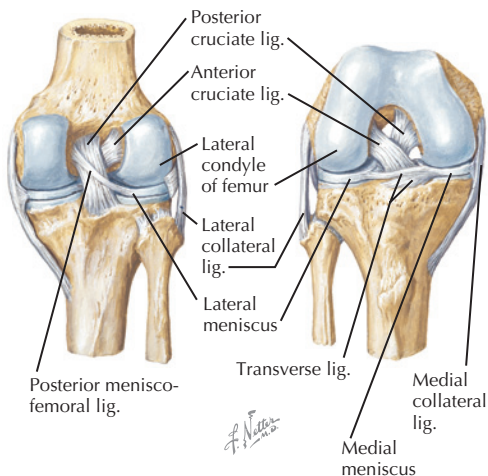
- Fibrous capsule provides relatively little support to complex knee joint.
- Patellofemoral joint: synovial articulation between patella and femoral condyles



Bones of the Leg (Right)

In extension: posterior view

In flexion: anterior view



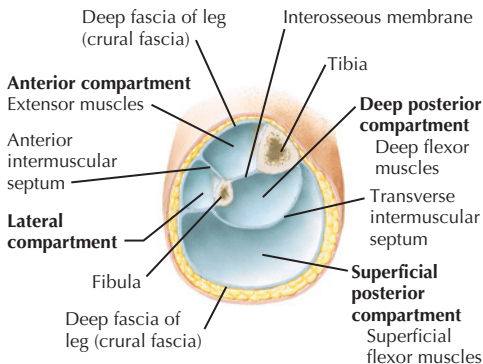
### Knee Joint

- Medial meniscus
  - Articular fibrocartilage between medial femoral and tibial condyles
  - More crescent-shaped, attached to tibial collateral ligament
- Lateral meniscus
  - Articular fibrocartilage between lateral femoral and tibial condyles
  - More circular

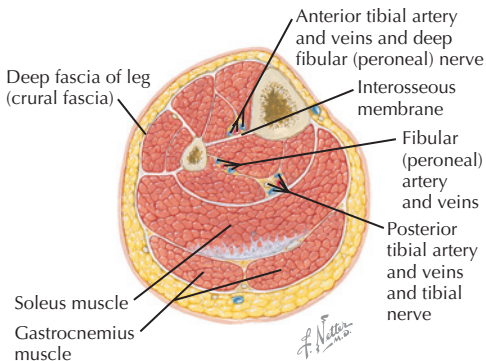
- Transverse meniscal ligament: between anterior aspects of menisci; stabilizing
- Posterior menisiofemoral ligament (of Humphrey): from posterior lateral meniscus to medial femoral condyle; stabilizing
- Anterior cruciate ligament (ACL): from postero-medial aspect of lateral femoral condyle to anteromedial tibial eminence
- Posterior cruciate ligament (PCL): from lateral aspect of medial femoral condyle to posteromedial tibial eminence
- Tibial (medial) collateral ligament
  - Medial femoral epicondyle to medial tibia and medial meniscus
  - Resists valgus angulation
- Coronary ligament: stabilizes medial meniscus
- Pes anserinus
  - Distal tendons of sartorius, gracilis, and semitendinosus inserting on medial subcondylar tibia, superficial to collateral ligaments
  - Resists valgus angulation
- Lateral (fibular) collateral ligament
  - Lateral supracondylar femur to fibular head
  - Resists varus angulation

## Compartments of the Leg

- Crural fascia
  - Tough, nonexpansible, deep fascial sheath surrounds leg compartments, attached to the tibia anteriorly
  - Continuous with fascia lata above knee
  - Fuses with deep intermuscular septa surrounding compartments



### Cross section just above middle of leg



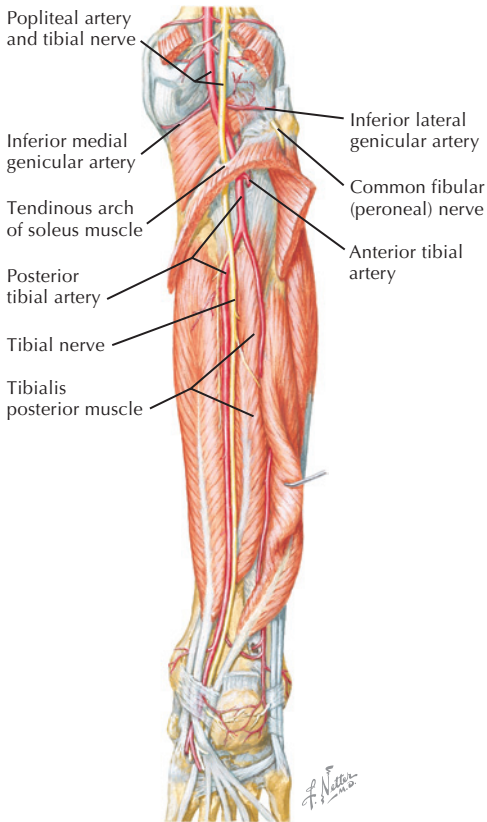
Leg: Cross Section and Compartments

- Anterior compartment
  - Ankle/foot (plantar) extensor muscles: tibialis anterior, extensor digitorum longus, extensor hallucis longus, peroneus (fibularis) tertius (when it exists)
  - Vessels: anterior tibial artery and vein
  - Nerve: deep fibular (peroneal)
- Superficial posterior compartment
  - Knee and ankle/foot (plantar) flexor muscles: gastrocnemius and soleus (triceps surae), plantaris, tibialis posterior, flexor digitorum longus (fibular) branches
  - Vessels: posterior tibial and fibular (peroneal) arteries and veins
  - Nerve: tibial
- Deep posterior compartment
  - Knee and ankle/foot (plantar) flexor muscles: popliteus, tibialis posterior, flexor digitorum longus, flexor hallucis longus
  - Vessels: posterior tibial and fibular (peroneal) arteries and veins
  - Nerve: tibial
- Lateral compartment
  - Evertors of ankle and foot: peroneus (fibularis) longus and brevis
  - Vessels: anterior tibial and fibular (peroneal) arteries and veins (perforating branches)
  - Nerve: superficial fibular (peroneal)

## VESSELS AND NERVES

### Arterial Supply

- Popliteal artery (from femoral) gives rise to medial and lateral genicular branches above and below knee joint (superior and inferior).



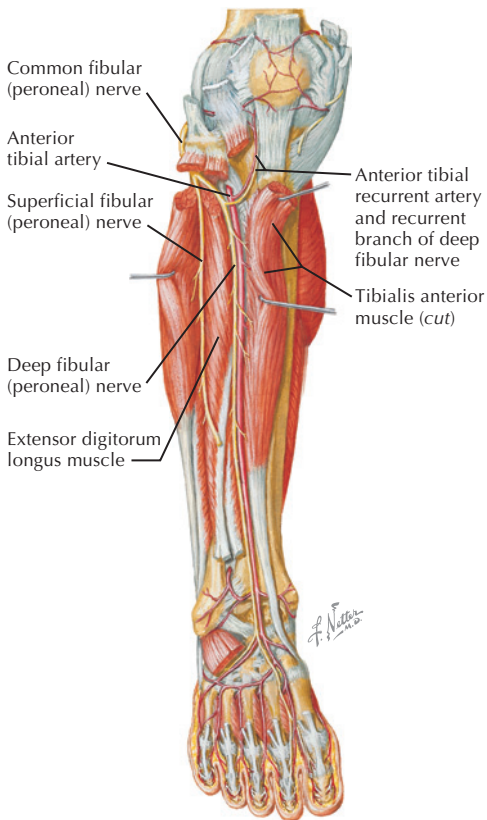
Arteries and Nerves of Leg: Deep Dissection (Posterior View)

- Tibial artery continues from popliteal and branches into the
  - Posterior tibial artery
    - ▲ Fibular (peroneal) artery branch runs laterally along fibula, between flexor hallucis longus and tibialis posterior.
    - ▲ Anterior tibial artery emerges through uppermost interosseus membrane, providing an anterior tibial recurrent branch to genicular anastomosis.
- Anastomoses around knee include
  - Descending genicular artery, medial branch of distal femoral artery
  - Superior lateral genicular and superior medial genicular arteries, branches of popliteal artery
  - Inferior lateral genicular and inferior medial genicular arteries, branches of popliteal artery
  - Posterior and anterior recurrent branches of tibial artery
- Dorsalis pedis artery typically arises from terminal portion of anterior tibial.
- Terminal, perforating branch of the (peroneal) artery typically anastomoses with dorsalis pedis.

### Veins of the Knee and Leg

- Main deep veins run parallel to popliteal and to anterior and posterior tibial arteries and their branches.
- Popliteal vein (tributary of the femoral) includes anterior and posterior tibial branches draining plantar and dorsalis pedis.
- Surface drainage along greater and lesser saphenous veins, into the proximal femoral vein





Arteries and Nerves of Leg: Deep Dissection  
(Anterior View)

## Nerves

- Hilton's law: nerves supplying a joint also innervate muscles acting across it, as well as skin over distal insertions of those muscles

### *Sciatic Nerve (L4-S1)*

- Dominant nerve supply for lower extremity
- Tibial divisions (anterior): posterior compartment of leg (and plantar foot), flexors
- Fibular (peroneal) divisions (posterior)
  - Deep fibular (peroneal) nerve: anterior compartment extensors of ankle and foot
  - Superficial fibular (peroneal nerve): lateral compartment extensor and evertors

## CLINICAL CORRELATES

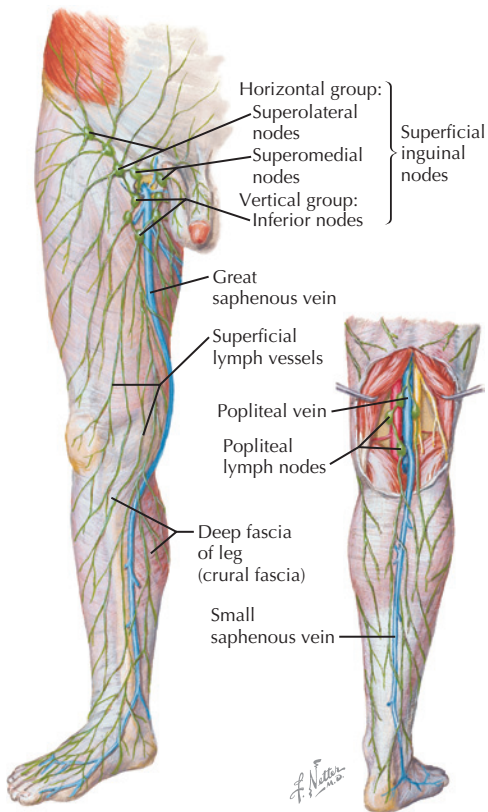
### Compartment Syndrome

- Can occur with open tibial fracture or intramedullary nailing
- Chronic: relatively common without accompanying fracture in runners and other training athletes
- Dependent position of limbs promotes high compartment pressures
- Common findings
  - Isolated pressure increase in deep posterior compartment most common
  - Anterior compartment pressure increase second most common

### Fractures of Knee Region and Leg

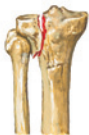#### *Patellar Fractures*

- Typically result from direct blow
- Displaced or nondisplaced

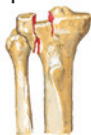

Veins, Lymph Vessels, and Nodes of Lower Limb

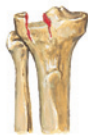## Tibial plateau fracture



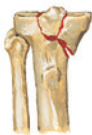**I.** Split fracture of lateral tibial plateau



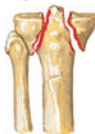**II.** Split fracture of lateral condyle plus depression of tibial plateau



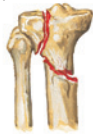**III.** Depression of lateral tibia plateau without split fracture



**IV.** Comminuted split fracture of media tibial plateau and tibial spine



**V.** Bicondylar fracture involving both tibial plateaus with widening



**VI.** Fracture of lateral tibial plateau with separation of metaphyseal-diaphyseal junction

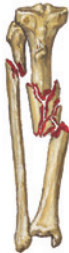## Fracture of shaft of tibia



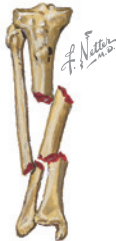**Transverse fracture;** fibula intact



**Spiral fracture** with shortening

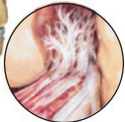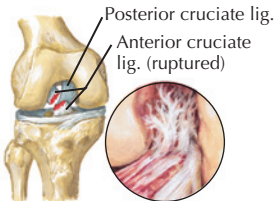


**Comminuted fracture** with marked shortening



**Segmental fracture** with marked shortening

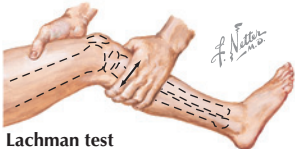## Tibial Fractures



Arthroscopic view



Usual cause is twisting of hyperextended knee, as in landing after basketball jump shot.

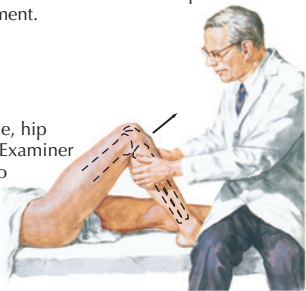


**Lachman test**

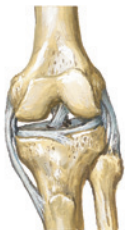With patient's knee bent 20-30°, examiner's hands grasp limb over distal femur and proximal tibia. Tibia alternately pulled forward and pushed backward. Movement of 5 mm or more than that in normal limb indicates rupture of anterior cruciate ligament.

**Anterior drawer test**

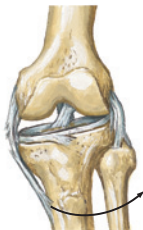Patient supine on table, hip flexed 45°, knee 90°. Examiner sits on patient's foot to stabilize it, places hands on each side of upper calf and firmly pulls tibia forward. Movement of 5 mm or more is positive result. Result also compared with that for normal limb, which is tested first.



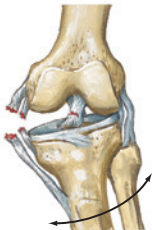
**Rupture of the Anterior Cruciate Ligament**



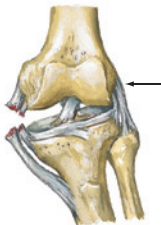
**1st-degree sprain.**  
Localized joint pain and tenderness but no joint laxity



**2nd-degree sprain.**  
Detectable joint laxity plus localized pain and tenderness

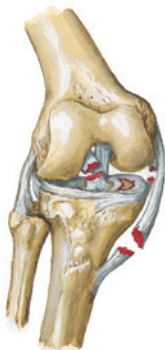

**3rd-degree sprain.** Complete disruption of ligaments and gross joint instability



**Valgus stress** may rupture tibial collateral and capsular ligaments.

*F. Netter M.D.*



**"Unhappy triad" of O'Donoghue.**  
Rupture of tibial collateral and anterior cruciate ligaments plus tear of medial meniscus

### Sprains of Knee Ligaments

- Classifications: comminuted, transverse, vertical, osteochondral, apical, or inferior pole fractures
- Surgical treatment for open, comminuted, or >2 mm displacement or incongruity

### *Tibial Plateau Fractures*

- Common result of falls and vehicle accidents
- Lateral more common, often occur in low-energy trauma of fall in elderly person with osteoporosis
- Medial fractures more commonly associated with *ligament*, peroneal nerve, *meniscal*, and popliteal vessel *injuries*; high-force injury
- Schatzker classification
  - Type I: lateral plateau split
  - Type II: lateral plateau split depression
  - Type III: lateral plateau depression
  - Type IV: medial plateau and tibial spine fracture
  - Type V: bicondylar
  - Type VI: bicondylar with diaphyseal extension

### *Tibial Shaft Fractures*

- Tibia relatively poorly supplied by posterior tibial artery nutrient branches
- Periosteal supply from anterior tibial artery
- Most common long bone fractures, resulting from direct or indirect trauma
- Simple: transverse, spiral, or oblique
- Comminuted
  - May be segmental
  - Result from high-energy torsion, bending, or crush injuries
- Butterfly: result from twisting, bending

- Stress: repetitive overuse (e.g., in dancers, sports, or military training)

### *Fibular Fractures*

- Although non-weight bearing, fibula is often fractured with tibia.
- Interosseus membrane transmits forces from tibia.
- Shaft fracture types comparable to those of tibia
- Pilon fracture
  - Fibular shaft fracture with tibial articular surface compression fracture
  - From vertical loading of ankle joint, fall from height, landing on heel

### *Malleolar Fractures*

- See [Chapter 28, Fractures of the Ankle and Foot](#)



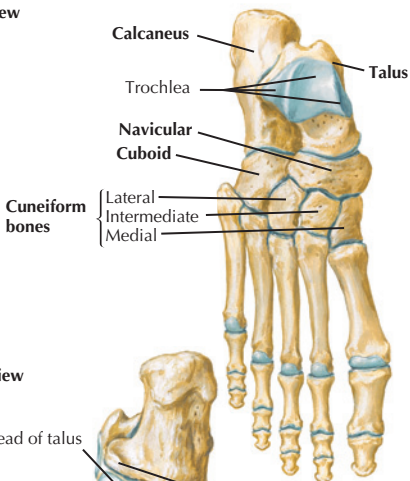
**ANATOMY OF THE ANKLE  
AND FOOT****Malleoli**

- Articulate with trochlea of talus
- Medial malleolus: distal tibia
- Lateral malleolus: distal fibula

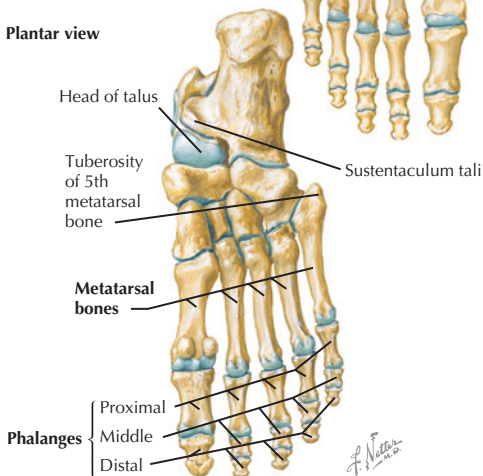
**Tarsal Bones**

- Talus
  - Only bone articulating with tibia and fibula
  - Parts and landmarks
    - ▲ Head, neck, body, trochlea, lateral process, posterior process (medial, lateral tubercles)
    - ▲ Lateral tubercle may be unfused.
  - No muscular attachments
  - Flexor hallucis longus tendon runs between medial and lateral tubercles.
- Calcaneus
  - Has multiple facets, posterior largest
  - Sustentaculum tali
    - ▲ Supports talar neck, attached to spring ligament
    - ▲ Overlies flexor hallucis longus tendon
  - Calcaneal tendon (Achilles) attached to posterior superior tuberosity
- Navicular: boat-shaped, with medial tuberosity for tibialis posterior insertion

## Dorsal view



## Plantar view



Bones of the Foot

- Cuboid
  - ▲ Tuberosity and cuboid groove inferior
  - ▲ Most lateral tarsal bone
  - ▲ Articulates with metatarsals IV and V
  - ▲ Inferior groove for peroneus longus tendon
- Medial cuneiform
  - Largest of 3, for metatarsal I
  - Bears partial insertion of peroneus longus
- Intermediate cuneiform
  - Shortest
  - Metatarsal II base is recessed, fracturable
- Lateral cuneiform: articulates with both navicular and cuboid, as well as metatarsal III

## Metatarsal Bones

- Anterior support of longitudinal arch
- 5, numbered I-V, 1-5
- Base, body, head; characteristics of long bone
- Peroneus brevis inserts on base of metatarsal V

## Phalanges

- Digit 1 (hallux): proximal and distal (2), 2 sesamoid bones
- Digits 2-5: proximal, medial, distal (3)

## Ankle and Foot Joints

- Ankle joint
  - Synovial hinge (ginglymus)
  - Mortise-and-tenon structure with talus between malleoli
- Numerous complex synovial joints exist between individual tarsals and between tarsals and metatarsals.

- Transverse tarsal joint (Chopart)
  - Calcaneus with cuboid + talus with navicular
  - Allows inversion and eversion
- Transverse metatarsal joint (Lisfranc): between cuneiforms, cuboid, and metatarsal bases

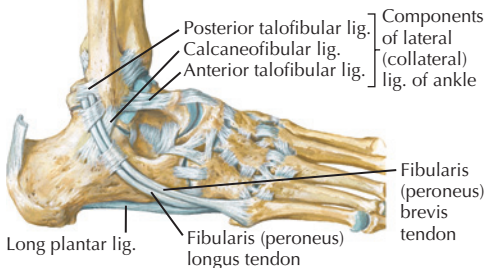
### Ankle and Foot Ligaments

- Inferior tibiofibular (syndesmosis)
  - Complex support of distal tibia and fibula
  - Anterior inferior tibiofibular (AITFL)
  - Posterior inferior tibiofibular (PITFL)
  - Inferior transverse
  - Interosseus ligament
- Ankle ligaments (collateral)
  - Medial: deltoid (4 parts): tibionavicular, tibiocalcaneal, posterior and anterior tibiotalar
  - Lateral: anterior and posterior talofibular (ATFL, PTFL), calcaneofibular (CFL)
- Intertarsal ligaments (named for paired bones)
- Tarsometatarsal ligaments
- Transverse tarsal ligaments
- Interphalangeal and collateral ligaments

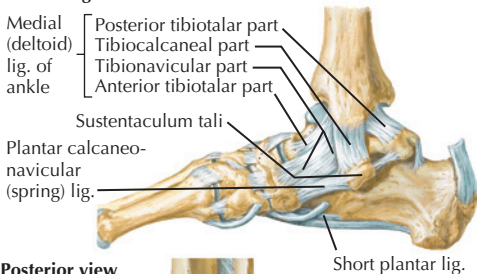
### Compartments of the Foot

- Foot does *not* have muscular compartments comparable to leg and thigh.
- Blood and fluid retention tend to be confined to dorsal or plantar spaces.
- Dorsal: dorsalis pedis vessels lie subcutaneously and dorsal to interossei and bones of foot
- Plantar: spaces occur between layers of foot muscles and tendons
  - Layer 1: abductors of digits 1 and 5
  - Layer 2: flexor digitorum longus tendons and quadratus plantae

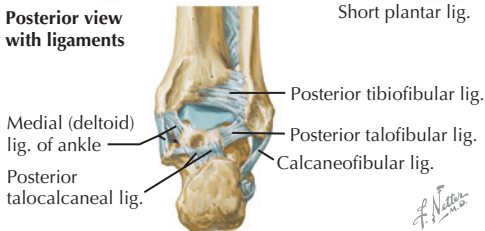
### Right foot: lateral view



### Right foot: medial view



### Posterior view with ligaments



*F. Netter M.D.*

## Ankle Joints and Ligaments

- Layer 3: flexor digitorum brevis
- Layer 4: interossei, adductors of digits 1 and 5, opponens
- Medial and lateral plantar neurovascular bundles lie in space between layers 2 and 3.
- Plantar neurovascular bundles enter foot by passing posterior to medial malleolus: fluid extravasation in posterior inferior leg can follow this route into foot.

## VESSELS AND NERVES

### Plantar view

#### Medial plantar n.

Sensitivity of skin of sole of foot, both sides of 1st, 2nd, 3rd, and medial toes, and medial aspect of the 4th toe, as well as joints of tarsus and metatarsus of the related toes

Proper plantar digital aa.

Common plantar digital aa.

Plantar metatarsal aa.

Plantar arch

Anterior tibial a.

Tibial n.

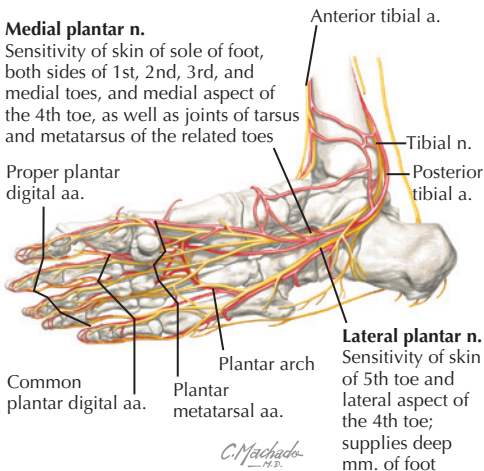
Posterior tibial a.

#### Lateral plantar n.

Sensitivity of skin of 5th toe and lateral aspect of the 4th toe; supplies deep mm. of foot

*C. Machado*  
—M.D.

### Arteries and Nerves of the Sole



## Arterial Supply

- Posterior tibial artery (from tibial) gives rise to medial and lateral plantar branches above and below ankle joint.
  - Medial plantar artery supplies medial aspect of plantar foot.
  - Lateral plantar artery supplies lateral aspect of plantar foot.
- Anterior tibial artery typically gives rise to dorsalis pedis artery.
- Terminal, perforating branch of peroneal (fibular) artery typically anastomoses with dorsalis pedis artery.
- Peroneal (fibular) artery occasionally emerges through uppermost interosseus membrane to give rise to dorsalis pedis artery.

## Venous Drainage

- Runs parallel to anterior and posterior tibial arteries and their major branches
- Deep plantar and dorsal tributaries drain into posterior and anterior tibial veins; tributaries of popliteal drain to femoral.
- Surface drainage along greater and lesser saphenous veins, into femoral and popliteal, resp.

## Nerves

- Hilton's law: nerves supplying a joint also innervate muscles acting across it, as well as skin over distal insertions of those muscles

### *Sciatic Nerve (L4-S1)*

- Dominant nerve supply for lower extremity
- Tibial (anterior) divisions: plantar flexors of foot

- Medial plantar nerve: to abductor and short flexor hallucis, flexor digitorum brevis, 1 medial lumbrical
- Lateral plantar nerve: quadratus plantae, interossei, and 3 lateral lumbricals; adductor hallucis; abductor and flexor digiti minimi brevis
- Peroneal (fibular, posterior) divisions
  - Deep peroneal (fibular): anterior compartment extensors of ankle/foot: extensors hallucis brevis and digitorum brevis
  - Superficial peroneal (fibular): lateral compartment extensor/evertor

## CLINICAL CORRELATES

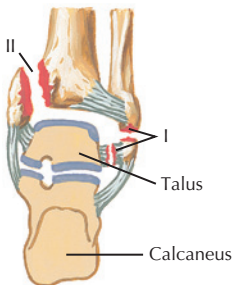
### Ankle Fractures

- Typically involve malleolar prominences of tibia and fibula, along with avulsion and rupture of supporting ligaments
- Characteristic patterns of fractures accompany injuries caused by extreme forced movements in specific directions.
  - Supination and adduction
  - Supination and external rotation
  - Pronation and abduction
  - Pronation and external rotation

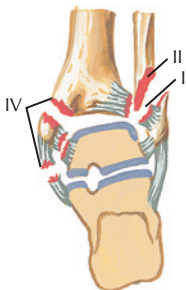
### Tarsal Fractures

- Talus Fractures
  - Neck is most common site for talar fractures.
  - Usually result from direct trauma or landing on foot after a fall
  - Hyperdorsiflexion impacts neck on distal tibia.

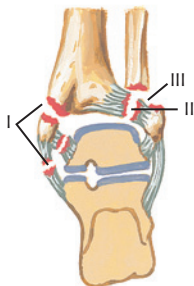




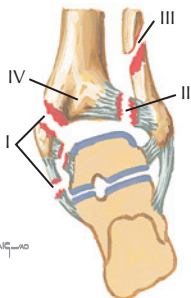
**Supination-abduction (SA)**



**Supination-external rotation (SER)**



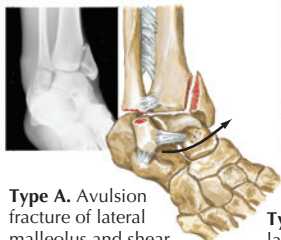
**Pronation-abduction (PA)**



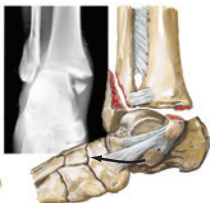**Pronation-external rotation (PER)**

JOHN A. CRAIG MD

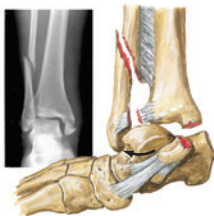### Classification of Ankle Fractures



**Type A.** Avulsion fracture of lateral malleolus and shear fracture of medial malleolus caused by medial rotation of talus. Tibiofibular ligaments intact.



**Type B.** Shear fracture of lateral malleolus and small avulsion fracture of medial malleolus caused by lateral rotation of talus. Tibiofibular ligaments intact or only partially torn.



**Type C.** Disruption of tibiofibular ligaments with diastasis of syndesmosis caused by external rotation of talus. Force transmitted to fibula results in oblique fracture at higher level. In this case, avulsion of medial malleolus has also occurred.

#### **Maisonneuve fracture.**

Complete disruption of tibiofibular syndesmosis with diastasis caused by external rotation of talus and transmission of force to proximal fibula, resulting in high fracture of fibula. Interosseous membrane torn longitudinally.

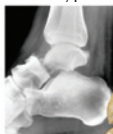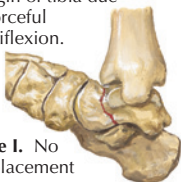


Torn deltoid lig.

### Rotational Fractures

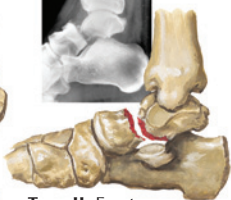Usual cause is impact on anterior margin of tibia due to forceful dorsiflexion.

Lateral radiograph shows type II fracture.

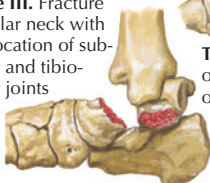


**Type I.** No displacement

**Type III.** Fracture of talar neck with dislocation of subtalar and tibio-talar joints



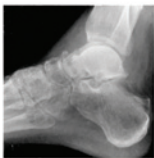**Type II.** Fracture of talar neck with subluxation or dislocation of subtalar joint



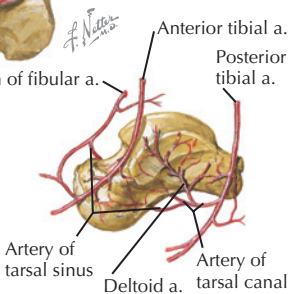
Perforating branch of fibular a.

Anterior tibial a.

Posterior tibial a.



Avascular necrosis of talar body evidenced by increased density (sclerosis) compared with other tarsal bones



Artery of tarsal sinus

Artery of tarsal canal

Deltoid a.

Because of profuse intraosseous anastomoses, avascular necrosis commonly occurs only when surrounding soft tissue is damaged, as in type II and III fractures of talar neck.

## Fractures of the Talar Neck

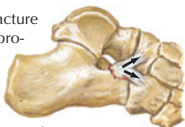
- Three types of talar fractures
  - ▲ Type I: nondisplaced
  - ▲ Type II: neck fracture with subtalar subluxation or dislocation
  - ▲ Type III: neck fracture with dislocation of tibiotalar and subtalar joints
- Neck fractures can lead to avascular necrosis because most of blood supply passes through here.
- Calcaneus Fractures
  - Most common tarsal fractures
  - Intraarticular
    - ▲ 75% of all calcaneal fractures
    - ▲ From forceful landing on a heel
    - ▲ Talus driven down on cancellous calcaneus
  - Extraarticular
    - ▲ Anterior process: avulsion caused by landing on plantar-flexed, adducted foot
    - ▲ Calcaneal tuberosity: avulsion due to sudden forceful contraction of gastrocnemius/soleus
    - ▲ Sustentaculum tali fracture: landing on inverted foot
    - ▲ Body fracture: jumping and landing on heel

### Metatarsal and Phalangeal Fractures

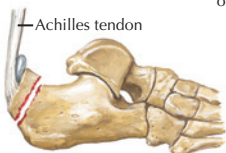
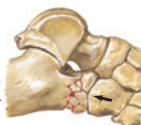- Please see illustration on [page 442](#).

### Extraarticular fracture of calcaneus

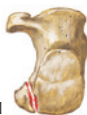Avulsion fracture of anterior process of calcaneus caused by tension on bifurcate ligament



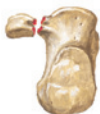Comminuted fracture of anterior process of calcaneus due to compression by cuboid in forceful abduction of forefoot



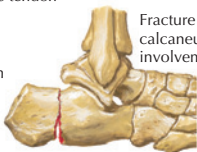
Avulsion fracture of tuberosity of calcaneus due to sudden, violent contraction of Achilles tendon



Fracture of medial process of tuberosity of calcaneus

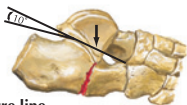


Fracture of sustentaculum tali

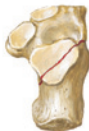

Fracture of body of calcaneus with no involvement of subtalar articulation

### Intraarticular fracture of calcaneus



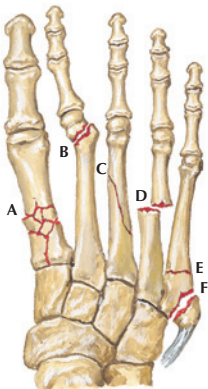
**Primary fracture line**  
Talus driven down into calcaneus, usually by fall and landing on heel



Primary fracture line runs across posterior facet, forming anteromedial and posterolateral fragments.

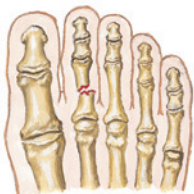*F. Netter M.D.*

### Fractures of the Calcaneus

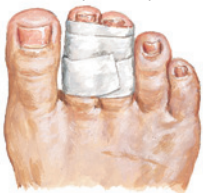

**Types of fractures of metatarsal:**

A. comminuted fracture, B. displaced neck fracture, C. oblique fracture, D. displaced transverse fracture, E. fracture of base of 5th metatarsal, F. avulsion of tuberosity of 5th metatarsal

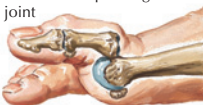

Fracture of proximal phalanx

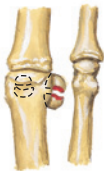

Fracture of phalanx splinted by taping to adjacent toe (buddy taping)

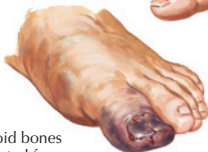Dorsal dislocation of 1st metatarsophalangeal joint



*F. Netter M.D.*



Fracture of sesamoid bones (must be differentiated from congenital bipartite sesamoid bones)



Crush injury of great toe

**Metatarsal and Phalangeal Injuries**

# Index

Page numbers followed by *f* indicate figures.

## A

- Aaron's sign, 147
- Abdomen, acute, 332
- Abdominal ostium, 326*f*
- Abdominal wall
  - anatomy of, 201-207, 202*f*
  - layers of, 201
  - lymphatics of, 208
  - regional arteries and veins of, 207-208
- Abducens (VI) nerve, 9
- Abscesses, of breast, 52-54
- Accessory hepatic ducts, 149, 152*f*
- Accessory (XI) nerve, 10
- Acetabular fossa, 300
- Acetabular fractures, 307-309
  - fixation, 307*f*
- Acetabular labrum, 398*f*, 405*f*
- Acetabular ligament, 398*f*
  - transverse, 400
- Acetabulum, 299, 397, 398*f*
- Achalasia, of esophagus, 124
- Achilles tendon. *see*
  - Calcaneal tendon (Achilles)
- Acid, injury from, esophageal, 128
- ACL. *see* Anterior cruciate ligament (ACL)
- Acousticovestibular (VIII) nerve, 10
- Acromial facet, 345*f*
- Acromioclavicular joint, 343, 344*f*
- Acromioclavicular ligament, 346, 350*f*
- Acromion, 343, 344*f*
- Adamkiewicz, artery of, 36
- Adductor longus muscle, 401*f*, 403
- Adductor magnus muscle, 401*f*, 403
- Adductor pollicis muscle, 387, 388*f*
- Adenocarcinoma, 261
  - of colon, 173
  - esophageal, 126-127
  - of lungs, 111
  - rectal cancer, 294-296
- Adenoid cystic adenoma, bronchial, 113

- Adenomas  
  bronchial, 113  
  of colon, 173
- Adenomyosis, 333*f*-334*f*
- Adipose tissue, 45
- Adnexa, 326*f*  
  anatomy of, 325-328  
  arterial supply of, 328-330  
  venous drainage of, 330
- Adnexal diseases, uterus and, 325-340
- Adult cardiovascular disease, 81-84, 83*f*
- Aggregate lymphoid nodules, 267*f*
- AiIS. *see* Anterior inferior iliac spine (AiIS)
- Ala, sacral, 299
- Alar ligaments, 33
- Alkali, injury from, esophageal, 128
- Alveolar ducts, 95
- Alveolar sacs, 95
- Amebic colitis, 175-178
- Ampulla of ductus deferens, 312*f*
- Ampulla of Vater, 150*f*, 154, 185, 254, 326*f*  
  endoscopy through, 160  
  obstruction of, 159*f*, 162
- Ampullary stone, 159*f*
- Anal canal, 286
- Anal columns (Morgagni's), 286*f*
- Anal fissure, 294
- Anal glands, 286, 286*f*
- Anastomotic loops  
  arterial, 267*f*, 271*f*  
  veins, 272*f*
- Aneurysm, left ventricle, 82
- Angina, 84
- Angular artery, 6*f*
- Angular incisure (notch), of stomach, 181, 182*f*
- Ankle  
  anatomy of, 429-434  
  arterial supply of, 435  
  fractures of, 429-440, 437*f*  
  joints of, 431-432  
  ligaments of, 432, 433*f*  
  nerves of, 435-436  
  venous drainage of, 435
- ANLD. *see* Axillary lymph node dissection (ANLD)
- Annular ligament, 368, 376*f*
- Anoderm, 286*f*
- Anorectal anatomy, 285-289, 286*f*  
  arteries in, 290*f*  
  lymphatics in, 289-292, 293*f*  
  microscopic, 287  
  nerves in, 288*f*  
  veins in, 291*f*  
  vessels and, 289-292
- Anorectal arteries, 290*f*
- Anorectal diseases, 285-296  
  abscess, 292-294  
  hemorrhoids, 168, 292



- Antebrachial
  - compartment syndrome, 374
- Antebrachial fascia, 369, 370*f*
- Antebrachial spaces, 387
- Anterior cardiac veins, 75*f*, 76
- Anterior cerebral arteries, 7
- Anterior compartment
  - of leg, 417*f*, 418
  - of thigh, 402
- Anterior cruciate ligament (ACL), 415*f*, 416
  - rupture of, 425*f*
- Anterior drawer test, 425*f*
- Anterior external plexus, 36
- Anterior inferior iliac spine (AIIS), 297, 298*f*, 306*f*
- Anterior longitudinal ligament, 298*f*
- Anterior papillary muscle, 66*f*-67*f*
- Anterior posterior
  - compression fracture, 308*f*
- Anterior process, fracture of, 440
- Anterior superior iliac spine (ASIS), 297, 306*f*
- Anterior tibial artery, 419*f*, 420, 435
- Anterior vagal trunk,
  - small intestine and, 269*f*
- Antrum, 181, 183
  - pyloric, 182*f*
- Anulus fibrosus, 30*f*, 31
- Aorta, 61-62, 63*f*-64*f*
  - coarctation of, 81
  - overriding, 80
- Aortic arch, 115, 116*f*, 133
  - development of, 72
- Aortic insufficiency, 84-86
- Aortic (lumbar) lymph nodes, lateral
  - kidneys and, 225*f*, 226
  - large intestine and, 171
  - uterus and ovaries and, 331*f*
- Aortic plexus, 269*f*
- Aortic stenosis, 84, 85*f*
- Aortic valve, 62, 67*f*
- Aorticorenal ganglia, 221*f*, 222
- Apex, of heart, 63*f*
- Appendectomy, surgical, 147
- Appendiceal abscess, 146*f*
  - vs. ovarian cyst, 336*f*
- Appendiceal artery, 140*f*, 142-143
- Appendiceal
  - (appendicular) vein, 143, 143*f*
- Appendicitis, 139, 145, 146*f*, 147
- Appendicular artery, 140*f*, 142-143
- Appendicular nodes, 144*f*
- Appendicular
  - (appendiceal) vein, 143, 143*f*

- Appendix  
abscess of, 146*f*, 336*f*  
anatomy of, 139-142,  
140*f*-141*f*  
carcinoid of, 146*f*,  
147  
diseases of, 139-147,  
146*f*  
inflamed, fecal  
concretions in,  
146*f*  
location and position of,  
139-142  
mucocele of, 146*f*  
retrocecal, with  
adhesions, 146*f*  
vessels and lymphatics  
of, 142-144,  
143*f*-144*f*
- Arcades, intestinal  
arterial, 267*f*
- Arcuate line, 299
- Arm, 356, 357*f*-358*f*, 360*f*  
nerves of, 359-362  
veins of, 359
- Arteriae rectae, 167*f*, 271*f*
- Arterial abnormalities,  
78-79
- Arterial supply  
of leg, 418-420, 419*f*  
of thyroid, 19
- Articular process, 30*f*
- Ascites, 246-247, 251
- ASDs. *see* Atrial septal  
defects (ASDs)
- ASIS. *see* Anterior  
superior iliac spine  
(ASIS)
- Atlas (C1), 28*f*, 29
- Atonic stomach, 182*f*
- Atrial septal defects  
(ASDs), 78
- Atrioventricular bundle  
(of His), 65
- Atrioventricular node, 62
- Atrium  
internal features of  
left, 67*f*  
right, 66*f*  
left, 61-62, 64*f*  
right, 61-65, 63*f*-64*f*
- Auditory nerve. *see*  
Acousticovestibular  
(VIII) nerve
- Auerbach's plexus, 164,  
166, 183, 186, 268,  
287
- Auricular artery, posterior,  
5, 6*f*
- Auriculotemporal nerve,  
8*f*
- Avulsion fracture, 438*f*
- Avulsions, 306*f*
- Axillary artery, 347*f*, 348,  
358*f*, 359, 360*f*
- Axillary lymph node  
dissection (ANLD), 60
- Axillary nerve, 356,  
360*f*-361*f*  
injury to, 365
- Axillary nodes, 49, 208
- Axillary vein, 348, 359,  
373
- Axis (C2), 28*f*, 29
- Azygos system, 133
- Azygos vein, 119, 121*f*

## B

- Backpain, cardiovascular disease in women and, *83f*
- Barrett's esophagus, *127*
- Base, of skull, *3*
- Basilic vein, *348, 359, 372-373, 389*
- Beck's triad, *87*
- Benign disease, of breast, *50-54*
- Benign prostatic hyperplasia (BPH), *311, 319-320*
- Benign surface papilloma, *339f*
- Benign tumors, of lung, *114*
- Biceps brachii muscle, *356, 357f, 363f, 378f*
- Biceps brachii tendon, *353, 355f*
- Biceps tendon, *345*
- Bigelow ligament. *see* Iliofemoral (Bigelow) ligament
- Bile  
production of, *156-158*  
secretion of, *154, 158*
- Bile duct, common, *150f, 153-154, 155f, 239f*  
calculus in, *159f*  
interlobular, *238*  
portal triad and, *233, 234f*  
variations in, *152f*
- Bile duct sphincter, *153*
- Bile stones, *158*
- Biliary colic, *159f*
- Biliary diseases, *149-162*
- Biliary duct, intrahepatic, *149*
- Biliary function tests, *160*
- Biliary pain, mechanisms of, *159f*
- Biliary system  
extrahepatic  
anatomy of, *149-154, 150f*  
diagnostic procedures for, *160*  
vessels and lymphatics of, *154-156, 155f, 157f*  
hemorrhage in, *252*
- Biliary tract, carcinoma of, *162*
- Billroth procedures, *199*
- Black stones, *160*
- Bladder, *312f*  
neck, *321f*  
perforation, *321f*
- Bleeding, gastrointestinal, upper, *193*
- Blood circulation,  
intrapulmonary, *100f*
- Bloodless fold of Treves, *140f, 142*
- Blowout fracture, of orbit, *13*
- Body fracture, of  
calcaneus, *440*
- Body of pancreas, *254f*
- Boerhaave's syndrome, *127*
- Boutonnière deformity, *394f*

- Boxer fractures, 393*f*  
 BPH. *see* Benign prostatic hyperplasia (BPH)  
 Brachial artery, 357*f*-358*f*, 359, 369-372  
 Brachial fascia, 356  
 Brachial plexus, 348-349, 356, 360-362, 360*f*-361*f*  
   trunks, 361*f*  
 Brachial vein, 348, 357*f*, 359, 373  
 Brachiocephalic vein, 121*f*, 133  
 BRCA1 gene, 55  
 BRCA2 gene, 55  
 Breast  
   anatomy of, 45-47  
   arterial supply of, 47-49  
   basic structure of, 45  
   benign disease of, 50-54  
   development and embryology of, 47  
   endocrinology of, 45-47  
   lymphatic drainage of, 48*f*, 49-50  
   premalignant lesions of, 54  
   sensory innervation of, 47  
   venous drainage of, 49  
 Breast cancer, 55-60  
   clinical signs of, 55-56, 58*f*  
   staging of, 59  
   treatment of, 59-60  
 Breast diseases, 45-60  
 Broad ligaments, 326*f*  
 Bronchi, 94-96  
 Bronchial arteries, 98, 101*f*, 120*f*  
 Bronchial veins, 98, 101*f*  
 Bronchiolar mucosa, 95  
 Bronchiolar smooth muscle, submucosal, 95  
 Bronchioles, 95  
 Bronchogenic carcinoma, 109-111, 112*f*  
 Bronchopulmonary segments, of lungs, 94-96  
 Buccal nerve, 8*f*  
 Bulbourethral (Cowper's) gland, 312*f*, 313  
 Bulbus cordi, 69
- C**
- C1(atlas), 28*f*, 29  
 C1 burst (Jefferson), 38, 39*f*  
 C2 (axis), 28*f*, 29  
 C2 hangman's, in cervical fractures, 38, 39*f*  
 C2 odontoid, in cervical fractures, 38  
 CABG. *see* Coronary artery bypass graft (CABG)  
 Calcaneal tendon (Achilles), 429  
 Calcaneal tuberosity, fracture of, 440  
 Calcaneus, 429, 430*f*  
   fractures of, 440, 441*f*

- Calcium oxalate, 226
- Calyces
  - major, 220
  - minor, 220
- Camper's fascia, 201
- Cancer, 338-340
  - prostate, 317
- Capitate bone, 381, 382*f*, 385*f*
- Capitulum, 356
- Capsular ligament, 355*f*
- Carcinoma, 322*f*
  - risk factors of, 55
- Cardiac conduction system, 62
- Cardiac drainage vessels, 76-77
- Cardiac embryology, 68-72
- Cardiac lymph vessels, and nodes, 76-77
- Cardiac nerve plexus, 72-73
- Cardiac tamponade, 87, 90*f*
- Cardiac veins, 62
- Cardinal ligaments, 328
- Cardiovascular disease
  - in elderly, 83*f*
  - in women, 83*f*
- Carpal bones, 381, 382*f*
  - fractures of, 390-392
    - scaphoid, 391*f*, 392
- Carpal fractures, 374
- Carpal joints, 383
- Carpal tunnel, 373, 384-387, 385*f*
- Carpal tunnel syndrome, 392
- Carpometacarpal joints, 383-384
- Catecholamines, 65
- Cauda equina, 35*f*
- Cavernous hemangioma, of liver, 246-247
- CCK. *see* Cholecystokinin (CCK)
- Cecal artery, 142
- Cecal vein, posterior, 143*f*
- Cecum, 163, 164*f*
  - appendix and, 139, 142
  - Crohn's disease of, 280*f*
  - low-lying, *vs.* ovarian cyst, 336*f*
  - small intestine and, 266*f*
- Celiac artery, 119
  - branches of, 241, 270
  - variations of, 242*f*
- Celiac axis, 187, 191
- Celiac branches, small intestine and, 269*f*
- Celiac ganglion, 151, 188*f*, 221*f*, 241, 256
- Celiac nodes, 122, 123*f*, 157*f*, 194*f*, 245*f*, 260*f*, 274*f*
- Celiac plexus, 151, 188*f*, 221*f*, 222, 238, 240, 256
- Celiac trunk, 155*f*, 189*f*-190*f*, 191, 254*f*
- Central veins, of hepatic lobules, 238, 243
- Cephalic vein, 348, 359, 372, 389
- Cerebral arteries, anterior, 7

- Cervical curvature, 27, 28*f*
- Cervical fibroid, 335*f*
- Cervical fractures, 38, 39*f*
- Cervical nerve, 10
- Cervical plexus, 8*f*
- Cervical spinal nerves, dorsal rami of, 8*f*
- Cervical vertebrae, 28*f*, 29
- Cervicothoracic (stellate) ganglion, 118*f*
- Cervix  
cancer of, 333*f*-334*f*  
uterine, 325-326, 330  
carcinoma of, 338
- Chance fracture, 37*f*
- Chancre, 333*f*-334*f*
- Chemical injury, esophageal, degrees of, 128
- Chemotherapeutic adjuncts, 60
- Children's ribs, 135
- Cholangiole, 240*f*
- Cholecystectomy, 153, 161-162
- Cholecystitis, 159*f*, 161
- Cholecystokinin (CCK), 154, 158, 268
- Cholelithiasis, 158-160, 159*f*
- Chondral fracture, 134*f*
- Chondroma, of lung, 114
- Chondrosternal separation, 134*f*
- Chordae tendineae, 66*f*-67*f*
- Chorio-epithelioma, 333*f*-334*f*
- Circular folds, small intestine and, 267*f*
- Circumferential deep fascia, of lower limbs, 400-403
- Circumflex arteries, 406
- Cirrhosis, 247-251, 250*f*  
carcinoma with, 247, 249*f*
- Cisterna chyli, 171, 194*f*, 225*f*, 226, 259, 274*f*
- Clavicle, 343, 345*f*  
fractures of, 350*f*, 351  
manubrium and, 130, 130*f*
- Clear cell carcinoma of ovary, 339*f*
- Clinical correlates  
in breast diseases, 50-60  
of heart diseases, 77-87  
in skull and face fractures, 10-15  
in thyroid diseases, 21-23  
in vertebral fractures, 36-38
- CNB. *see* Core needle biopsy (CNB)
- Coarctation, of aorta, 81
- Coccyx, 28*f*, 299  
fracture of, 306*f*
- Colectomy, aspects of, 178
- Colic arteries, 166, 167*f*
- Colic branch, small intestine and, 271*f*
- Colic nodes, 144*f*

- Colic veins, 168, 169*f*
- Colitis, of colon, 175-178  
ulcerative, 177*f*, 178
- Collateral artery, 358*f*
- Collateral ligaments, 400
- Colles' fracture, 379, 380*f*
- Colloid carcinoma, of stomach, 198*f*
- Colon, 163  
anatomy of, 163-166, 164*f*  
arterial supply of, 166-168, 167*f*  
ascending, 266*f*  
cancer of, 173, 174*f*  
surgical resection of, 179*f*  
colitis of, 175-178  
diverticula of, 171  
diverticulitis of, 171-173  
diverticulosis of, 171, 172*f*  
embryology of, 165  
innervation of, 165-166  
parasympathetic, 165-166  
sensory fibers, 166  
sympathetic, 166  
ischemia of, 294  
lymphatic drainage of, 168-171, 170*f*  
polyps of, 173  
transverse, 266*f*  
venous drainage of, 168, 169*f*
- Colorectal cancer, 173, 174*f*  
clinical manifestations of, 295*f*  
metastases from, 247  
obstruction in, 173, 174*f*, 178  
rectal involvement in, 294
- Comminuted, skull fracture, 10
- Common bile duct, 262*f*
- Common facial vein, 6*f*, 7-9
- Common fibular (peroneal) nerve, 407*f*
- Common hepatic artery, 150*f*, 155, 155*f*, 189*f*-190*f*, 241, 242*f*, 243, 257*f*  
gastroduodenal branches of, 191  
small intestine and, 270
- Common hepatic duct, 149, 150*f*, 151  
arteries of, 155*f*  
variations in, 152*f*
- Common iliac nodes, 293*f*, 331*f*
- Compact (cortical) bone, 3
- Compartment syndrome, 408  
antebrachial, 374  
forearm-hand, 369  
in leg, 422  
upper limb, 362

- Compartment syndrome  
(*continued*)  
of wrist and hand,  
390-392
- Compound, skull  
fractures, 11*f*, 13
- Compound depressed  
skull fractures, 11*f*
- Condylar fracture, 366
- Congenital aortic stenosis,  
81
- Congenital heart disease,  
77-78
- Conjoined (conjoint)  
tendon, 204
- Connective tissue (true)  
capsule, 17
- Conoid ligament, 344*f*,  
346
- Conoid tubercle, 345*f*
- Conotruncal ridges, 71
- Conus arteriosus, 63*f*, 66*f*
- Conus medullaris, 34, 35*f*
- Cooper (pectineal)  
ligament, 201, 211
- Cooper's (suspensory)  
ligaments, 45, 46*f*
- Coracoacromial ligament,  
344*f*, 346
- Coracoclavicular ligament,  
344*f*, 345-346, 350*f*
- Coracoid process, 343,  
344*f*, 361*f*
- Cords, of brachial plexus,  
361*f*, 362
- Core needle biopsy  
(CNB), 50
- Corona mortis, 210*f*
- Coronary arteries, 61, 75*f*
- Coronary artery bypass  
graft (CABG), 82
- Coronary artery disease,  
81-82, 83*f*
- Coronary ligament, 416  
of liver, 233, 235*f*
- Coronary sinus, 64*f*,  
66*f*-67*f*, 73-76, 75*f*
- Coronoid process, 367,  
368*f*  
fractures of, 374-379,  
375*f*
- Cortex, of kidney, 220
- Cortical bone, of ribs, 129
- Costal cartilages, 129, 130*f*
- Costochondral joints, 130
- Costochondral separation,  
134*f*
- Costoclavicular ligament,  
343, 345*f*, 346
- Costotransverse joints,  
130
- Costovertebral dislocation,  
134*f*
- Costovertebral joints, 129
- Cough, chronic, causes of,  
104*f*
- Cowper's (bulbourethral)  
glands, 312*f*, 313
- Coxal (hip) bones,  
297-299, 397
- Cranial nerve, 9-10
- Cranial vault, 3
- Cranium. *see also* Skull  
arteries of, 5-7, 6*f*
- Cremaster muscle, 202*f*,  
203, 209*f*



- Cremasteric artery, 207, 209*f*
- Cremasteric fascia, 202*f*, 203
- Cricopharyngeus, 115, 122
- Crista terminalis, 66*f*
- Crohn's disease, 175, 176*f*, 279-281, 280*f*
- Cruciate ligament (craniovertebral), 32-33
- Crural fascia, 416-418, 417*f*
- Cubital tunnel, 373-374
- Cuboid, 430*f*, 431
- Cuneiform bones, 430*f*
- Cupola, 91
- Cutaneous infections, endocarditis and, 88*f*
- Cutaneous nerves, of head and neck, 8*f*
- Cysteine stones, 226
- Cystic artery, 150*f*, 154, 155*f*, 242*f*
- Cystic duct, 149, 150*f*, 151, 155*f*  
ligation of, 162  
obstruction of, 159*f*, 161  
variations in, 152*f*, 153
- Cystic lymph nodes, 156, 157*f*
- Cystic node, 245*f*
- Cystic veins, 156
- Cystohepatic junction, 153
- Cystohepatic triangle (of Calot), 155*f*
- Cystosarcoma phyllodes, 54
- Cysts, 333*f*-334*f*  
in breast, 52
- ## D
- Dashpot function, 32
- DCIS. *see* Ductal carcinoma in situ (DCIS)
- Deep external pudendal artery, 403
- Deep femoral (profunda femoris) artery, 403, 404*f*-405*f*
- Deep fibular (peroneal) nerve, 422
- Deep posterior compartment, of leg, 417*f*, 418
- Deferential artery, 207
- Defibrillators, 87
- Deltoid muscle, 356, 357*f*
- Deltoid tuberosity, 354*f*
- Dental infections, endocarditis and, 88*f*
- Dentate line, 285, 286*f*
- Descending genicular artery, 403, 420
- Developmental (homeobox) anomalies, 27
- Diabetes, cardiovascular disease in women and, 83*f*

- Diaphragm, 91, 182*f*  
 hiatal hernia of, 126,  
 196, 197*f*, 216*f*  
 lymph nodes on,  
 243-246
- Diaphyseal fractures,  
 410-412
- Diploë, 3
- Diploic spaces, 3
- Distal fractures, 411*f*, 412
- Distended bladder, *vs.*  
 ovarian cyst, 336*f*
- Diverticula, colonic, 171
- Diverticulum  
 traction, 124  
 Zenker's, 122-124
- Dorsal root (spinal)  
 ganglion, 131*f*
- Dorsalis pedis artery, 420,  
 435
- Ductal carcinoma in situ  
 (DCIS), 54
- Ductal ectasia, 52
- Ducts of Luschka, 153
- Ductus arteriosus, patent,  
 79-80
- Ductus (vas) deferens,  
 202*f*, 207-208, 209*f*
- Duodenal veins, venous  
 drainage of, 273
- Duodenojejunal flexure,  
 184*f*
- Duodenum, 184-185,  
 184*f*, 262*f*  
 adenocarcinoma of, 278  
 arteries of, 190*f*, 191  
 (common) bile duct  
 and, 184*f*
- Duodenum (*continued*)  
 carcinoma of head  
 invading, 262*f*  
 gallbladder and, 149,  
 150*f*  
 greater papilla of, 185  
 hepatopancreatic  
 ampulla and, 254  
 innervation of, 187-189,  
 188*f*  
 lesser papilla of, 185  
 microscopic anatomy  
 of, 185-186  
 ulcer of, 193-196  
 venous drainage of,  
 191-193, 192*f*
- E**
- Early development, of  
 cardiac embryology,  
 68-69
- Ecchymosis, 15, 16*f*
- Ectopic pregnancy,  
 333*f*-334*f*
- Ejaculatory ducts, 311  
 beginning of, 312*f*  
 opening of, 312*f*
- Elbow joint, 353-356,  
 367-369  
 dislocations of, 374-379,  
 375*f*
- Embolism, pulmonary,  
 106-109, 110*f*  
 infarction secondary to,  
 108  
 in pulmonary artery,  
 108

- Embolism, pulmonary  
 (*continued*)  
 roentgenographic  
 appearance of, 109  
 source of, 106-109  
 without infarction,  
 108
- Embryonic mammary  
 ridges, 47
- Emissary veins, 3  
 parietal, 6*f*
- Endoabdominal fascia,  
 201, 205
- Endobronchial lipomas,  
 114
- Endocardial cushions, 70*f*,  
 71
- Endocarditis, 86-87, 88*f*
- Endocervical polyps,  
 333*f*-334*f*
- Endocervix, cancer of,  
 333*f*-334*f*
- Endocrine neoplasms,  
 261-263
- Endocrinology, of breast,  
 45-47
- Endometrial polyps,  
 333*f*-334*f*
- Endometriosis, 333*f*-334*f*
- Endopelvic fascia, 287
- Endoscopic retrograde  
 cholangiopancreatog-  
 raphy (ERCP), 160,  
 252, 259
- Epicardium, 65
- Epidermoid carcinoma, of  
 lungs, 109, 112*f*
- Epidural hematoma, 13
- Epidural plexus, 36
- Epigastric artery, 204,  
 208, 209*f*  
 inferior, 210*f*
- Epigastric veins, 208,  
 209*f*, 303
- Epigastric vessels, 207
- Epiploic (omental)  
 appendices, 163, 172*f*
- Epiploic (omental)  
 foramen (of Winslow),  
 233, 234*f*
- ERCP. *see* Endoscopic  
 retrograde cholangio-  
 pancreatography  
 (ERCP)
- Erosion, in uterus,  
 333*f*-334*f*
- Esophageal diseases,  
 115-128
- Esophageal nerve plexus,  
 117-119
- Esophageal varices, 250*f*
- Esophagitis, peptic, 125*f*
- Esophagus  
 achalasia of, 124  
 anatomy of, 115-119,  
 116*f*  
 arterial supply of, 119,  
 120*f*  
 cancer of, 126-127  
 caustic injury to,  
 127-128  
 diverticulum of,  
 122-124  
 gastroesophageal reflux  
 disease and,  
 124-126, 125*f*  
 hiatal hernia and, 126,  
 196, 197*f*, 216*f*

- Esophagus (*continued*)  
 innervation of, 117-119,  
 118*f*  
 lymphatic drainage of,  
 122, 123*f*  
 perforations of, 127  
 polyps of, 127  
 stomach and, 181, 182*f*  
 stricture of, 125*f*  
 surgical approaches to,  
 122  
 venous drainage of,  
 119-122, 121*f*, 244*f*  
 vessels and lymphatics  
 of, 119-122
- Essex-Lopresti fracture,  
 377*f*
- Estrogen, 45-47
- Ethmoid bone, 3
- Ethmoidal nerve, external  
 nasal branch of  
 anterior, 8*f*
- Excisional biopsy, 50
- Exophthalmos,  
 moderately severe,  
 22*f*
- External anal sphincter  
 muscles, 286
- External carotid artery, 5,  
 6*f*, 20*f*
- External iliac artery, 404*f*
- External iliac drainage,  
 406
- External iliac node, 293*f*,  
 318*f*, 331*f*  
 prevesical plexus and  
 pathway to, 318*f*
- External jugular vein, 9
- External oblique fascia,  
 207
- External oblique muscle,  
 201-204, 202*f*,  
 206
- External plexus  
 anterior, 36  
 posterior, 36  
 rectal, 291*f*
- Extraarticular fracture, of  
 calcaneus, 440, 441*f*
- Extraperitoneal fascia,  
 202*f*
- F**
- Face  
 arteries of, 5-7, 6*f*  
 fractures of, 3-15
- Facial artery, 5, 6*f*, 7
- Facial bones, 3-5
- Facial fractures, 13
- Facial (VI) nerve, 9-10
- Facial skeleton, 3-5
- Falciform ligament, 186,  
 233, 235*f*, 236, 242*f*,  
 244*f*
- Fallot, tetralogy of, 80
- False pelvis, 297
- False ribs, 130*f*
- Fascia lata, 401*f*, 402
- Femoral artery, 401*f*,  
 403-406, 404*f*-405*f*  
 inguinal ligament and,  
 207-208
- Femoral head, arteries of,  
 405*f*
- Femoral hernia, 212

- Femoral nerve, 210*f*, 401*f*,  
402, 408
- Femoral vein  
  inguinal ligament and,  
  207-208  
  tributaries, 406
- Femur, 397, 399*f*
- Fibroadenomas, 52, 53*f*
- Fibrocystic disease, of  
  breast, 51*f*, 52
- Fibroid (submucous), in  
  uterus, 333*f*-335*f*  
  histology of, 335*f*
- Fibroma, of lung, 114
- Fibromuscular tube, 115
- Fibrous cord with  
  intermediate cyst,  
  277*f*
- Fibrous pericardium, 65
- Fibula, 413, 414*f*  
  fractures of, 428
- Fibular (peroneal) artery,  
  419*f*, 420
- Fibular fractures, 428
- Fimbriae, 326*f*
- Fine needle aspiration  
  biopsy (FNAB), 50
- Finger injuries, 393*f*
- Flail chest, 134*f*, 135
- Flexor carpi radialis  
  tendon, 385*f*
- Flexor carpi ulnaris  
  muscle, 369, 373-374
- Flexor carpi ulnaris  
  tendon, 385*f*
- Flexor digitorum  
  profundus muscle,  
  371*f*, 373
- Flexor digitorum  
  profundus tendons,  
  369, 384, 385*f*-386*f*  
  avulsion of, 393*f*
- Flexor digitorum  
  superficialis muscle,  
  369, 373
- Flexor digitorum  
  superficialis tendons,  
  384, 385*f*-386*f*
- Flexor hallucis longus  
  muscle, 429
- Flexor muscles, of  
  forearm, 370*f*
- Flexor pollicis longus  
  muscle, 369
- Flexor pollicis longus  
  tendon, 385*f*-386*f*
- Flexor retinaculum, 373,  
  384, 385*f*
- Floating ribs, 130*f*
- FNAB. *see* Fine needle  
  aspiration biopsy  
  (FNAB)
- Focal nodular hyperplasia,  
  247
- Follicular thyroid  
  carcinoma, 23
- Foot  
  anatomy of, 429-434  
  arterial supply of, 435  
  bones of, 430*f*  
  compartments of,  
  432-434  
  fractures of, 429-440  
  joints of, 431-432  
  ligaments of, 432  
  venous drainage of, 435

Foramen ovale, 67*f*  
 patent, 80  
 Foramen primum, 69, 70*f*  
 Foramina transversaria,  
 29  
 Forearm  
 anatomy of, 367-369,  
 368*f*  
 arterial supply of,  
 369-372, 371*f*  
 compartment syndrome  
 of, 369, 374, 387  
 compartments of, 369,  
 370*f*  
 fractures of, 367-379,  
 378*f*  
 nerves of, 360*f*, 373-374  
 veins of, 372-373  
 Fossa ovalis, 66*f*  
 Fractures  
 of dens, 39*f*  
 in thoracic injuries,  
 133-135, 134*f*  
 Frontal bone, 3, 4*f*  
 Fundus, of stomach, 181,  
 182*f*

## G

Galeazzi fractures, 379  
 Gallbladder, 149-151,  
 150*f*, 154-155, 158  
 carcinoma of, 162  
 inflammation of, 159*f*,  
 161  
 Gallstone pancreatitis,  
 162  
 Gallstones, 263  
 Ganglia, 131*f*  
 Gangrenous appendicitis,  
 146*f*  
 Gastric artery, 119, 120*f*,  
 188*f*-189*f*, 191, 241,  
 242*f*, 243  
 Gastric lymph nodes, left,  
 122, 123*f*  
 Gastric nodes, 194*f*  
 left, 157*f*  
 Gastric ulcer, 195*f*  
 Gastric veins, 121*f*,  
 191-193, 192*f*, 244*f*  
 Gastrinoma, 263  
 Gastritis, 193, 199  
 Gastroduodenal artery,  
 155*f*, 189*f*-190*f*, 191,  
 241, 242*f*, 257*f*  
 Gastroduodenal diseases,  
 181-200  
 Gastroduodenal  
 embryology, 186-187  
 Gastroesophageal reflux  
 disease (GERD),  
 124-126, 125*f*, 196  
 Gastrointestinal stromal  
 tumor (GIST), 199,  
 279  
 Gastro-omental  
 (gastroepiploic)  
 arteries, 188*f*-189*f*,  
 191, 256  
 Gastro-omental  
 (gastroepiploic) node,  
 194*f*  
 Gastro-omental  
 (gastro-epiploic) vein,  
 192*f*

- Genicular arteries, 420
- Genitalia  
 lymph vessels of, 331*f*  
 nodes of, 331*f*
- Genitofemoral nerve,  
 202*f*, 207, 210*f*
- Genitourinary infections,  
 endocarditis and, 88*f*
- GERD. *see*  
 Gastroesophageal  
 reflux disease (GERD)
- GIST. *see* Gastrointestinal  
 stromal tumor (GIST)
- Glenohumeral joint, 345,  
 353  
 arterial supply of,  
 356-359  
 brachial plexus and,  
 362
- Glenoid cavity, 355*f*
- Glenoid fossa, 343, 344*f*  
 fractures of, 345,  
 349-351
- Glenoid labrum, 353, 355*f*
- Glossopharyngeal (IX)  
 nerve, 10
- Glucagon-like peptide 2  
 (GLP-2), 268
- Glucagonoma, 263
- Gluteal artery  
 inferior, 302*f*  
 superior, 302*f*
- Gluteal compartment,  
 402
- Gluteal nerves, 408
- Gluteus maximus, 401*f*,  
 402
- Graves' disease, 22*f*
- Great auricular nerve (C2,  
 3), 8*f*
- Great cardiac vein, 75*f*,  
 76
- Greater curvature, of  
 stomach, 186
- Greater occipital nerve  
 (C2), 8*f*
- Greater pancreatic artery,  
 257*f*
- Greater thoracic  
 splanchnic nerves,  
 small intestine and,  
 269*f*
- Greater trochanter, 397,  
 399*f*
- Greater tubercle, 354*f*
- H**
- Hamartomas, of lung,  
 113-114
- Hamate bone, 381, 382*f*,  
 385*f*, 388*f*, 391*f*
- Hand  
 anatomy of, 381-387,  
 382*f*-383*f*  
 arterial supply of,  
 387-389, 388*f*  
 compartment syndrome  
 of, 390-392  
 compartments of,  
 384-387, 385*f*  
 fractures of, 381-392  
 joints of, 381-384  
 ligaments of, 384  
 nerves of, 389-390  
 venous drainage of, 389

- Hangman fracture, 39*f*  
 Hartmann's pouch, 150*f*  
     calculus in, 159*f*  
 Haustra, 163, 165  
 Head and neck  
     cutaneous nerves of, 8*f*  
     innervation of, 9-10  
 Head of pancreas, 254*f*  
 Heart, 63*f*  
     anatomy of, 61-73  
     arteries of, 73, 75*f*  
     external features of,  
         61-62, 64*f*  
     innervation of, 72-73  
     internal features of,  
         62-65, 66*f*-67*f*  
     lymphatics of, 73-77  
     nerves of, 74*f*  
     veins of, 73-76  
     vessels of, 73-77  
 Heart chambers, division  
     of, 70*f*  
 Heart diseases, 61-87  
 "Heartburn,"  
     cardiovascular disease  
     in women and, 83*f*  
 Hematocele, ectopic  
     pregnancy with, 339*f*  
 Hematometra, vs. ovarian  
     cyst, 336*f*  
 Hemiazygos vein, 119,  
     121*f*, 133  
 Hemorrhoidal plexus, 168  
     venous, 292  
 Hemorrhoids, 292  
 Hemothorax, 91, 102-106,  
     107*f*  
     persistent, 106  
 Hepatic arteries, 150*f*,  
     151, 154-155, 155*f*,  
     241, 242*f*, 243  
     branches of, 236, 238,  
         239*f*-240*f*  
     injury from dissection,  
         162  
     proper, 233, 234*f*, 238,  
         239*f*, 241  
 Hepatic duct, 149, 150*f*,  
     151  
     variations in, 152*f*, 153  
 Hepatic encephalopathy,  
     247  
 Hepatic nodes, 156, 157*f*,  
     245*f*  
 Hepatic plexus, 188*f*, 238  
 Hepatic veins, 238, 239*f*,  
     243  
     cirrhosis and, 250*f*  
 Hepatocellular carcinoma,  
     247  
 Hepatoduodenal ligament,  
     182*f*, 184, 233, 234*f*  
 Hepatogastric ligament,  
     182*f*, 186, 233, 234*f*  
 Hepatopancreatic ampulla  
     (Vater), 150*f*, 154,  
     185  
 Hepatopancreatic  
     sphincter (of Oddi),  
     154, 255  
 Hernias, 201-215  
     femoral, 212  
     hiatal, 126, 196, 197*f*,  
         215, 216*f*  
     incarceration of, 208  
     incisional, 213, 214*f*



- Hernias (*continued*)  
 inguinal, 206, 208-212, 209*f*  
 approaches to, 211-212  
 direct, 211  
 indirect, 211  
 types of, 211  
 lumbar, 215  
 obturator, 213-215  
 parastomal, 215  
 perineal hernia, 215  
 reduction of, 208  
 repair, inguinal  
   landmarks in, 210*f*  
 sciatic, 215  
 small bowel obstruction to, 273  
 spigelian, 214*f*, 215  
 strangulation of, 208  
 umbilical, 212-213, 214*f*
- Herniation, of lumbar disc, 41*f*
- Hesselbach's triangle, 206, 211
- Hiatal hernia, 126, 196, 197*f*, 215, 216*f*
- Hilton's law, 300-301, 359, 373, 408, 422, 435
- Hip  
 anatomy of, 397-403  
 fractures of, 397-412  
 joint of. *see* Hip joint  
 nerves of, 408  
 veins of, 406
- Hip joint, 397-400  
 arterial supply to, 403-406, 405*f*  
 and ligaments, 398*f*
- Humeral head, 353, 354*f*  
 dislocations of, 365  
 fractures of, 363*f*
- Humerus  
 anatomy of, 353-356, 354*f*  
 arterial supply to, 356-359, 358*f*  
 artery in, 347*f*, 348  
 elbow joint and, 367  
 fractures of, 353-366, 363*f*-364*f*, 374  
 distal, 365-366  
 proximal, 365  
 shaft, 365  
 neck of, 353, 354*f*, 363*f*-364*f*
- Hürtle cell carcinoma, 23
- Hydatid mole, *vs.* ovarian cyst, 336*f*
- Hydatidiform mole, 333*f*-334*f*
- Hydramnios, *vs.* ovarian cyst, 336*f*
- Hyoid bone, 27
- Hypertonic stomach, 182*f*
- Hypertrophic prostate, 321*f*
- Hypertrophy, intravesical view of, 321*f*
- Hypogastric nerves, 288*f*, 315*f*

- Hypogastric plexus, 166, 301  
 prostate and, 314  
 superior, 315*f*  
 rectum and, 288*f*
- Hypoglossal (XII) nerve, 10
- Hypothenar compartment, 387
- Hypotonic stomach, 182*f*
- I**
- Ileal arteries, small  
 intestine and, 271*f*
- Ileal branch, 140*f*  
 small intestine and, 271*f*
- Ileal veins, small intestine and, 272*f*
- Ileal vessels, small  
 intestine and, 272*f*
- Ileocecal fold, 140*f*, 142
- Ileocecal fossa, 142
- Ileocecal junction, 165
- Ileocecal recess, 140*f*
- Ileocolic artery, 140*f*, 142-143, 166, 167*f*, 269*f*, 270, 271*f*
- Ileocolic fold, 142
- Ileocolic intussusception, 275*f*
- Ileocolic nodes, 144*f*, 170*f*
- Ileocolic vein, 143, 143*f*, 168, 169*f*, 272*f*, 273
- Ileo-ileocolic  
 intussusception, 275*f*
- Ileum, 265, 266*f*-267*f*  
 arterial supply of, 270  
 leiomyosarcoma of, 279  
 lymphoma in, 279  
 Peyer's patches, 273  
 terminal  
 appendix and, 139, 140*f*, 142  
 Crohn's disease of, 280*f*  
 venous drainage of, 273
- Iliac artery  
 common, 302*f*  
 crossing of, 227*f*  
 deep circumflex, 303  
 external, 207-208, 302*f*  
 internal, 302*f*  
 rectal branches of, 168, 290*f*  
 uterus and, 328, 329*f*
- Iliac crest, 27
- Iliac fossa, 298*f*, 303
- Iliac nodes, 225*f*
- Iliac vein  
 common, 303  
 deep circumflex, 303  
 external, 207-208, 303  
 internal, 168, 291*f*
- Iliac vessels, external, 143*f*
- Iliac wing, fractures of, 306*f*
- Iliacus muscle, 210*f*
- Iliofemoral (Bigelow)  
 ligament, 297, 400
- Iliolumbar artery, 302*f*
- Iliolumbar ligament, 298*f*
- Iliolumbar veins, 303

- Iliopubic tract, 206, 210*f*
- Ilium, 297, 397
- Incisional hernia, 213, 214*f*
- Infarction, pulmonary, secondary to embolization, 108
- Infectious mastitis, 52-54
- Inferior anal (rectal) nerve, 288*f*
- Inferior lateral genicular artery, 419*f*, 420
- Inferior medial genicular artery, 419*f*, 420
- Inferior mesenteric artery
  - colon and, 165-166, 167*f*, 171
  - rectum, 290*f*
- Inferior mesenteric ganglion, 166, 288*f*
- Inferior mesenteric nodes, 170*f*, 171, 293*f*
- Inferior mesenteric plexus, 166, 288*f*, 315*f*
- Inferior mesenteric vein, 168, 169*f*, 243, 291*f*
- Inferior pancreatic artery, 257*f*
- Inferior
  - pancreaticoduodenal to 1st jejunal artery, small intestine and, 271*f*
- Inferior rectal artery, 290*f*
- Inferior rectal vein, 291*f*
- Inferior tibiofibular (syndesmosis), 432
- Inferior vena cava, 61-62, 64*f*, 66*f*
- Inferior vesical artery, 329*f*
- Inflammatory bowel disease, 175, 273
- Infrahyoid muscles, 17
- Infraorbital nerve, 8*f*
- Infraspinatus muscle, 349
- Infraspinatus tendon, 353, 355*f*
- Infratrochlear nerve, 8*f*
- Infundibulum, 150*f*, 326*f*
- Inguinal canal, boundaries of, 206
- Inguinal hernia, 206, 208-212, 209*f*
  - approaches to, 211-212
  - direct, 211
  - indirect, 211
  - types of, 211
- Inguinal ligament, 201, 202*f*, 203, 206, 208, 297
- Inguinal ring
  - deep (internal), 202*f*, 204, 207-208, 211
  - superficial (external), 203, 206, 209*f*, 211
- Innervation
  - of heart, 72-73
  - of lungs, 96, 97*f*
- Insulinoma, 263
- Interatrial septum, 66*f*
- Intercostal arteries, 131*f*, 132-133
- Intercostal muscles, 129, 131*f*, 132

- Intercostal nerve block,  
134*f*, 135
- Intercostal nerves, 131*f*,  
132
- Intercostal nodes, 123*f*
- Intercostal veins, 133
- Intermediate cuneiform,  
430*f*, 431
- Intermesenteric (aortic)  
plexus, 269*f*
- Intermuscular septa, 402
- Internal anal sphincter  
muscle, 286
- Internal carotid artery, 7
- Internal iliac nodes, 293*f*,  
318*f*, 331*f*  
pathway from lower  
prostate, 318*f*
- Internal jugular vein, 6*f*,  
7-9, 18*f*, 20*f*
- Internal mammary  
(thoracic) artery, 82
- Internal oblique (IO)  
muscle, 201, 202*f*,  
203-204  
inguinal canal and,  
206
- Internal (epidural) plexus,  
36
- Internal rectal plexus,  
291*f*
- Internal rectal venous  
plexus, 286*f*
- Internal sphincter muscle,  
286*f*
- Internal thoracic  
(mammary) artery,  
131*f*, 133, 242*f*
- Internal thoracic  
(mammary) veins,  
133
- Interosseous artery, 371*f*,  
372
- Interosseous  
compartment, 387
- Interosseous fascia, 386*f*,  
387
- Interosseous membrane,  
of forearm, 368*f*, 369,  
377*f*
- Interosseous muscles, of  
hand, 387, 388*f*
- Interosseous nerve, 369,  
371*f*
- Interphalangeal joints,  
384  
dislocations of, 394*f*
- Interspinous ligament, 32
- Interstitial (intramural),  
335*f*
- Interstitial lymphatic  
drainage, 76-77
- Interventricular septum,  
66*f*
- Intervertebral disc, 30*f*
- Intestinal lymphatic  
trunk, 274*f*
- Intraarticular fracture, of  
calcaneus, 440, 441*f*
- Intracapsular fractures,  
409*f*, 410
- Intraligamentary, 335*f*
- Intrapulmonary blood  
circulation, 100*f*
- Intussusception, 273-276,  
275*f*

Ischemic colitis, 175  
Ischial ramus, 297  
  fracture of, 306*f*  
Ischial spine, 297, 298*f*,  
  398*f*  
Ischial tuberosity, 297,  
  298*f*, 398*f*  
Ischiofemoral ligament,  
  398*f*, 405*f*  
Ischium, 297, 300, 397  
Isthmus, 326*f*

## J

Jefferson fracture of atlas  
  (C1), 39*f*  
Jejunal arteries, small  
  intestine and, 271*f*  
Jejunal veins, small  
  intestine and, 272*f*  
Jejunal vessels, small  
  intestine and, 272*f*  
Jejunum, 265, 266*f*-267*f*  
  arterial supply of, 270  
  Crohn's disease of, 280*f*  
  duodenum and, 184*f*  
  leiomyosarcoma of, 279  
  venous drainage of, 273  
Judet-Letournel  
  classification, 309  
Jugular (suprasternal)  
  notch, 130, 130*f*  
Jugular vein, internal, 6*f*,  
  7-9  
Juvenile polyps, of colon,  
  173  
Juxtaintestinal group,  
  274*f*

## K

Kidney stones, 226-229,  
  227*f*  
Kidneys  
  anatomy of, 217-222,  
    218*f*-219*f*  
  arterial supply of, 222,  
    223*f*-224*f*  
  cancer of, 229  
  collecting system of,  
    220  
  innervation of, 220-222,  
    221*f*  
  internal structure of,  
    217-220  
  lymph vessels and  
    nodes of, 220-222  
  lymphatic drainage of,  
    226  
  obstructive uropathy  
    and, 228*f*  
  position of, 217  
  surgical approaches to,  
    230*f*  
  venous drainage of, 222,  
    224*f*  
Kiesselbach's area/plexus,  
  7  
Knee  
  anatomy of, 413-418  
  fractures of, 413-428  
  ligaments of, sprains of,  
    426*f*  
  lymph vessels of, 423*f*  
  nodes of, 423*f*  
  veins of, 420, 423*f*  
Knee joint(s), 413-416,  
  415*f*

## L

- Lachman test, 425*f*
- Lacrimal bone, 3
- Lacrimal nerve, palpebral branch of, 8*f*
- Lactiferous ducts, 45, 46*f*
- Lactiferous glands, 45
- Lacunar ligament, 201, 206
- Lamina, 30*f*
- Lamina propria, appendix and, 139
- Large bowel obstruction, 178
- Large cell anaplastic carcinoma, of lungs, 111
- Large intestine  
arteries of, 167*f*  
lymph drainage of, 144*f*  
lymphatic drainage of, 170*f*  
obstruction of, in  
  colorectal cancer, 173, 174*f*, 178  
  veins of, 143*f*, 169*f*
- Laryngeal artery, superior, 20*f*
- Laryngeal nerve  
  recurrent, 18*f*, 20*f*, 21  
  esophagus and, 117, 118*f*  
  superior, 18*f*, 20*f*
- Lateral circumflex  
  retinacular arteries, 406
- Lateral (fibular) collateral ligament, 415*f*, 416
- Lateral compartment, of leg, 417*f*, 418
- Lateral cuneiform, 430*f*, 431
- Lateral femoral circumflex artery, 403, 404*f*-405*f*
- Lateral femoral cutaneous nerve, 210*f*
- Lateral meniscus, 415, 415*f*
- Lateral plantar nerve, 434*f*, 436
- LCIS. *see* Lobular carcinoma in situ (LCIS)
- Le Fort classification, 12*f*, 13-15
- Left atrium, 61-62, 64*f*, 67*f*  
  internal features of, 67*f*
- Left colic nodes, 293*f*
- Left marginal ventricular veins, 75*f*, 76
- Left ventricle, 61-62, 63*f*  
  internal features of, 67*f*
- Leg  
  anatomy of, 413-418  
  arterial supply of, 418-420, 419*f*, 421*f*  
  bones of, 414*f*. *see also* Fibula; Tibia  
  compartments of, 416-418, 417*f*  
  syndrome in, 422  
  fractures of, 413-428  
  lymph vessels of, 423*f*  
  nerves of, 419*f*, 421*f*, 422

- Leg (*continued*)  
 nodes of, 423*f*  
 veins of, 420, 423*f*
- Leiomyoma, esophageal, 127
- Lesser occipital nerve (C2), 8*f*
- Lesser omentum, 233, 234*f*
- Lesser thoracic splanchnic nerves, small intestine and, 269*f*
- Levator ani muscle, 286, 286*f*
- Ligament of Treitz, 185, 264*f*
- Ligamenta flava, 32
- Ligamentum nuchae, 32
- Ligamentum teres, 234*f*-235*f*, 400
- Ligamentum venosum, 235*f*
- Linea alba, 205  
 hernia of, 214*f*
- Linea semilunaris, hernia of, 214*f*
- Linea terminalis, 299
- Linear, skull fractures, 10-13
- Lingual artery, 5
- Lipomas, endobronchial, 114
- Liver  
 abscesses of, 251-252  
 anatomy of, 233-241  
 arterial supply of, 241-243, 242*f*
- Liver (*continued*)  
 arteries of, 257*f*  
 carcinoma of tail  
 adherent to, 262*f*  
 cirrhosis of, 247-251, 249*f*-250*f*  
 collateral supply of, 242*f*  
 divisions of, 236-238  
 functions of, 246  
 hemobilia and, 252  
 hepatic venous drainage of, 243  
 innervation of, 234*f*-235*f*, 238-241, 240*f*  
 lobes of, 234*f*-235*f*, 236-238, 237*f*  
 lymphatic drainage of, 240*f*, 243-246, 245*f*  
 portal venous supply of, 243  
 segments of, 236-238, 237*f*  
 surfaces and bed of, 235*f*  
 trauma to, 246, 252  
 tumors of, 248*f*-249*f*  
 benign, 246-247  
 malignant, 247  
 vessel and duct  
 distribution of, 239*f*
- Liver failure, 247-251
- Liver function tests, 160
- Lobar bronchus, 94
- Lobes, of lung, 92
- Lobular carcinoma in situ (LCIS), 54

- Lower limb enlargement,  
34
- Lumbar curvature, 27, 28*f*
- Lumbar disc, herniation  
of, 41*f*
- Lumbar hernia, 215
- Lumbar plexus, 35*f*
- Lumbar vertebrae, 30*f*, 31
- Lumbosacral roots, 34
- Lumbrical muscles, 386*f*  
nerve to, 388*f*
- Lumpectomy, 59
- Lunate bone, 381,  
382*f*-383*f*
- Lung cancer, 109-114
- Lung diseases, 91-114
- Lungs  
anatomy of, 91-96, 93*f*  
bronchi, 94-96  
bronchopulmonary  
segments, 94-96  
external features of,  
91-92  
innervation in, 96,  
97*f*  
trachea, 92-94  
clinical correlates of,  
102-114  
benign tumors, 114  
bronchial adenomas,  
113  
bronchogenic  
carcinoma,  
109-111, 112*f*  
hamartomas, 113-114  
hemothorax, 102-106,  
107*f*  
mesothelioma, 113
- Lungs (*continued*)  
Pancoast syndrome,  
111-113  
pneumothorax, 102,  
105*f*  
pulmonary embolism,  
106-109  
superior vena cava  
syndrome, 113  
lymphatics of, 96-102  
lymphatic drainage,  
98-102, 103*f*  
trauma to, 133, 134*f*, 135  
vessels of, 96-102, 99*f*  
bronchial arteries, 98,  
101*f*  
bronchial veins, 98,  
101*f*  
pulmonary arteries,  
96-98  
pulmonary veins, 98
- Luschka, ducts of, 153
- Lymph drainage, of large  
intestine, 144*f*
- Lymph nodes  
carcinoma of tail  
adherent to, 262*f*  
esophagus and, 123*f*  
kidneys and, 220-222,  
226  
large intestine and, 170*f*  
liver and, 243-246, 245*f*  
of pancreas, 157*f*  
pelvic, prostate and,  
317  
status, 59  
of stomach, 194*f*  
stomach and, 245*f*



Lymph vessels, 260*f*  
of small intestine, 274*f*  
Lymphatic capillaries, 76  
Lymphatic drainage  
of lung  
on left side, 102  
on right side, 98  
routes of, 103*f*  
of thyroid, 21  
Lymphatics  
esophageal, 119-122  
of lungs, 96-102  
Lymphoma, of stomach,  
199

## M

Magnesium ammonium  
phosphate, 226  
Magnetic resonance  
imaging (MRI), 50  
Maisonneuve fracture, 438*f*  
Malignant lymphoma, of  
thyroid, 23  
Malleolar fractures, 428  
Malleoli, 429  
Mallet finger, 393*f*  
Mammary (internal  
thoracic) arteries,  
131*f*, 133, 242*f*  
Mammary gland, 46*f*  
Mammary ridges,  
embryonic, 47  
Mammary (internal  
thoracic) veins, 133  
Mandible, 3, 4*f*, 27  
Mandible fractures, 15,  
16*f*  
Mandibular division of  
trigeminal nerve (V<sub>3</sub>),  
8*f*, 9  
Manubriosternal joint, 132  
Manubrium, 130, 130*f*  
Marginal artery, 167*f*, 168,  
270  
Maxilla, 3, 4*f*  
Maxillary arteries, 5  
Maxillary division of  
trigeminal nerve (V<sub>2</sub>),  
8*f*, 9  
McBurney's point, 141*f*,  
147  
Meckel's diverticulum,  
171, 273, 277*f*  
ileal, 276-278  
Medial collateral ligament.  
see Tibial (medial)  
collateral ligament  
Medial compartment, of  
thigh, 403  
Medial cuneiform, 430*f*,  
431  
Medial epicondyle, 354*f*  
Medial (inferior) external  
iliac nodes, 331*f*  
Medial femoral circumflex  
artery, 403, 404*f*-405*f*  
Medial meniscus, 415,  
415*f*  
Medial plantar nerve,  
434*f*, 436  
Median nerve, 357*f*, 360*f*  
in forearm, 369,  
370*f*-371*f*, 373  
in wrist and hand, 384,  
385*f*, 388*f*, 389-390

- Medulla, of kidney, 220  
Medullary thyroid carcinoma, 23  
Meissner's plexus, 164-165, 183, 186-187, 268, 287  
Membranous septum, 67*f*, 71  
Mental nerve, 8*f*  
Mesenteric branches, small intestine and, 269*f*  
Mesenteric nodes, superior, 260*f*  
Mesentery, 142, 163, 164*f*, 184, 184*f*, 186-187  
Mesoappendix, 139, 140*f*-141*f*, 142  
Mesocolic taenia, 140*f*  
Mesocolon, 254*f*  
Mesogastrium, 186  
Mesometrium, 325, 326*f*  
Mesosalpinx, 326*f*  
Mesothelioma, of lung, 113  
Metacarpal ligaments, 384  
Metacarpals, 381 fractures of, 392, 393*f*  
Metacarpophalangeal joints, 384, 393*f*  
Metastasis (M), 59  
Metatarsal bones, 430*f*, 431 fractures of, 440, 442*f*  
Middle cardiac vein, 76  
Middle meningeal artery, in skull fractures, 13  
Middle rectal artery, 290*f*, 329*f*  
Middle rectal nodes, 293*f*  
Middle rectal vein, 291*f*  
Mid-face fractures, 12*f*, 13-15  
Midpalmar space, 386*f*, 387  
Mitral regurgitation, 86  
Mitral stenosis, 86  
Mitral valve, 62, 67*f*  
Monteggia fracture/dislocation, 376*f*, 379  
Montgomery's tubercles, 45  
Motilin, 268  
MRI. *see* Magnetic resonance imaging (MRI)  
Mucosa of colon, 163-165 of duodenum, 185 esophageal, 117 small intestine and, 266-268, 267*f* of stomach, 183  
Multilocular serous cystadenoma, 339*f*  
Murphy's sign, 161  
Muscularis of duodenum, 186 of stomach, 183  
Musculocutaneous nerve, 356, 357*f*, 360*f*, 362  
Musculophrenic arteries, 133  
Myocardial infarction, complications of, 82  
Myoelectric pacemaker, for peristalsis, 183

## N

- Nasal bone, 3, 4*f*  
Nasal fractures, 13  
Navicular, 429, 430*f*  
Nephroblastoma (Wilms' tumor), 229  
Nerve root compression, 41*f*  
Nervi erigentes, 301  
Neurocranium, 3  
Neurovascular bundles, 314  
Neurovascular supply, of skull, 5-10  
Nipple, 45  
    retraction of, 55, 57*f*  
Nodes, of small intestine, 274*f*  
Nucleus pulposus, 30*f*, 32  
Nutmacker configuration, 222
- O**
- Oblique pericardial sinus, 68  
Oblique rib fracture, 134*f*  
Obturator artery, 210*f*, 329*f*, 404*f*-405*f*, 406  
Obturator foramen, 297, 301  
Obturator hernia, 213-215  
Obturator nerve, 301, 408  
Obturator node, 331*f*  
Obturator (pelvic) nodes, 317  
Occipital artery, 5  
Occipital bone, 3  
Oculomotor (III) nerve, 9  
Olecranon, 367, 368*f*  
    fractures of, 374-379, 375*f*  
Olecranon fossa, 354*f*  
Olfactory (I) nerve, 9  
Omental (epiploic) appendices, 163, 172*f*  
Omental (epiploic) foramen (of Winslow), 233, 234*f*  
Omentum  
    greater, 163, 182*f*, 186, 266*f*  
    lesser, 182*f*, 184, 186, 233, 234*f*  
Ophthalmic artery, 7  
Ophthalmic division of trigeminal nerve (V<sub>1</sub>), 8*f*, 9  
Optic (II) nerve, 9  
Orthotonic stomach, 182*f*  
Osteonecrosis, 409*f*  
Ostium secundum, 71  
Ovarian arteries, 328  
Ovarian cysts, 332-337  
    differential diagnosis of, 336*f*  
Ovarian tumors, 338-340, 339*f*  
Ovarian veins, 330  
Ovaries, 326*f*, 327-328, 337*f*  
    endometriosis in, 337-338, 337*f*  
    ligament of, 326*f*  
    lymphatic drainage of, 332

Overriding aorta, 80  
 Overriding rib fracture,  
 134*f*

## P

P cells, 62  
 Pacemaker rate, 65  
 Pacemakers, 87, 89*f*  
 Paget's disease of the  
 breast, 55  
 Palmar aponeurosis,  
 386*f*  
 Palmar arch  
 deep, 389  
 superficial, 387-389,  
 388*f*  
 Palmar digital artery,  
 386*f*, 388*f*, 389  
 Palmar digital nerve, 386*f*,  
 388*f*, 390  
 Palmar interosseous  
 fascia, 386*f*  
 Palmar ligaments, 384  
 Palmar metacarpal  
 arteries, 388*f*, 389  
 Pancoast syndrome,  
 111-113  
 Pancreas  
 anatomy of, 253-256,  
 254*f*  
 arterial supply of, 256  
 arteries of, 190*f*, 257*f*  
 artery to tail of, 257*f*  
 carcinoma of, 262*f*  
 clinical correlates and,  
 259-263  
 duct system, 254-255

Pancreas (*continued*)  
 duodenum and,  
 184-185, 184*f*, 187  
 functional anatomy of,  
 255-256  
 innervation of, 256  
 islet carcinomas of, 247  
 locale of, 253  
 location of, 253  
 lymph nodes of, 157*f*  
 lymphatic drainage of,  
 259  
 lymphatics of, 256-259  
 nodes of, 260*f*  
 tumors of, 200  
 uncinate process of,  
 253-256  
 veins of, 192*f*, 258*f*  
 venous drainage of,  
 259  
 vessels of, 256-259  
 Pancreatic artery  
 dorsal, 257*f*  
 inferior, 257*f*  
 Pancreatic cancer, 261  
 Pancreatic diseases,  
 253-263  
 Pancreatic duct, 150*f*,  
 254-255  
 accessory, 185, 255  
 Pancreatic nodes,  
 superior, 260*f*  
 Pancreatic vein, 258*f*  
 Pancreaticoduodenal  
 artery, 190*f*, 191,  
 256, 270  
 anterior inferior, 257*f*  
 anterior superior, 257*f*

- Pancreaticoduodenal
  - artery (*continued*)
  - posterior inferior, 257f
  - posterior superior, 257f
- Pancreaticoduodenal
  - nodes, 157f, 260f
- Pancreaticoduodenal vein, 192f
  - anterior inferior, 258f
  - anterior superior, 258f
  - posterior inferior, 258f
  - posterior superior, 258f
  - superior and inferior, 259
- Pancreatitis, 162, 259-261
- Papillary serous
  - cystadeno-carcinoma, 339f
- Papillary thyroid
  - carcinoma, 23
- Papillomas, 52
- Paraesophageal hernia, 197f
- Parafollicular (C) cells, 19
- Paraneoplastic syndromes, of lung, 111
- Praoovarian cyst, 339f
- Parastomal hernia, 215
- Parasympathetic
  - preganglionic fibers, 72
  - of esophagus, 117
  - of lungs, 96
- Parathyroidectomy
  - incision, 24f
- Parathyroids, 19, 20f
- Paratracheal nodes, 123f
- Parietal bone, 3, 4f
- Parietal nodes, 123f
- Parietal (serous)
  - pericardium, 65
- Parietal pleura, of lungs, 91
- Pars interarticularis, 30f
- Patella, 413
- Patellar fractures, 422-427
- Patellar tendon, 413
- Patellofemoral joint, 413
- Patent ductus arteriosus, 79-80
- Patent foramen ovale, 80
- PCL. *see* Posterior
  - cruciate ligament (PCL)
- Peau d'orange appearance
  - in breast cancer, 56
  - as clinical signs of breast cancer, 58f
- Pecten pubis, 299
- Pectineal (Cooper)
  - ligament, 201, 211
- Pectineal line, 299
- Pectoral girdle, 129, 354f
  - anatomy of, 343-346, 344f
  - fractures of, 343-351, 350f
- Pectoral nerves, 360f, 362
- Pectoralis major muscle, 129, 361f
- Pectoralis minor muscle, 129
- Pectoralis minor tendon, 361f
- Pelvic cavity, 312f
- Pelvic fractures, 297-309

- Pelvic inflammation, 333*f*-334*f*
- Pelvic parasympathetic efferents, 314
- Pelvic plexus, 166, 288*f*, 315*f*
- Pelvic splanchnic nerves, 165, 288*f*, 315*f*
- Pelvis, 332
- arteries of, 301-303, 302*f*, 316*f*
  - in female, 329*f*
  - fractures of, 303-307, 306*f*
  - classification of, 305*f*
  - joints, 300
  - ligaments of, 298*f*, 300
  - lymph vessels of, 331*f*
  - nerves of, 300-301
  - neurovascular supply of, 300-303
  - nodes of, 331*f*
  - skeleton, anatomy of, 297-300
  - veins of, 302*f*, 316*f*
  - venous drainage of, 303
- Penis
- cavernous nerves of, 315*f*
  - deep dorsal vein and dorsal artery, 316*f*
- Peptic reflux, complications of, 125*f*
- Peptic ulcer, 193-196, 195*f*
- Peptide YY (PYY), 268
- Percutaneous transluminal coronary angioplasty (PTCA), 82
- Perforating branches, of deep femoral artery, 403, 404*f*
- Pericardiacophrenic arteries, 68
- Pericardium, 65-68
- Perimuscular rectal plexuses, 291*f*
- Perineal lymph vessels, 293*f*
- Perineum, 301
- Peritoneal reflection, 286*f*
- Peritoneal sac, lesser, 233
- Peritoneum, 201, 202*f*
- Peritonitis, 145
- Peroneal (fibular) artery, 435
- Peroneal (fibular, posterior) divisions, of sciatic nerve, 436
- Persistent hemothorax, 106
- Persistent truncus arteriosus, 80
- Pes anserinus, 416
- Peyer's patches, 185, 267*f*, 273
- Phalangeal fractures, of hand, 392, 393*f*
- Phalanges, 430*f*, 431
- fractures of, 440, 442*f*
  - of hand, 381, 382*f*
- Pharynx, posterior view, 18*f*
- Phrenic arteries, inferior, 119, 120*f*
- Phrenic artery, inferior, 242*f*

- Phrenic nerves, 68, 241
- Phrenic nodes, 123*f*,  
243-246, 245*f*
- Phrenic vein, left inferior,  
121*f*
- Phyllodes tumors, 52
- Pilon fracture, 428
- Pisiform bone, 381,  
382*f*-383*f*, 390
- Placenta previa, 333*f*-334*f*
- Plantar  
  compartment, of foot,  
  432-434  
  neurovascular bundles  
  of, 434
- Plicae circulares, 185, 265
- Pneumothorax, 91, 102  
  tension, 105*f*
- Polypoid adenocarcinoma,  
198*f*
- Polyps  
  of colon, 173  
  esophageal, 127
- Popliteal artery, 403,  
404*f*-405*f*, 406,  
418-420, 419*f*
- Popliteal vein, 420, 423*f*
- Porta hepatis, 235*f*
- Portal hypertension  
  cirrhosis and, 250*f*  
  hemorrhoids in, 168,  
  289
- Portal triads, 233, 234*f*,  
238, 245*f*
- Portal vein  
  duodenal drainage of,  
  191-193, 192*f*  
  hepatic, 243, 244*f*
- Portal vein (*continued*)  
  branches of, 238,  
  239*f*-240*f*  
  carcinoma in, 249*f*  
  esophagus and, 121*f*  
  hepatoduodenal  
  ligament and,  
  233, 234*f*, 243  
  pancreas and, 253,  
  258*f*  
  rectal venous plexuses  
  and, 289  
  small intestine and,  
  272*f*, 273  
  superior mesenteric  
  vein and, 143,  
  143*f*, 243  
  superior mesenteric  
  vein and, 168, 169*f*
- Posterior auricular artery,  
5, 6*f*
- Posterior compartment, of  
thigh, 402-403
- Posterior cruciate ligament  
(PCL), 415*f*, 416
- Posterior division, of  
  pelvic arteries, 329*f*
- Posterior external plexus,  
36
- Posterior femoral  
  cutaneous nerve, 407*f*
- Posterior left ventricular  
  veins, 76
- Posterior meniscofemoral  
  ligament (of  
  Humphrey), 415*f*, 416
- Posterior papillary muscle,  
67*f*

- Posterior superior iliac spine, 297, 298*f*
- Posterior tibial artery, 419*f*, 420, 435
- Posterior vagal trunk, small intestine and, 269*f*
- Postganglionic fibers, 165-166
- Pouches, position of, 326-327
- Preaortic lymph nodes, 331*f*
- Preaortic nodes, 293*f*, 318*f*
- Prececal nodes, 144*f*
- Preganglionic fibers, 165-166
- Pregnancy  
  appendicitis during, 145  
  vs. ovarian cyst, 336*f*
- Prevesical plexus, 318*f*
- Primary burn, esophageal, 128
- Primary curvatures, of vertebral column, 27
- Primary tumor (T), 59
- Primordium, of heart, 69
- Princeps pollicis artery, 388*f*, 389
- Processus vaginalis, 209*f*, 211
- Profunda brachii artery, 358*f*, 359, 372
- Profunda femoris (deep femoral) artery, 403, 404*f*-405*f*
- Progesterone, 47
- Promontorial (middle sacral) nodes, 318*f*, 331*f*
- Pronator quadratus muscle, 369, 373, 378*f*
- Pronator teres muscle, 371*f*, 373, 378*f*
- Proper hepatic artery, 150*f*, 154-155, 157*f*, 191
- Prophylaxis, for appendicitis, 147
- Prostate, 312*f*  
  anatomy of, 311  
  arterial supply of, 316-317  
  carcinoma of, 320-324  
  staging and treatment, 320-324  
  clinical correlates of, 317-324  
  lymphatic drainage of, 318*f*  
  lymphatics of, 317, 318*f*  
  venous drainage of, 317  
  vessels of, 316-317
- Prostate diseases, 311-324
- Prostate specific antigen (PSA), 317-319
- Prostatectomy  
  open, 319  
  radical, 323*f*  
  surgical approaches in, 324  
  transurethral (TURP), 319, 321*f*
- Prostatic capsule(s), 313-314



- Prostatic carcinoma, 322*f*
- Prostatic ducts, 314
- Prostatic fossa, 321*f*
- Prostatic innervation, 314
- Prostatic plexus, 315*f*
- Prostatic utricle, 312*f*
- Prostatic utriculus, 314
- Prostatic venous plexus, 317
- Prostatitis, 317
- Proximal interphalangeal joint dislocations, 394*f*
- PSA. *see* Prostate specific antigen (PSA)
- Pseudomembranous colitis, 175
- PTCA. *see* Percutaneous transluminal coronary angioplasty (PTCA)
- Pterion, 4*f*
- Pterygoid venous plexus of deep face, 7
- Pubic ramus
  - fracture of, 306*f*
  - inferior, 298*f*
  - superior, 298*f*
- Pubic symphysis, 298*f*, 300
- Pubic tubercle, 201, 203, 298*f*
- Pubis, 299, 397
- Pubofemoral ligament, 398*f*, 400
- Puboprostatic ligaments, 313
- Pudendal artery, internal, 290*f*, 302*f*
  - prostate, 316*f*
  - vagina and, 329*f*, 330
- Pudendal nerve, 288*f*
- Pudendal vein, internal, 291*f*
- Pulmonary artery, 61-62, 64*f*, 96-98
  - stenosis of, 80
- Pulmonary embolism, 106-109, 110*f*
  - infarction secondary to, 108
  - in pulmonary artery, 108
  - roentgenographic appearance of, 109
  - source of, 106-109
  - without infarction, 108
- Pulmonary infarction, secondary to embolization, 108
- Pulmonary infections, endocarditis and, 88*f*
- Pulmonary ligament, 92
- Pulmonary nerve plexus, 96
- Pulmonary stenosis, 81
- Pulmonary valve, 62, 66*f*
- Pulmonary veins, 61-62, 64*f*, 67*f*, 98
- Pulse generator, 87
- Purkinje fibers, 62
- Pyloric nodes, 157*f*, 260*f*
- Pylorus, 181, 182*f*, 184*f*
- Pylorus glands, 183
- Pyometra, *vs.* ovarian cyst, 336*f*

Pyramids, of kidney, 220  
 PYY. *see* Peptide YY (PYY)

## Q

Quadrante lobe, of liver,  
 234*f*-235*f*, 236, 237*f*,  
 243  
 Quadratus lumborum, 217

## R

Radial artery, 359  
 in forearm, 369,  
 370*f*-371*f*, 372  
 in wrist and hand, 385*f*,  
 387, 388*f*  
 Radial bursa, 386*f*, 387  
 Radial groove, 354*f*  
 Radial nerve, 356, 357*f*,  
 360*f*-361*f*, 362  
 in forearm, 369, 370*f*,  
 374  
 injury to, 365  
 in wrist and hand, 390  
 Radial scars, 54  
 Radial veins, 373  
 Radialis indicis artery,  
 388*f*, 389  
 Radical mastectomy, 59-60  
 Radical prostatectomy,  
 323*f*  
 Radiocarpal joint, 367,  
 381-384  
 Radiocarpal ligaments,  
 384  
 Radioulnar joints,  
 367-369

Radius, 367, 368*f*, 370*f*  
 fractures of, 374, 375*f*,  
 377*f*, 379, 380*f*,  
 390-392  
 Rectal artery, 166, 168  
 inferior, 316*f*  
 Rectal cancer, 294-296  
 Rectal plexus, 288*f*  
 Rectal veins, 168  
 Rectosigmoid arteries,  
 290*f*  
 Rectouterine pouch, 327  
 endometriosis in, 337*f*  
 Rectovaginal septum, 285  
 endometriosis of, 337*f*  
 Rectovesical septum, 313  
 Rectum, 285, 322*f*, 337*f*  
 arterial supply of, 165,  
 289  
 cancer of, 174*f*  
 and cancer of left colon,  
 174*f*  
 Crohn's disease of, 281  
 innervation of, 287-289  
 lymphatic drainage of,  
 292  
 pathway alongside to, in  
 prostate, 318*f*  
 venous drainage of,  
 289-292  
 Rectus abdominis, 201,  
 204-205, 207, 210*f*  
 Rectus femoris tendon  
 avulsion, 304  
 Rectus sheath, 203  
 Redundant sigmoid colon,  
*vs.* ovarian cyst, 336*f*  
 Regional enteritis, 280*f*

Renal (cortical) columns  
(Bertini), 220  
Renal fascia, 217  
Renal papilla, of kidney,  
220  
Renal pelvis, 220  
Retinacula, 400  
Retinacular arteries, 405*f*,  
406  
Retrocecal appendix, 141*f*  
Retrocecal recess, 140*f*  
Retromandibular vein, 6*f*,  
7  
Retropharyngeal danger  
space, 115  
Rhomboid muscle, 129  
Rib components,  
associated, of typical  
vertebrae, 27  
Ribs, 129-130, 130*f*  
fractures of, 129-135,  
134*f*  
Right atrium, 61-65,  
63*f*-64*f*  
internal features of, 66*f*  
Right ventricle, 61-62,  
63*f*-64*f*  
internal features of,  
66*f*  
Right ventricular  
hypertrophy, 80  
Rocky-Davis incision, 147  
Root, of lung, 91-92  
Rotational fractures, 438*f*  
Round ligament, 400  
of liver, 233, 234*f*-235*f*,  
242*f*, 244*f*  
of uterus, 203, 206, 332

Roux-en-Y  
gastrojejunostomy,  
199  
Rugae, 181

## S

Sacral artery  
lateral, 302*f*  
median, 290*f*  
Sacral canal, 31  
Sacral curvature, 27, 28*f*  
Sacral fractures, 38  
Sacral ganglia, 301  
Sacral hiatus, 31, 299  
Sacral node, 331*f*  
Sacral plexus, 35*f*, 301,  
315*f*  
Sacral splanchnic nerves,  
288*f*, 315*f*  
Sacral veins, lateral and  
middle, 303  
Sacral vertebrae, 31  
Sacrococcygeal ligaments,  
31  
posterior and anterior,  
299  
Sacroiliac (SI) joints, 300  
Sacroiliac ligaments,  
posterior, 298*f*  
Sacrospinous ligament,  
298*f*  
Sacrotuberous ligament,  
298*f*  
Sacrum, 28*f*, 299  
fracture of, 306*f*  
Saphenous vein bypass  
graft, 82

- Saphenous veins, 435
- Sartorius muscle, 306*f*,  
401*f*
- Sartorius tendon,  
avulsion, 304
- Scalp  
layers, 5  
superficial arteries and  
veins, 6*f*
- Scaphoid, 381, 382*f*-383*f*,  
384  
fractures of, 391*f*, 392
- Scapula, 129, 343  
fractures of, 349-351  
inferior angle of, 27  
subclavian artery and,  
346-348, 347*f*,  
356-359
- Scapular artery, 346, 347*f*,  
348, 356, 358*f*
- Scapular ligament, 361*f*
- Scapular veins, 348
- Scarpa's fascia, 201
- Schatzker classification,  
427
- Sciatic foramen  
greater, 298*f*, 300  
lesser, 298*f*, 300
- Sciatic hernia, 215
- Sciatic nerve, 35*f*, 301,  
407*f*, 408, 422  
ankle and foot branches  
of, 435-436
- Sciatic notch, greater,  
297
- Sclerosing adenosis, 54
- Scotty dog, in vertebral  
fractures, 40*f*
- Secondary burn,  
esophageal, 128
- Secondary curvatures, of  
vertebral column, 27
- Secretin, 156, 268
- Semicircular lines (of  
Douglas), 203
- Seminal colliculus  
(verumontanum),  
312*f*, 314
- Seminal vesicle, 285, 312*f*
- Sensory fibers, 73, 314  
of esophagus, 119  
of lungs, 96
- Sensory innervation, 68  
of breast, 47
- Sentinel node, 49-50
- Septation, 69-71
- Septum primum, 69, 70*f*
- Septum secundum, 70*f*,  
71
- Serosa  
of duodenum, 186  
of stomach, 183
- Serous adenofibroma,  
339*f*
- Serous cystoma, vs.  
ovarian cyst, 336*f*
- Serous mesothelial  
membrane, 65
- Serous pericardium, 65-68
- Serratus anterior muscle,  
129
- Shaft fractures, 411*f*,  
412
- Shear fracture, 438*f*
- Short gastric arteries,  
120*f*, 189*f*, 191

- Short gastric veins, 121*f*, 192*f*
- Short-bowel syndrome, 281
- Shoulder  
 arterial supply of, 346-348, 347*f*, 356-359, 358*f*  
 joints of, 343-345, 344*f*, 355*f*  
 ligaments of, 345-346, 355*f*  
 nerves of, 348-349  
 venous drainage of, 348
- Sigmoid arteries, 166, 167*f*, 290*f*
- Sigmoid colon, 163, 164*f*  
 diverticulosis in, 171, 172*f*  
 innervation of, 165-166  
 small intestine and, 266*f*
- Sigmoid mesocolon, 164*f*, 165
- Sigmoid nodes, 170*f*
- Sigmoid veins, 168, 169*f*
- Simple mastectomy, 59
- Simple serous cyst, *vs.* ovarian cyst, 336*f*
- Sinuatric node, 62
- Sinus venosus  
 development, 72
- Skin dimpling, 55-56, 56*f*
- Skin edema, in breast cancer, 58*f*
- Skull  
 anatomy of, 3-5, 4*f*  
 base of, 3  
 neurovascular supply of, 5-10  
 venous drainage of, 7-9
- Skull fractures, 10-13, 11*f*-12*f*
- Sliding hernia, 197*f*
- Small bowel,  
 adenocarcinoma of, 196-199
- Small cardiac vein, 75*f*, 76
- Small cell anaplastic carcinoma, of lungs, 111
- Small intestine  
 anatomy of, 265-270  
 arterial supply of, 270  
 arteries of, 271*f*  
 cancer of, 278-279  
 clinical correlates of, 273-281  
 Crohn's disease of, 279-281, 280*f*  
 diseases, 265-281  
 diverticular disease of, 276  
 endocrine gut functions of, 268  
 innervation of, 268-270  
 intussusception of, 273-276  
 lymph vessels of, 274*f*  
 lymphatic drainage of, 273

- Small intestine  
(*continued*)  
Meckel's ileal  
diverticulum,  
276-278  
microscopic anatomy  
of, 266-268  
nerves of, 269*f*  
nodes of, 274*f*  
obstruction, 273  
short-bowel syndrome  
and, 281, 282*f*  
veins of, 272*f*  
venous drainage of, 273  
vessels and lymphatics  
and, 270-273
- Smoking, cardiovascular  
disease in women  
and, 83*f*
- SMS. *see* Somatostatin  
(SMS)
- Snuffbox, anatomical, 389  
scaphoid fracture and,  
391*f*, 392
- Solitary lymphoid nodule,  
267*f*
- Somatostatin (SMS), 268
- Somatostatinoma, 263
- Spaces of Disse, 240*f*,  
245*f*
- Spaces of Mall, 245*f*
- Spermatic cord, 202*f*, 203,  
206, 210*f*  
layers and contents of,  
207  
nerves near, 207
- Spermatic fascia, 202*f*,  
203, 207, 209*f*
- Sphenoid bone, 3, 4*f*
- Sphincter, bile duct, 153
- Sphincter of Oddi, 153,  
158, 255
- Sphincter urethrae  
muscle, 312*f*
- Spigelian hernia, 214*f*,  
215
- Spinal cord  
arteries of, 34-36  
nerves and, 33-34, 35*f*
- Spinal foramina, 31
- Spinal nerve, 10  
cervical, dorsal rami of,  
8*f*  
intercostal nerve and,  
131*f*, 132
- Spine, 28*f*  
arteries of, 34-36  
articulated, 27  
joints of, 31-33  
ligaments of, 31-33
- Spinous process, 30*f*
- Splanchnic nerve, greater  
thoracic, 188*f*
- Spleen, 254*f*, 257*f*  
carcinoma of tail  
adherent to, 262*f*  
veins of, 258*f*
- Splenic artery, 120*f*, 189*f*,  
191, 254*f*, 256, 257*f*
- Splenic nodes, 194*f*, 260*f*
- Splenic vein, 121*f*, 122,  
169*f*, 192*f*, 193, 243,  
244*f*, 258*f*, 260*f*
- Splenorenal ligament,  
218*f*
- Spondylolisthesis, 40*f*

- Spondylolysis, 40*f*
- Sprains, of knee  
ligaments, 426*f*
- Stellate ganglion, 118*f*
- Sternal angle of Louis,  
132
- Sternal facet, of clavicle,  
343, 345*f*
- Sternoclavicular joint,  
343-346
- Sterncostal joints, 130
- Sternum, 130-132, 130*f*  
fractures of, 133, 134*f*
- Stomach  
arteries of, 189*f*, 191  
cancer of, 196-199, 198*f*  
cardiac nodes of, 123*f*  
functional anatomy and  
motility of, 181-183  
gastritis of, 193  
hiatal hernia of, 196,  
197*f*  
innervation of, 187-189,  
188*f*  
lymphatic drainage of,  
193, 194*f*  
microscopic anatomy  
of, 183  
parts of, 181, 182*f*  
ulcer of, 193-196, 195*f*  
veins of, 258*f*  
venous drainage of,  
191-193, 192*f*
- Straight arteries (arteriae  
rectae), 167*f*, 267*f*,  
271*f*
- Straight veins (venae  
rectae), 272*f*
- Strap muscles, 17
- Stroke, 83*f*
- Struvite stones, 226
- Styloid process, 367, 368*f*,  
383*f*
- Subacromial bursae, 353,  
355*f*
- Subclavian artery, 18*f*,  
120*f*, 133, 346-348,  
347*f*, 356-359
- Subclavian groove, 345*f*
- Subclavian vein, 18*f*, 119,  
121*f*, 133, 348, 359
- Subclavius muscle, 129,  
345*f*
- Subcostal arteries,  
132
- Subdeltoid bursae, 353,  
355*f*
- Submucosa  
of colon, 164  
of duodenum, 185-186  
of stomach, 183
- Submucosal bronchiolar  
smooth muscle, 95
- Submucous, 335*f*  
pedunculated, 335*f*
- Subpyloric nodes, 194*f*
- Subscapular artery, 347*f*,  
348, 358*f*, 359
- Subscapular fossa, 343,  
344*f*
- Subscapular nerve, 361*f*
- Subscapular veins, 348
- Subscapularis muscle,  
355*f*, 363*f*
- Subscapularis tendon,  
353, 355*f*

- Subserous, 335*f*  
  displacing tube, 335*f*  
  pedunculated, 335*f*
- Subtrochanteric fractures, 410
- Superficial epigastric artery, 403
- Superficial external pudendal artery, 403
- Superficial fibular (peroneal nerve), 422
- Superficial inguinal nodes, 293*f*, 331*f*, 423*f*
- Superficial posterior compartment, of leg, 417*f*, 418
- Superficial temporal artery, 5, 6*f*
- Superficial venous thrombophlebitis, 54
- Superior lateral brachial cutaneous nerve, 361*f*
- Superior mesenteric artery  
  branches, small  
    intestine and, 270  
  colon and, 165-168  
  duodenum and, 185, 187, 190*f*, 191  
  ileocolic artery and, 140*f*, 142-143  
  kidneys and, 218*f*  
  left renal vein and, 222, 224*f*  
  pancreas and, 253, 254*f*, 257*f*  
  right hepatic artery and, 243
- Superior mesenteric artery (*continued*)  
  small intestine and, 271*f*-272*f*
- Superior mesenteric ganglion, 187, 221*f*, 269*f*
- Superior mesenteric lymph nodes, 144, 144*f*, 168, 170*f*
- Superior mesenteric nodes, 274*f*
- Superior mesenteric plexus, 166, 222, 268, 269*f*
- Superior mesenteric vein  
  colon and, 169*f*  
  duodenal drainage of, 191-193, 192*f*  
  ileocolic vein and, 143, 143*f*  
  pancreas and, 254*f*, 258*f*  
  portal vein and, 243, 244*f*  
  small intestine and, 271*f*-272*f*, 273
- Superior mesenteric vessels, duodenum and, 184*f*
- Superior rectal artery, 288*f*, 290*f*
- Superior rectal nodes, 293*f*
- Superior rectal plexus, 288*f*
- Superior rectal vein (bifurcation), 291*f*



- Superior vena cava, 61-62, 63*f*-64*f*
- Superior vena cava (SVC) syndrome, 113
- Superior vesical arteries, 329*f*
- Supinator muscle, 371*f*, 378*f*
- Supracondylar fracture, 365-366
- Supracondylar ridge, 354*f*
- Supraduodenal artery, 155*f*, 190*f*
- Supraorbital artery, 6*f*
- Supraorbital nerve, 8*f*
- Suprapyloric nodes, 194*f*
- Suprascapular artery, 346, 347*f*, 348, 356
- Suprascapular nerve, 349
- Suprascapular notch, 343, 344*f*, 346, 356
- Supraspinatus muscle, 349, 361*f*, 363*f*
- Supraspinatus tendon, 353, 355*f*
- Supraspinous ligament, 32
- Suprasternal (jugular) notch, 130, 130*f*
- Supratrochlear artery, 6*f*
- Supratrochlear nerve, 8*f*
- Surgical (false) capsule, 17
- Suspensory ligament of ovary, 326*f*
- Sustentaculum tali, 429, 430*f*
- fracture of, 440
- Sutures, 3
- Sympathetic ganglia, 288*f*, 315*f*
- Sympathetic postganglionic fibers, 73, 314
- of esophagus, 119
- of lungs, 96
- Sympathetic trunk, 131*f*, 288*f*, 315*f*
- Syncope, 84
- Synovial membrane, 400
- ### T
- Taeniae coli, 163, 164*f*, 165
- appendix and, 139, 165
- diverticula and, 171, 172*f*
- rectum and, 285
- Tail of pancreas, 254*f*
- Talar fractures, 439*f*, 440
- Talus, 429-431, 430*f*
- fractures of, 436-440
- Tamponade, cardiac, 87, 90*f*
- Tarsal bones, 429-431
- Tarsal fractures, 436
- Tectorial membrane, 32
- Temporal bone, 3, 4*f*
- Tension pneumothorax, 105*f*
- Teres minor muscle, 361*f*
- Teres minor tendon, 353, 355*f*
- Tertiary burn, esophageal, 128
- Testicular artery, 207

- Testicular veins, 207  
Testis, 207  
Tetralogy of Fallot, 80  
Theca cells, 333*f*-334*f*  
Theca lutein cells, 328  
Thenar eminence, 390,  
391*f*, 392  
Thenar space, 386*f*, 387  
Thigh  
  anatomy of, 397-403  
  arterial supply to,  
    403-406, 404*f*  
  compartments of,  
    400-403, 401*f*  
  fractures of, 397-412  
  nerves of, 408  
  veins of, 406  
Thoracic aorta, 131*f*,  
132  
Thoracic cage, 134*f*  
Thoracic curvature, 27,  
28*f*  
Thoracic duct, 123*f*, 259,  
274*f*  
Thoracic vertebrae, 28*f*,  
29  
Thoracoacromial artery,  
348, 358*f*  
Thoracodorsal nerve,  
361*f*  
Thoracolumbar fractures,  
38  
Thorax, fractures of,  
129-135  
Three-column concept,  
  for vertebral  
  fractures, 36  
Three-vessel disease, 84  
Thumb, 381  
  injury to, 393*f*  
  proper digital artery of,  
    388*f*, 389  
Thyrocervical trunk, 18*f*  
Thyroid, 17-19, 18*f*, 20*f*  
  arterial supply of, 19  
  cancer of, 21-23  
  types of, 21-23  
  diseases of, 17-23  
  Graves' disease and, 22*f*  
  lymphatic drainage of,  
    21  
  venous drainage of,  
    19-20  
Thyroid artery  
  inferior, 18*f*, 19, 20*f*,  
    120*f*  
  superior, 18*f*, 19, 20*f*  
Thyroid cartilage, 27  
Thyroid follicular  
  (epithelial/principal)  
  cells, 17  
Thyroid ima artery, 19  
Thyroid plexus, 19-20  
Thyroid vein  
  inferior, 20, 20*f*, 121*f*  
  middle, 20  
  superior, 20, 20*f*  
Thyroidectomy, 21,  
24*f*  
Tibia, 413, 414*f*  
  fractures of, 424*f*  
Tibial artery, 419*f*, 420  
  anterior, 435  
  posterior, 435  
Tibial (medial) collateral  
  ligament, 415*f*, 416

- Tibial (anterior) divisions,  
of sciatic nerve,  
435-436
- Tibial fractures, 424*f*
- Tibial nerve, 407*f*,  
419*f*
- Tibial plateau fractures,  
424*f*, 427
- Tibial shaft fractures,  
424*f*, 427-428
- Tibial veins, 435
- Tibialis posterior, 418,  
419*f*
- Tissue chips, 321*f*
- Trachea, 92-94
- Tracheal (respiratory)  
mucosa, 94
- Trachealis smooth muscle,  
94
- Tracheobronchial mucosa,  
94
- Tracheobronchial nodes,  
123*f*
- Tracheobronchial tree,  
innervation of, 97*f*
- Traction diverticulum,  
124
- Transcondylar fracture,  
366
- Transurethral  
prostatectomy  
(TURP), 319, 321*f*  
aspects of, 320
- Transversalis fascia, 201,  
202*f*, 205-206, 211
- Transverse acetabular  
ligament, 400
- Transverse colon, 266*f*
- Transverse facial artery, 5,  
6*f*
- Transverse folds of  
rectum, 286*f*
- Transverse meniscal  
ligament, 416
- Transverse metatarsal  
joint (Lisfranc), 432
- Transverse pericardial  
sinus, 68
- Transverse process, 30*f*,  
130
- Transverse rib fracture,  
134*f*
- Transverse tarsal joint  
(Chopart), 432
- Transversus abdominis,  
202*f*, 204
- Transversus perinei  
muscle and fascia,  
313
- Trapezium, 381, 382*f*,  
384, 385*f*
- Trapezius muscle,  
129
- Trapezoid bone, 381,  
382*f*, 385*f*
- Trapezoid ligament, 344*f*,  
346
- Trapezoid line, of clavicle,  
343, 345*f*
- Trauma, in uterus,  
333*f*-334*f*
- Triangle of Calot, 151,  
155*f*  
incision of, 162
- Triangle of Doom, 210*f*
- Triangle of Pain, 210*f*

- Triangular ligaments, 233, 235*f*  
 Triceps brachii muscle, 356, 357*f*  
 Triceps tendon, 345  
 Tricuspid valve, 62, 66*f*  
 Trigeminal (V) nerve, 9  
   mandibular division of, 8*f*, 9  
   maxillary division of, 8*f*, 9  
   ophthalmic division of, 8*f*, 9  
 Triquetrum, 381, 382*f*-383*f*, 384  
 Trituration, 181  
 Trochlea, 354*f*  
 Trochlear (IV) nerve, 9  
 Trochlear notch, 368*f*  
 True ribs, 130*f*  
 Truncus, 69  
 Truncus arteriosus, 71  
   persistent, 80  
 Tubal inflammation, 333*f*-334*f*  
 Tuberculosis, in uterus, 333*f*-334*f*  
 Tumor/node/metastasis (TNM) system, for breast cancer, 59  
 Tumors, lung, 109-114  
   benign, 114  
 Tunica adventitia, 117  
 Tunica albuginea  
   ovarian, 328  
   testicular, 207  
 Tunica muscularis, 117  
 Tunica vaginalis, 206-207, 209*f*  
 TURP. *see* Transurethral prostatectomy (TURP)  
 Typical cervical vertebrae, 29
- ## U
- Ulcer  
   duodenal, 196  
   gastric, 195*f*  
   peptic, 193-196, 195*f*  
 Ulcerative colitis, 177*f*, 178  
 Ulna, 353, 367, 368*f*, 370*f*  
   fractures of, 374, 375*f*-376*f*, 379, 390-392  
 Ulnar artery, 358*f*, 359  
   in forearm, 369, 370*f*-371*f*, 372  
   in wrist and hand, 385*f*, 387, 388*f*  
 Ulnar bursa, 386*f*, 387  
 Ulnar nerve, 357*f*, 360*f*  
   in forearm, 369, 370*f*-371*f*, 373-374  
   in wrist and hand, 385*f*, 388*f*, 390  
 Ulnar veins, 373  
 Ultrasound, 160  
 Umbilical hernia, 212-213, 214*f*  
 Umbilical sinus, 277*f*  
 Umbilical vein, 233, 235*f*

- Umbilicointestinal fistula, 277*f*
- Umbilicus, 244*f*, 277*f*
- “Unhappy triad” of O’Donoghue, 426*f*
- Ureter, 219*f*, 220  
 blood supply of, 220, 223*f*-224*f*  
 innervation of, 220-222, 221*f*
- Ureteral obstruction, 227*f*
- Ureters, 326*f*, 329*f*  
 uterine arteries and, 330
- Urethra  
 female, 328, 337*f*  
 prostate and, 311, 314
- Urethral sphincter, internal, 312*f*
- Urethral stricture, postoperative, 321*f*
- Uric acid stones, 226
- Urinary bladder, 322*f*
- Urogenital diaphragm, male, 313
- Uterine  
 fibroids in, 335*f*  
 lymphatic drainage of, 332
- Uterine artery, 328, 329*f*
- Uterine bleeding, dysfunctional, 333*f*-334*f*
- Uterine endometrial carcinoma, 338
- Uterine fibromas, 332
- Uterine (fallopian) tubes (ducts), 326*f*, 327, 337*f*  
 endometriosis in, 337*f*
- Uterine veins, 330
- Uterosacral ligament, 326*f*
- Uterus, 325, 326*f*  
 and adnexal diseases, 325-340  
 anatomy of, 325-328  
 arterial supply of, 328-330  
 body of, 326*f*  
 fundus of, 326*f*  
 position of, 326-327  
 venous drainage of, 330

## V

- Vagal afferents, 166
- Vagal trunk, 188*f*
- Vagina, 328, 337*f*  
 anatomy of, 325-328
- Vaginal artery, 329*f*
- Vaginal veins, 330
- Vagus nerve (X), 10, 18*f*, 63*f*, 73, 165  
 auricular branch of, 8*f*
- Valgus stress, 426*f*
- Valves of Houston, 286*f*
- Valves of Kerckring, 267*f*
- Valvulae conniventes, 186, 268
- Valvular abnormalities, 79
- Valvular aortic stenosis, 81
- Valvular disease, 84-86, 85*f*

- Varices, esophageal, 122, 250*f*
- Vas deferens, 202*f*, 207-208, 209*f*
- Vascular signs, of breast cancer, 58*f*
- Vasoactive intestinal peptide (VIP), 256
- Vastus lateralis, 401*f*, 402
- Vastus medialis, 401*f*, 402
- Venae rectae (straight veins), 272*f*
- Venous drainage  
of prostate, 317  
of ribs and thorax, 133  
of skull, 7-9  
of thyroid, 19-20  
of vertebral column, 36
- Ventricle  
internal features of  
left, 67*f*  
right, 66*f*  
left, 61-62, 63*f*  
right, 61-62, 63*f*-64*f*
- Ventricular septal defects (VSDs), 78, 80  
in myocardial infarction, 82
- Vermiform appendix, 140*f*-141*f*
- Vertebra prominens, 27
- Vertebrae  
articulated, 27  
typical, 27
- Vertebral arch joints, 32
- Vertebral artery, 7
- Vertebral body, 30*f*
- Vertebral canal, 30*f*
- Vertebral column. *see also*  
Spinal cord; Spine  
anatomy of, 27-33, 28*f*  
venous drainage of, 36
- Vertebral dislocation, 37*f*
- Vertebral foramen, 30*f*
- Vertebral fractures, 27-38  
three-column concept  
for, 36
- Vertebral notch, 30*f*
- Vertebral venous plexuses, 317
- Vesical artery, inferior, 289
- Vesicouterine pouch, 327
- Vessels  
esophageal, 119-122  
of lungs, 96-102, 99*f*
- Vestibule, 328
- Vestibuloacoustic nerve.  
*see*  
Acousticovestibular (VIII) nerve
- VIP. *see* Vasoactive intestinal peptide (VIP)
- VIP (vasoactive intestinal peptide), 256
- VIPoma, 263
- Virchow's node, 123*f*
- Viscera, abdominal, 266*f*
- Visceral (serous)  
pericardium, 65
- Visceral pleura, of lungs, 91-92
- Viscerocranium, 3
- Volvulus, 163, 281  
and large bowel obstruction, 178

Vomer, 3  
VSDs. *see* Ventricular  
septal defects (VSDs)

## W

Werner-Morrison  
syndrome, 263  
Whipple's triad, 263  
Wilms' tumor  
(nephroblastoma),  
229  
Wrist  
anatomy of, 381-387,  
382*f*-383*f*  
arterial supply of,  
387-389, 388*f*  
compartment syndrome  
of, 390-392  
compartments of,  
384-387, 385*f*  
fractures of, 381-392  
joints of, 381-384  
ligaments of, 384  
nerves of, 389-390  
venous drainage of, 389

## X

Xiphisternal joint,  
132  
Xiphoid process, 130*f*,  
132  
and linea alba, 205  
X-ray mammography,  
50

## Z

Zenker's diverticulum,  
122-124  
Zollinger-Ellison  
syndrome, 200, 263,  
264*f*  
Zona orbicularis,  
398*f*  
Zygomatic bone, 3,  
4*f*  
Zygomatic fractures, 14*f*,  
15  
Zygomaticofacial nerve,  
8*f*  
Zygomaticotemporal  
nerve, 8*f*

This page intentionally left blank